

MS 1 Cardiology Exam

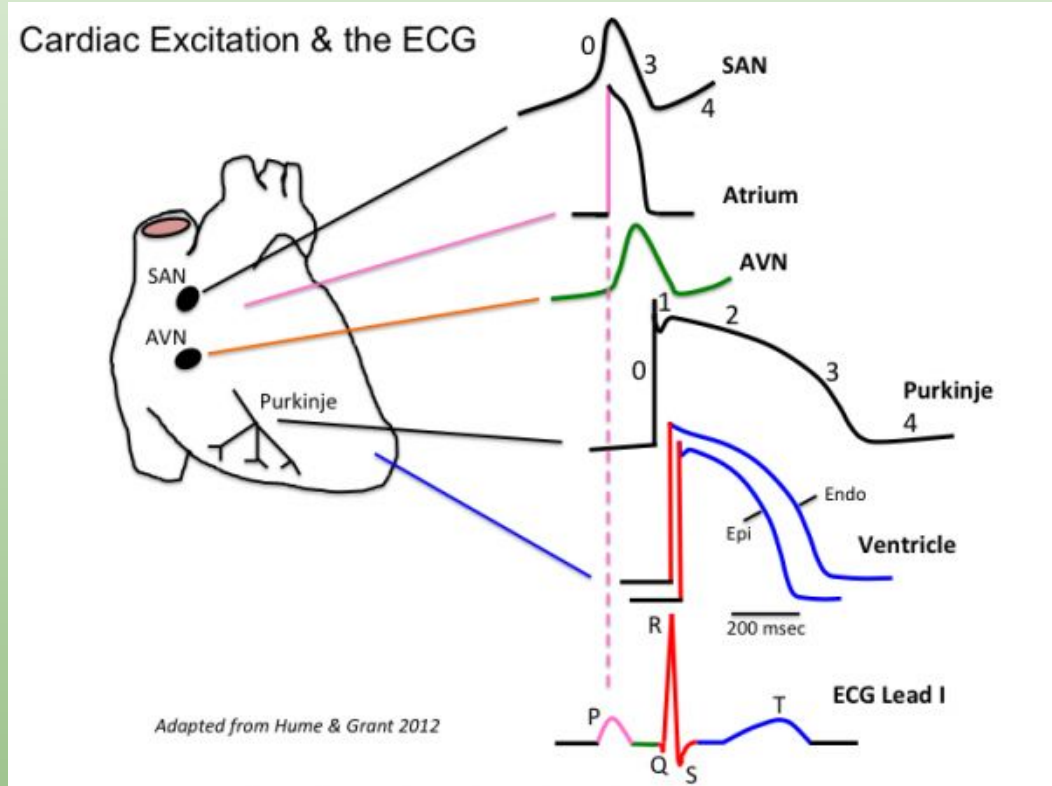
Amanda Krauss

Disclaimer

- I put this lecture together from notes I took 3 years ago. I supplemented that information with resources that you will likely use next year.
- Items in blue are attempts to plant a seed for next year or paint a bigger picture of pathophysiology. It will be lower yield for your upcoming exam.

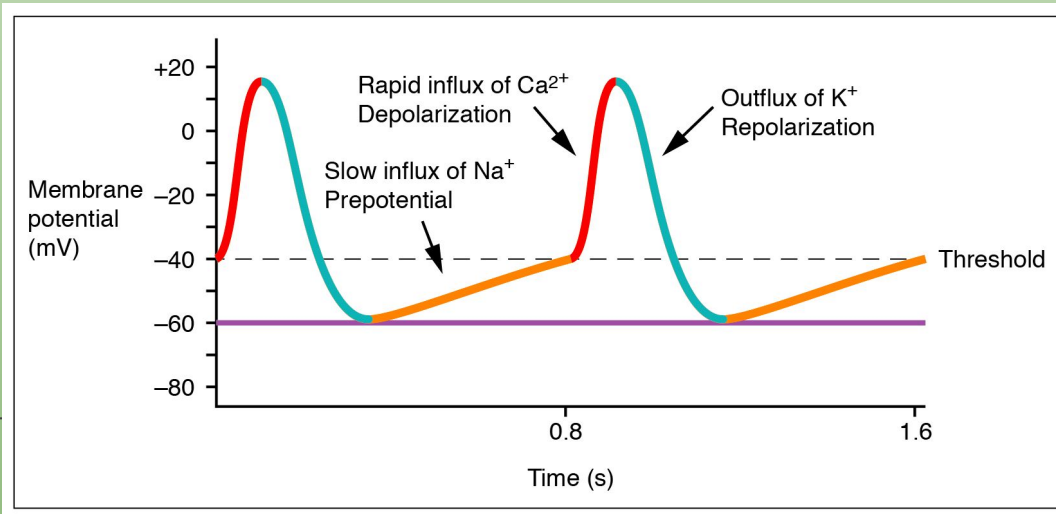
Cardiac Physiology-Electrical Conduction

- Normal conduction system goes SA to AV to Bundle of His to Bundle Branches (Right, Left Anterior and Left Posterior), Purkinje fibers
- Two different electrically conducting cells
 - SA node and AV node
 - Funny current adds to rhythmicity of these pacemakers
 - Purkinje and Bundles
 - Lacks funny current
- The small differences in ion conduction play into autonomics and medications



Cardiac Physiology-Electrical Conduction

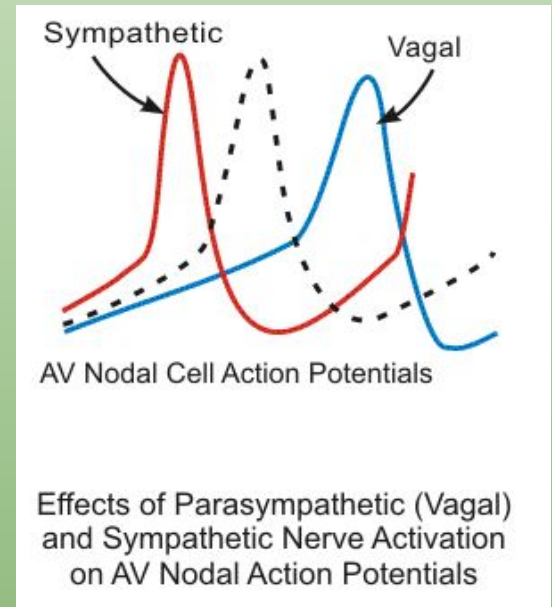
- Pacemaker (SA and AV)
 - SA goes faster, delay in AV allows for the ventricles to fill with blood for an effective SV
 - SA fires, depolarizes atria (P wave)
 - Delay in AV before AV fires, depolarizes ventricles (QRS)
 - Delay in AV represented by PR interval



4-Na funny current
0-Ca influx
3-K efflux

Cardiac Physiology-Electrical Conduction

- Sympathetics-Increased conduction of Ca (increase HR)
 - Beta 1 activation leads to increased Ca, steeper 4
- Parasympathetics-Increased conduction of K (decrease HR)
 - M2 activation leads to increased K, further from threshold

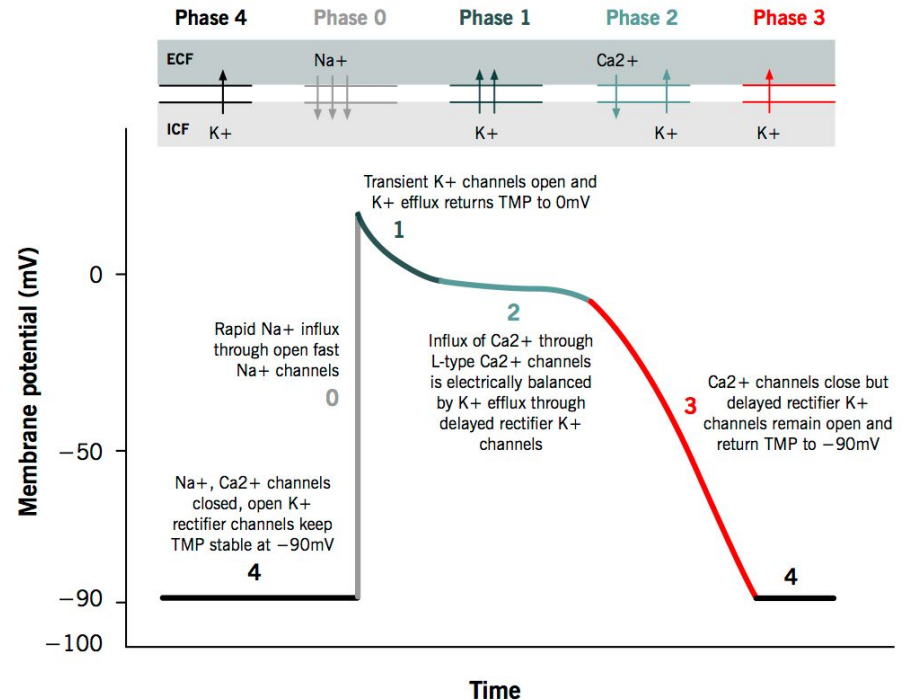


Cardiac Physiology-Electrical Conduction

- Conduction at non-nodal sites
 - Bundles, Purkinje, etc.

Action potential of cardiac muscles

Grigoriy Ikonnikov and Eric Wong



Genetics

- Channelopathies
- Long QT
 - LQT1-slow K channel causes arrhythmia with exercise
 - LQT2-fast K causes arrhythmia with loud noises
 - LQT3-Na channel causes arrhythmia in NREM
- Short QT
 - Can lead to atrial fibrillation
- Connexin 40-can lead to atrial fibrillation

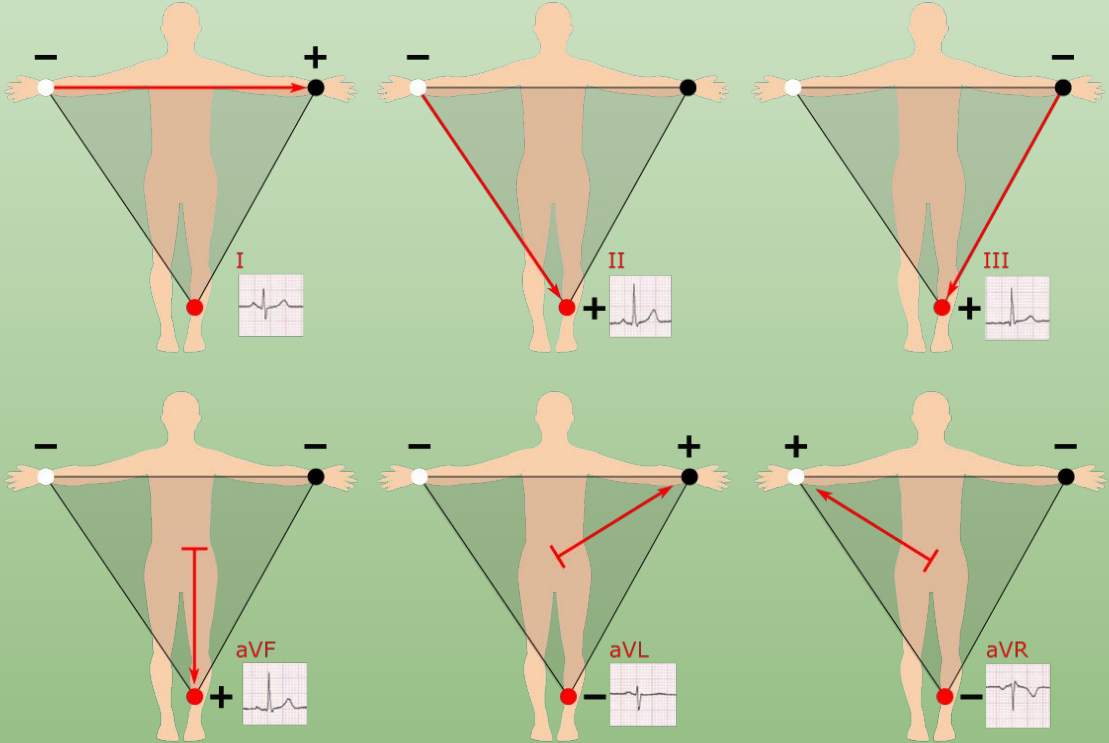
EKG

- Try to understand rather than just memorize and recognize a pattern
- Dr. Petrany does a great job teaching a systematic way of going through EKGs-rate, rhythm, axis, PR, QRS, ST, QT
 - Regardless of which field you go into-you WILL order an EKG on your patient at some point-so know how to read them

Basics of EKG

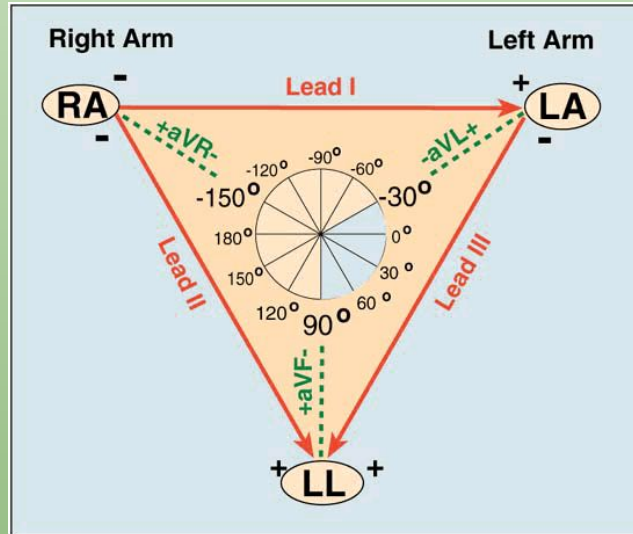
- Different electrical leads are placed on the patient to measure that current. Three limbs are used (R arm, L arm, foot) and are designated in leads aVR, aVL, and aVF respectively.
- Three other leads form an equilateral triangle utilizing the previously placed limb leads. This helps form the basis of a 12 lead EKG (this is done by augmenting the positive or negative charge of the respective limb leads but the details are not as important, as long as you understand this axis that forms from these leads)

Basics of EKG



Basics of EKG

- If you were to place those six previously mentioned leads (aVF, aVR, aVL, I, II, and III) then you can form a circle that represents the direction of currents. It looks a little something like this:

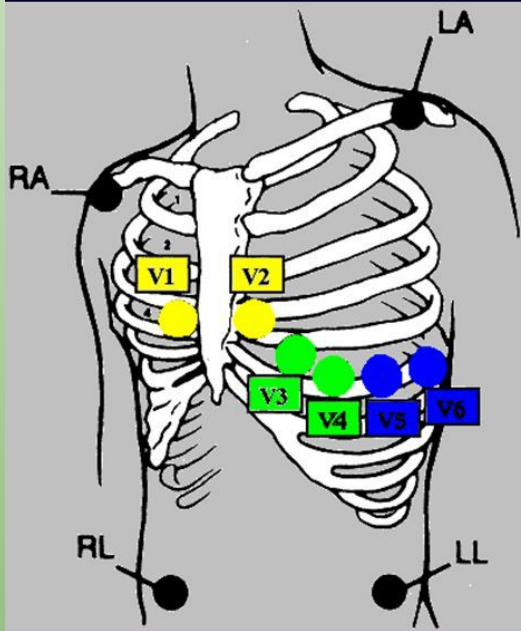


Basics of EKG

- Septal leads, designated as V1 through V6
- These leads start out measuring the conduction of the right side (V1 is furthest right) and go to the left side (V6 is furthest left)
- These leads give a better idea of conduction and provide a left vs right view of conduction. (Particularly in pediatric patients, looking at V1-V3 can be helpful in looking for RVH and V4-V6 for LVH as they will show huge depolarizations in those respective lead groups)

Basics of EKG

Lead Placement – V-Leads



V1-V2 = Septal

V3-V4 = Anterior

V5-V6 = Lateral

V1-V3 = Posterior

V1 – 4th ICS, right of sternum

V2 – 4th ICS, left of sternum

V3 – Midpoint between V2 and V4

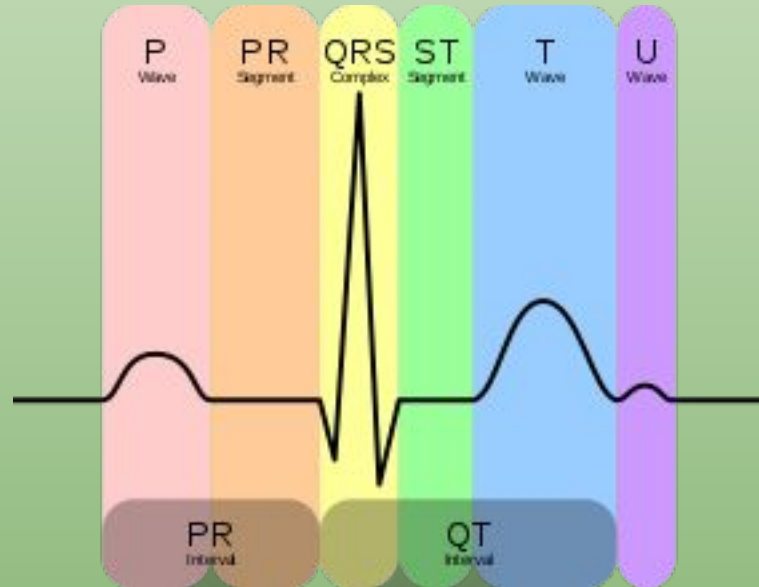V4 – 5th ICS, mid-clavicular line

V5 – Level with V4 , anterior to axillary line

V6 – Level with V4, mid-axillary line

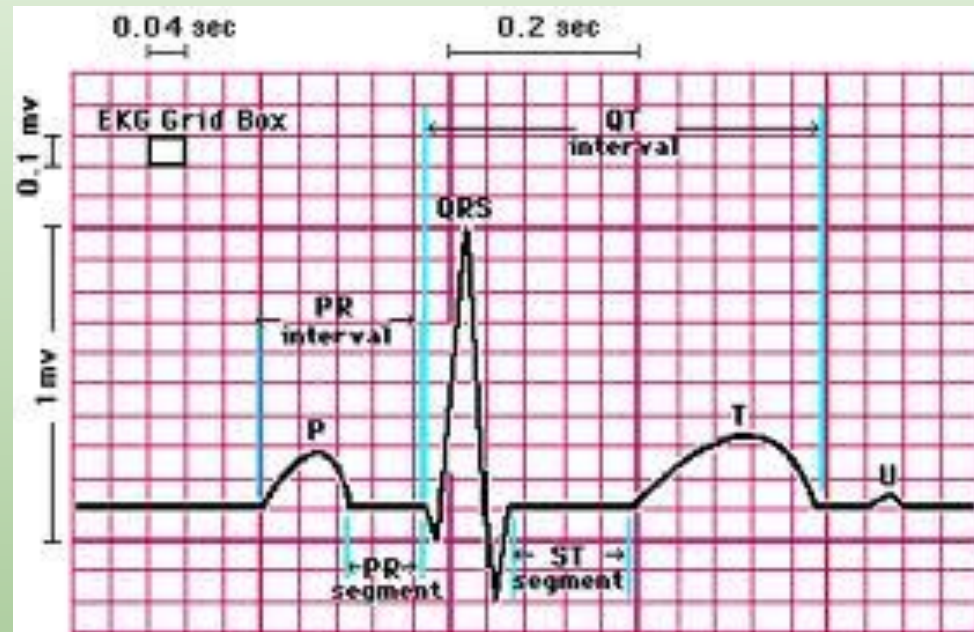
Basics of EKG

- This is what a normal EKG tracing looks like.
- P-atrial depolarization
- QRS-ventricular depolarization (atrial repolarization is buried within it)
- T-ventricular repolarization



Basics of EKG

- PR-0.12 to 0.2s
- QRS-<0.12s
- QTc-QT/RR
 - (<0.470ms M, 0.48ms F)
- Alterations in the QT-arrhythmias
 - Medications are the usual culprit
 - Genetics and channelopathies



Vertical 1mm=0.1mV

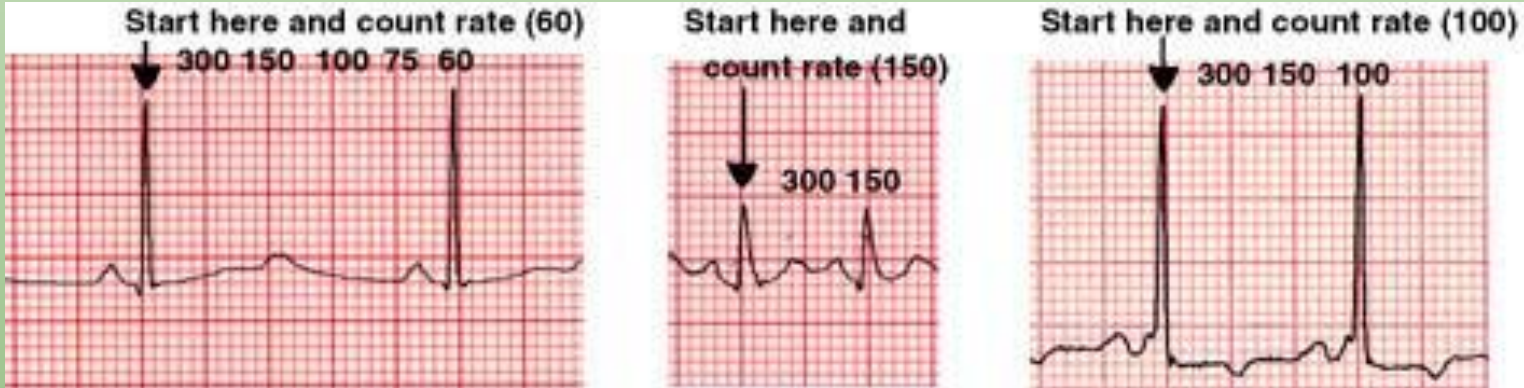
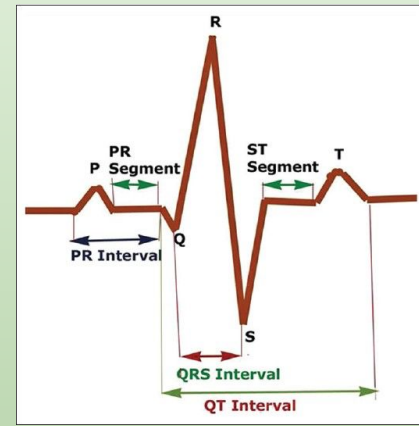
Horizontal small=0.04s, big=0.20s

Basics of EKG

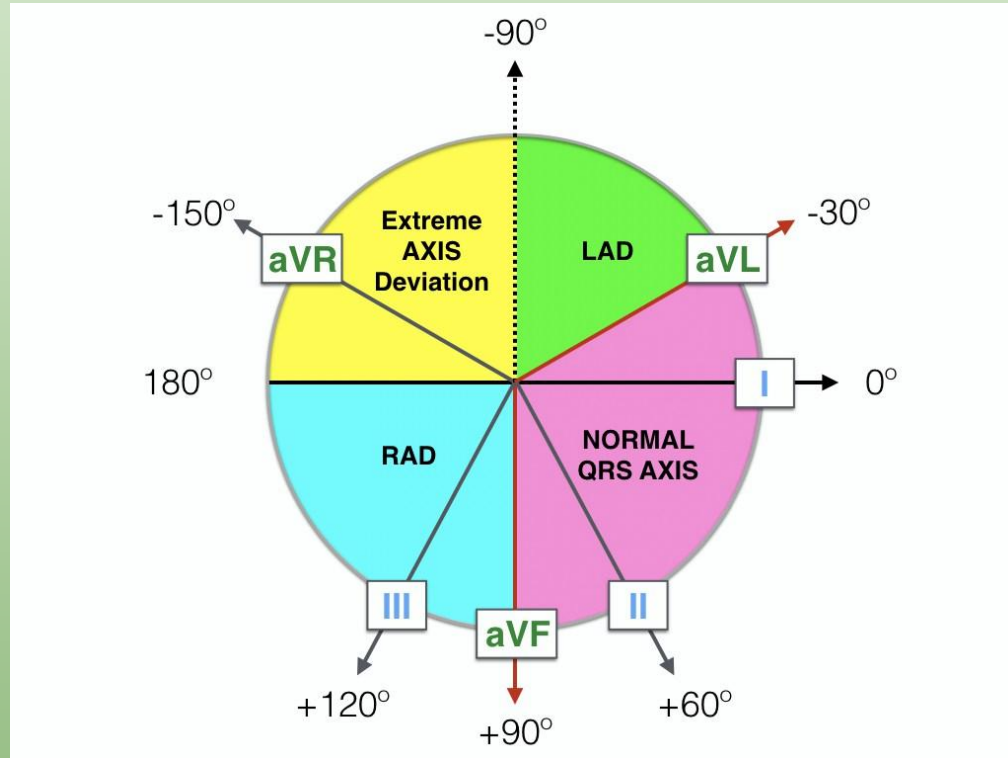
- Remember-EKGs are measuring vectors based on particular lead placement
 - Heart should depolarize from R to L and top to bottom
 - Net current towards something gives an upward deflection, away gives a downward deflection
 - The magnitude of these deflections reflects tissue mass or conduction delays

EKG Basics

- Rate 60-100, count off method (300, 150, 100, 75, 60)
 - 300/number of big boxes
 - If they give you a 12 lead with a rhythm strip-x6

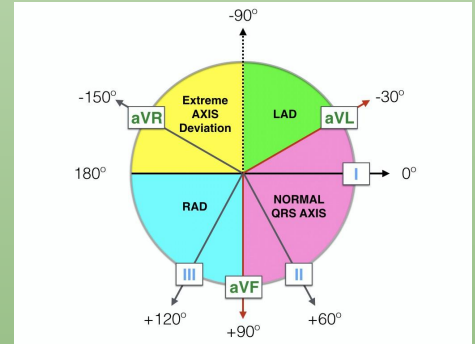


EKG Basics-Axis



Back to Basics

- Axis-normal from -30 to 90
 - Remember that positive currents mean that the net depolarization is going towards that lead
 - Lead I lines up with 0 and aVF lines up with 90
 - If they are both positive you are between 0 and 90
 - If aVF is positive and I is negative you have RAD
 - If I is positive and aVF is negative, you are between 0 and -90
 - To determine if LAD or normal, look at II
 - If II is positive-NAD
 - If II is negative-LAD











Axis

- Normal axis is -30 to 90
- Axis gives representation of tissue mass and/or electrical conduction
- Causes of LAD
 - Inferior wall MI
 - LAHB
 - LVH
 - Endocardial cushion defects
- Causes of RAD
 - RVH
 - LPHB
 - Massive PE

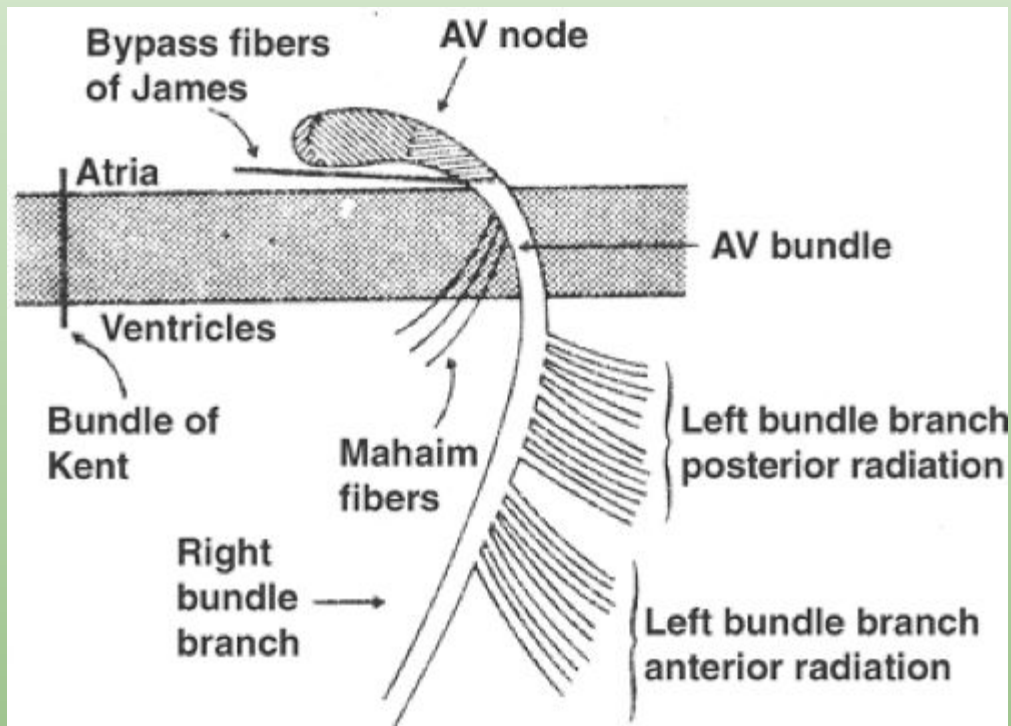
P wave

- P wave represents atrial depolarization
- Should be symmetric
- RAE leads to prominent P wave
- LAE leads to prominent m shape of p
 - Anatomically LA is close to the esophagus
 - LAE can lead to dysphagia

	II	V1
Normal		
RAE		
LAE		
RAE + LAE		

PR Interval

- Atrial depolarization to ventricular depolarization
 - Tells you if the conduction from SA to AV node is working
 - Should be one big box
- Shortened ($<.2$) in WPW because the Bundle of Kent depolarizes before the conduction from SA to AV occurs (AV is supposed to slow things down)
- Prolonged ($>.2$) in AV Blocks

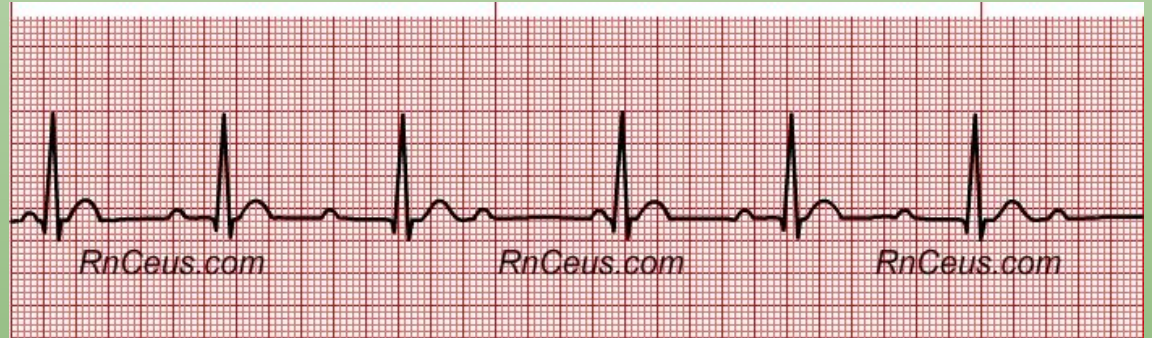
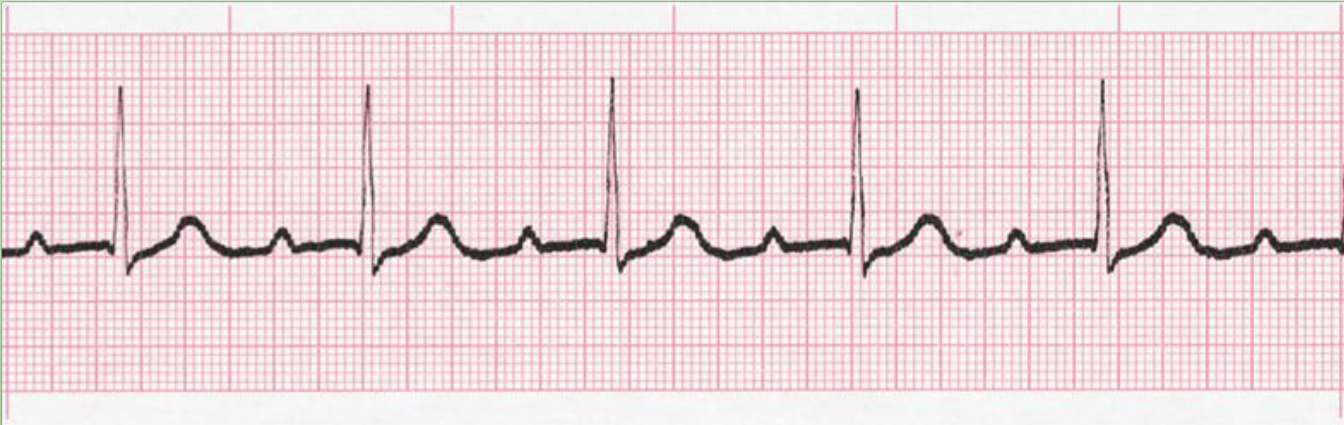

Importance of the PR interval

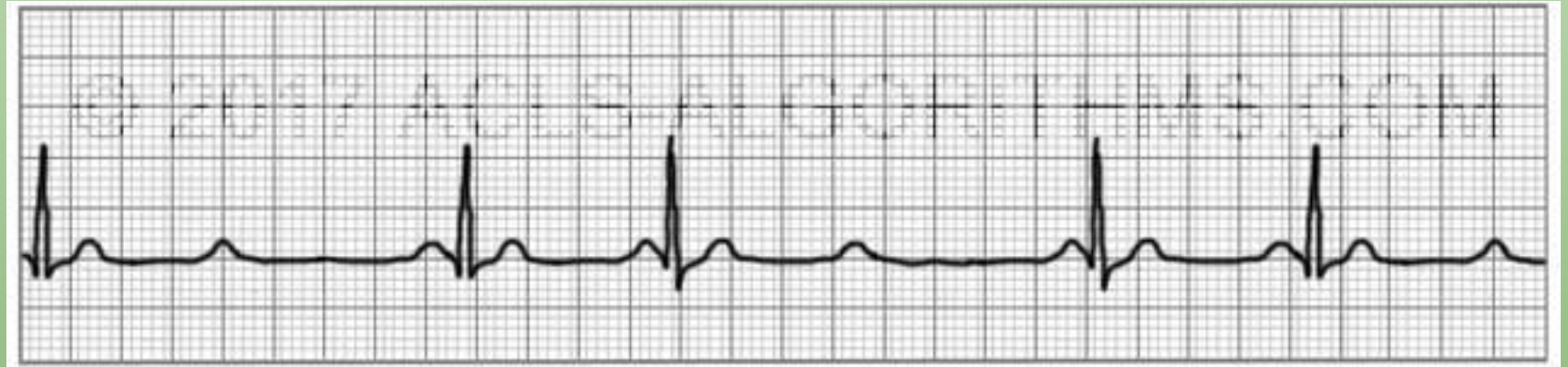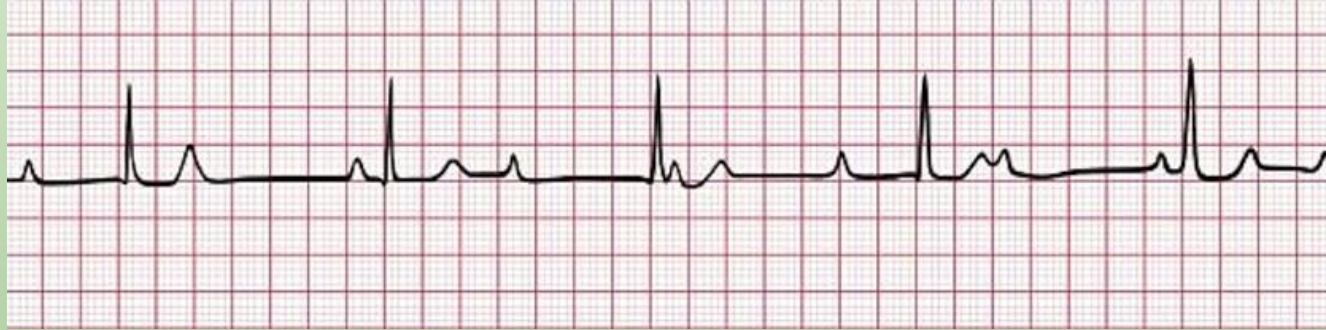
- Heart Block

- 1st Degree is no big deal, just a long PR interval
- 2nd Degree type 1-PR lengthens then drops
- 2nd Degree type 2-drops a beat without lengthening
- 3rd Degree-no association with P and QRS

AV Blocks



AV Blocks

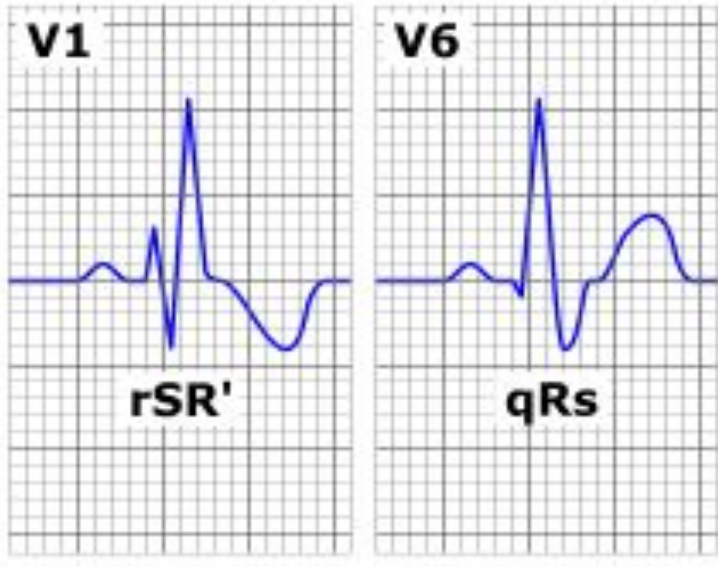


QRS

- Back to the rule that normal conduction is the fastest-if the QRS is prolonged that means that the normal conduction pathway is not working
- Recall that the heart depolarizes SA->AV->Bundle of His (RBB and LBB, LBB further splits into anterior and posterior fascicles->Purkinje)
- If the heart is using the normal conduction pathway, the QRS (ventricular depolarization) should be less than .12s
- If the heart cannot use that conduction pathway because there is a block or current is going the wrong direction, it will take >.12s
 - The differential of things that can cause a prolonged QRS are RBBB, LBBB, pacemaker, and WPW

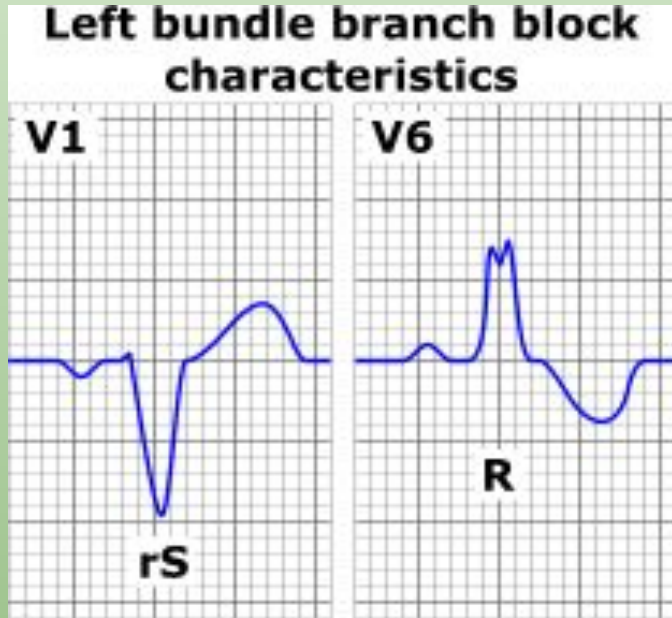
Bundle Branch Blocks-Right

Right bundle branch block characteristics



- V1 tells you about the right side of the heart. If the QRS is wide, conduction is not happening in the most efficient way. The characteristic pattern in V1 is rSR' (look for the M pattern)
- The positive upward deflection represents an attempt to conduct, then blocked, and then comes back after depolarizing the left side of the heart first (the net negative).
- It is able to bypass the block after depolarizing the left side of the heart
- The rSR' pattern is normal in children if the QRS is still narrow. Always check the QRS interval before saying hey there is a bundle branch off the wave morphology alone.

Bundle Branch Block-Left

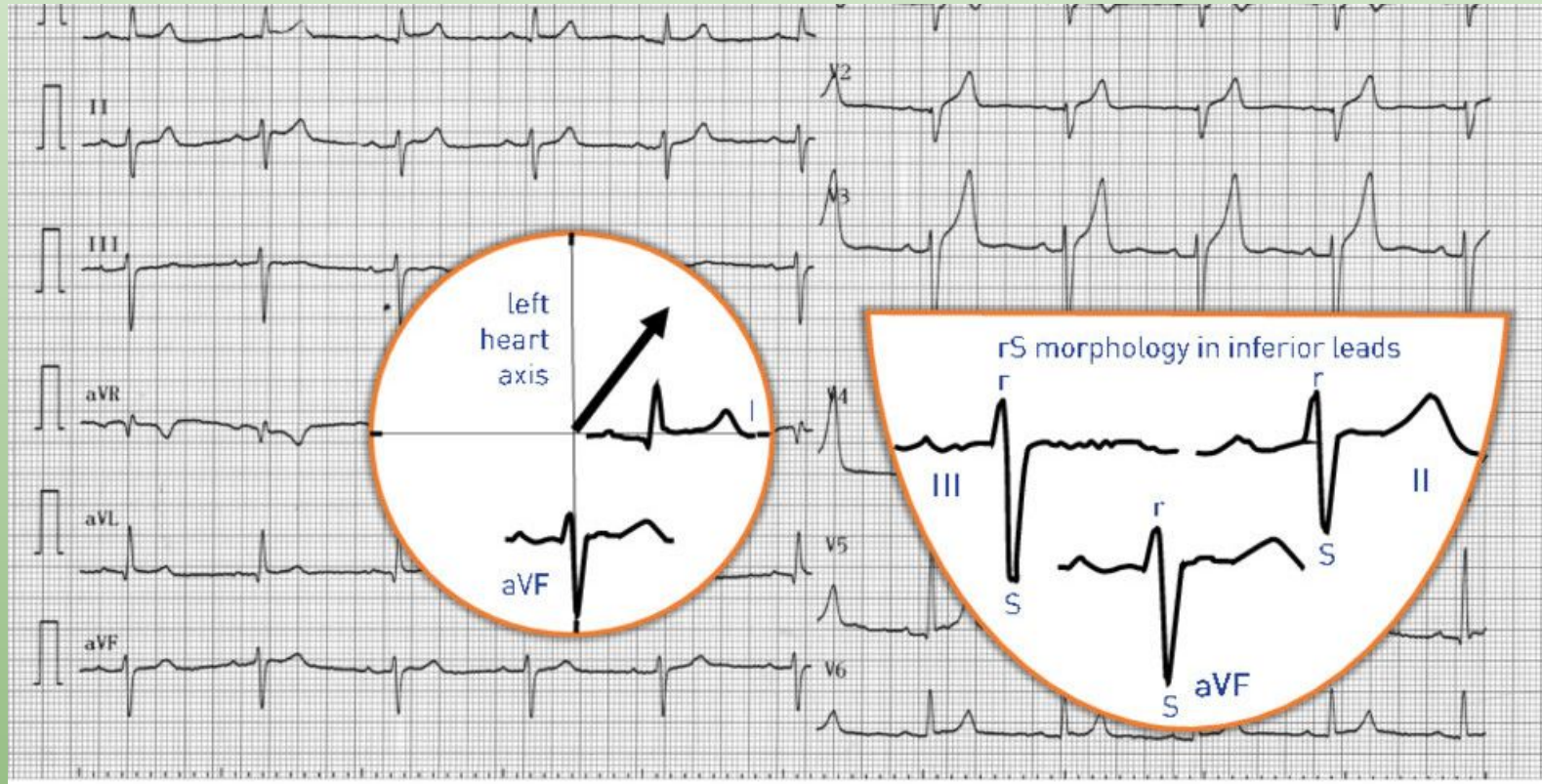


- V1 shows the right side of the heart.
- If the QRS is wide in V1 and looks like an L, it represents a LBBB
- If you look closely, V1/V6 are opposites of one another with respect to RBBB/LBBB

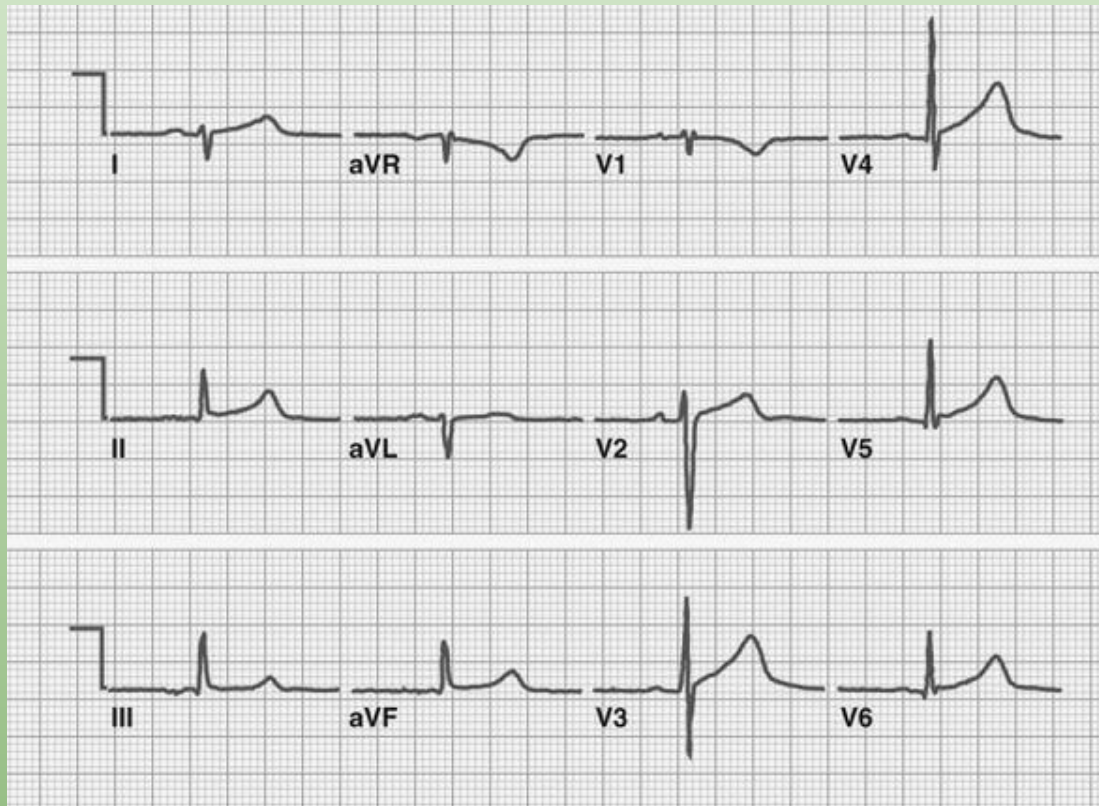
Hemi-blocks

- LBBB splits into two
- LAFB-anterior, superior, lateral
 - LAD
 - rS in III (deep, prominent S)
 - qR in I
- LPFB-posterior, inferior, medial
 - RAD
 - rS in I (deep, prominent S)
 - qR in III

LAFB



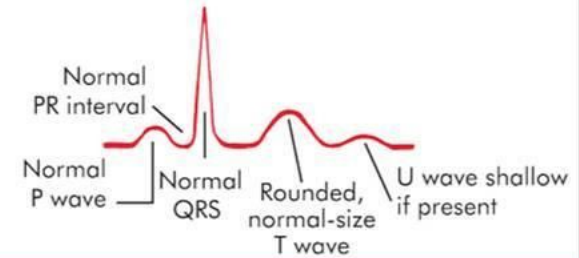
LPFB



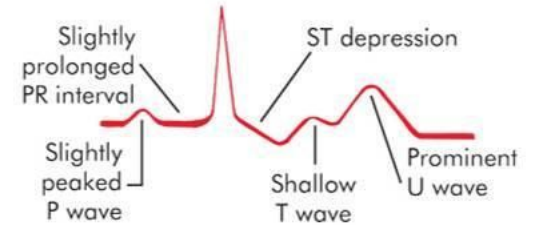
T wave

- Sensitive to changes-particularly with electrolytes
- Potassium on T wave (KT)
- Calcium on QT (by acting on ST segment-CaST)
- Digoxin-ST scooping

Normokalemia



Hypokalemia



Hyperkalemia

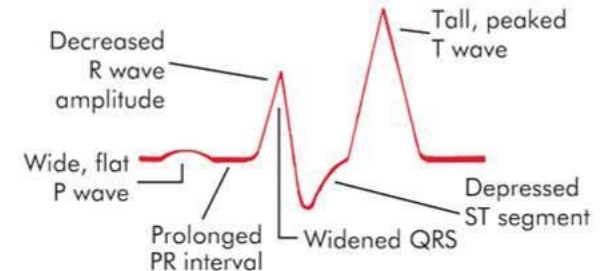


Fig. 4-7. Electrocardiogram Changes with Potassium Imbalance

T waves

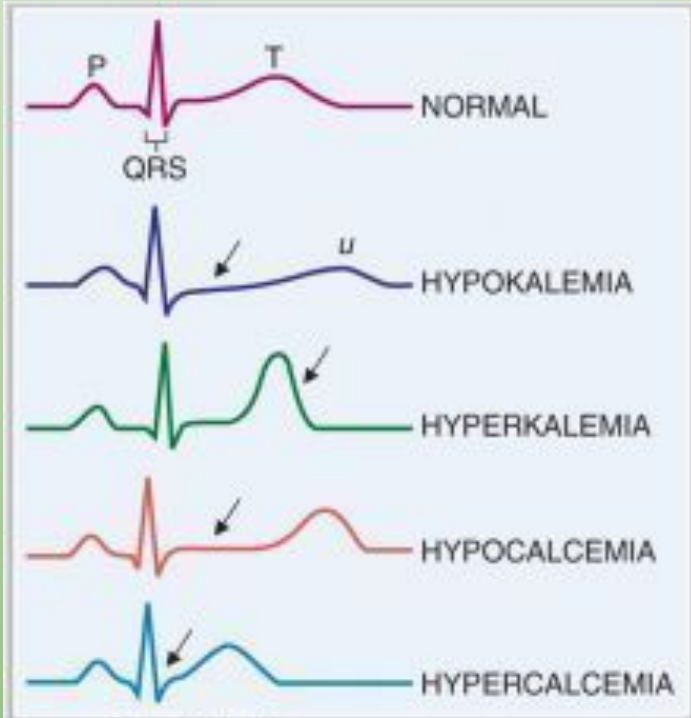
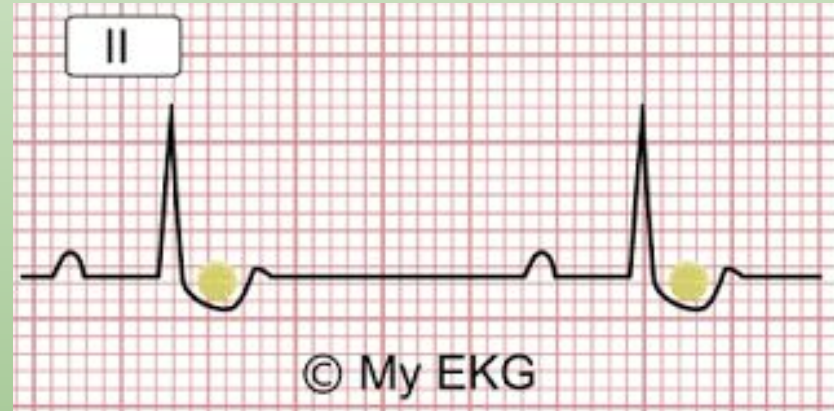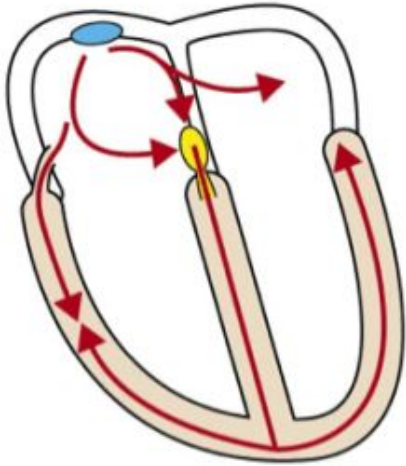


Diagram: Pathophysiology
Copyright © 2008 by Saunders, an imprint of Elsevier Inc. All rights reserved.



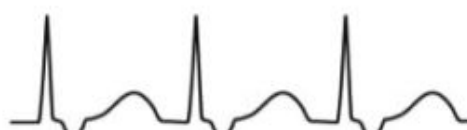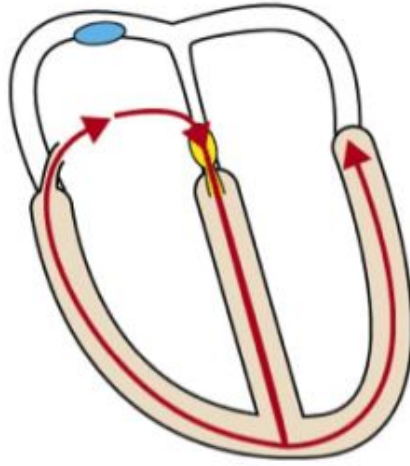
Pre-excitation



- Short PR interval
- In this case the PR segment cannot be seen.

Orthodromic AVRT

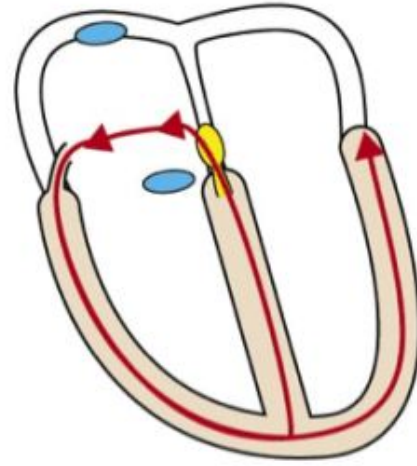
Antegrade conduction through atrioventricular node



- Normal QRS duration
- No delta wave
- Retrograde P-wave after QRS

Antidromic AVRT

Retrograde conduction through atrioventricular node



- Wide QRS complex with delta wave
- P-wave rarely seen
- If P-wave visible, it is retrograde and occurs just before the QRS

ST

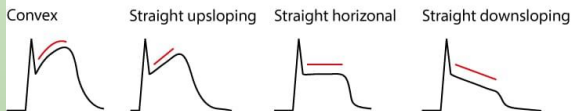- ST segment will change as a reflection of ischemia and infarction
 - Can only be called if there are reciprocal changes
 - ST depression-ischemia
 - ST elevation-infarction
 - Occurs in group of leads
 - Inferior leads-II, III, aVF, give fluids (not nitroglycerin) because problem is preload and vasodilation decreases preload
 - Septal-V1-V2
 - Lateral-I, aVL
 - Diffuse STE seen in setting of pericarditis
 - NSAIDS and colchicine

ST

- ST depression-ischemia
- Inversion T-ischemia
- ST elevation-infarction
- Q wave-old infarction

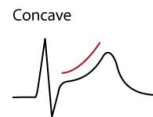
ST

A Characteristics of ST-segment elevations caused by ischemia



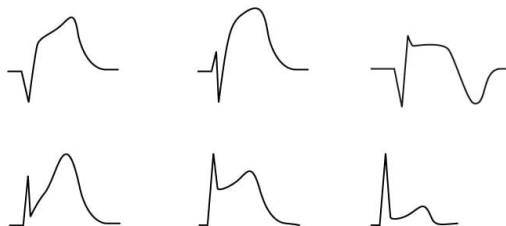
ST-segment elevations caused by ischemia typically displays a convex or straight ST-segment. Such ST-segment elevations in presence of chest discomfort are strongly suggestive of transmural myocardial ischemia. Note that the straight downsloping variant is unusual.

B Typical non-ischemic ST-segment elevation



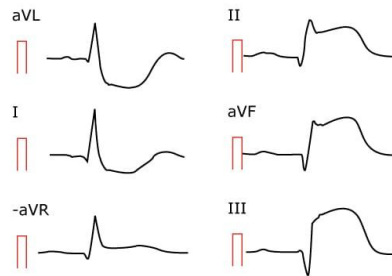
Non-ischemic ST-segment elevations are extremely common in all populations. They are characterized by a concave ST-segment and a greater distance between the J point and the T wave apex.

C Examples of ST-segment elevations caused by ischemia



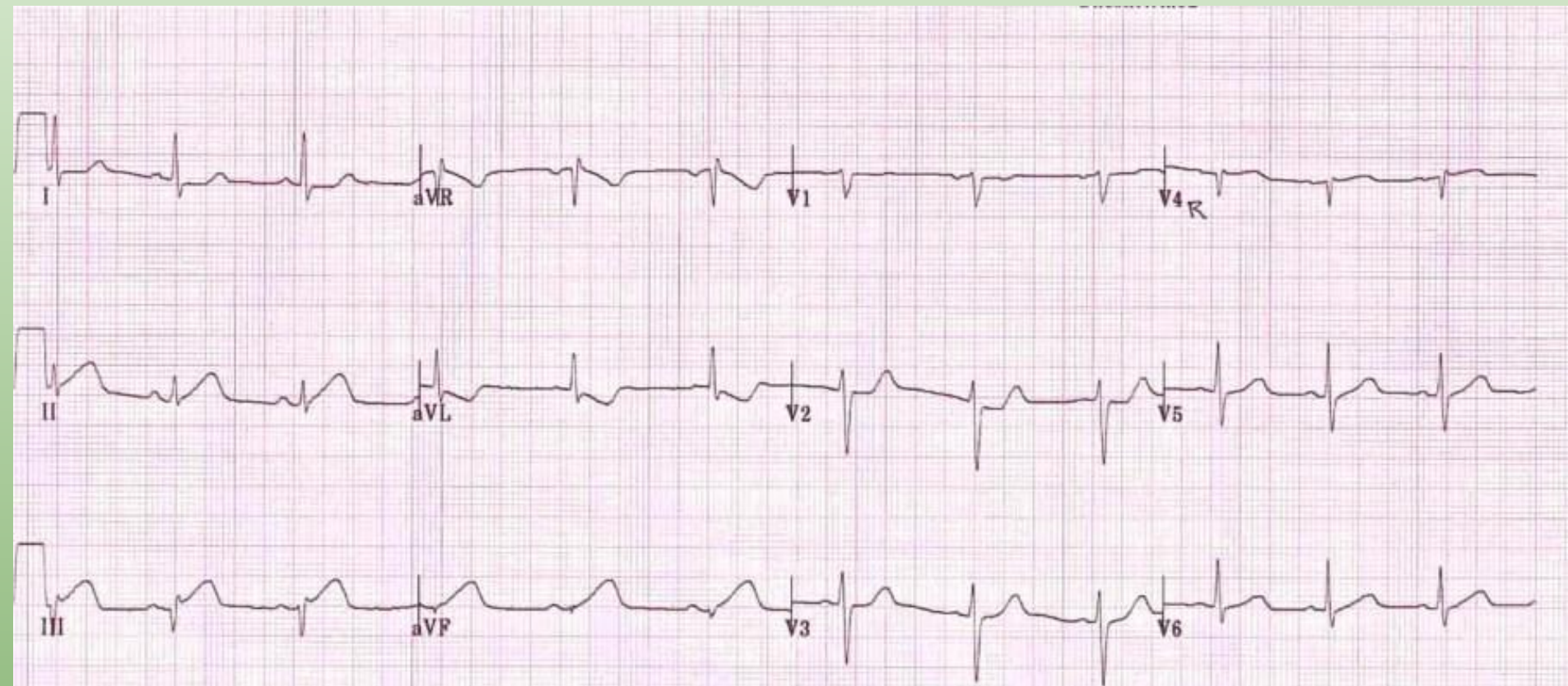
ST-segment elevation can vary markedly in appearance. These six examples were retrieved from six different patients with STEMI.

D Real life example (limb leads shown)



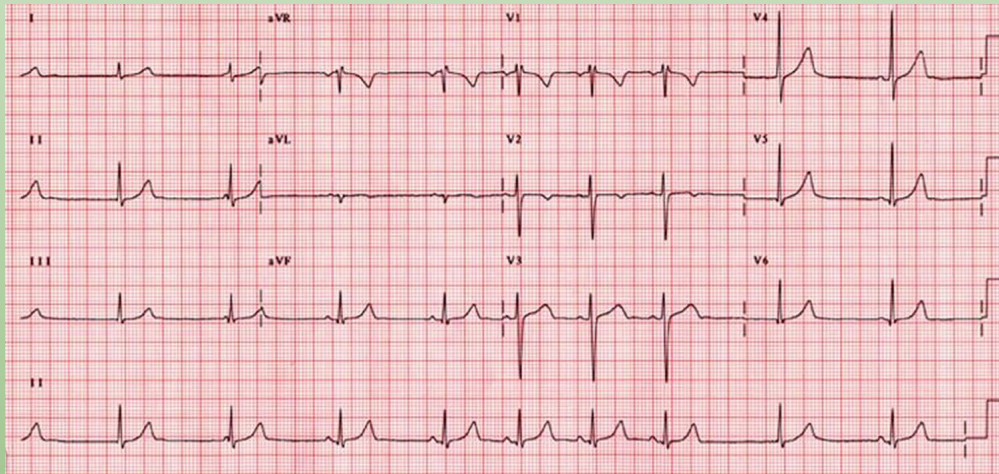
ECG from a male patient (age 61) who experienced chest pain while driving to work. Note ST-segment elevations as well as reciprocal ST-segment depressions. There are also pathological Q-waves (leads III, aVF and perhaps II).

ST



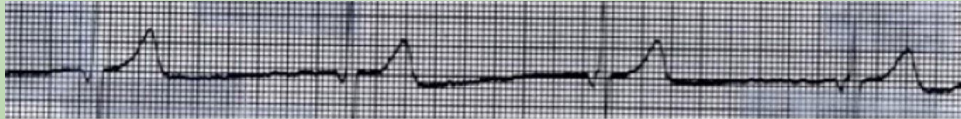Bradycardia

Sick sinus syndrome-(tachy-brady syndrome is variant) pacemaker dysfunction



Bradycardia

Junctional Escape (no P or inverted P, being saved by AV node firing)



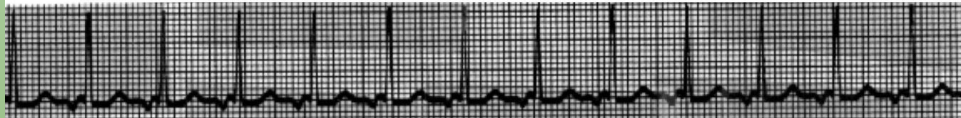
Junctional Rhythm

HR Range is 40-60 b/min



Accelerated Junctional Rhythm

HR Range is >60-100 b/min



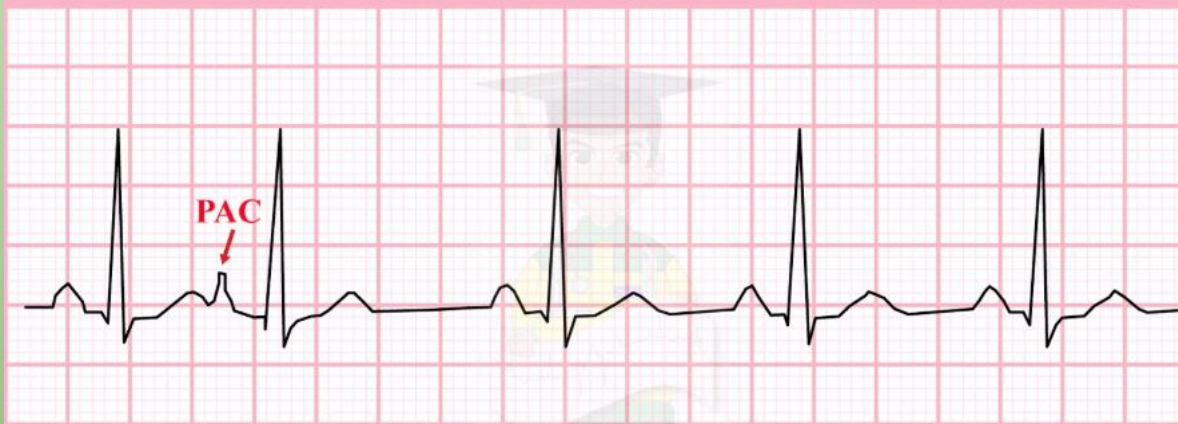
Junctional Tachycardia

HR Range is >100 b/min

Premature Beats

PAC-different morphology of P wave, QRS follows, pause after PAC

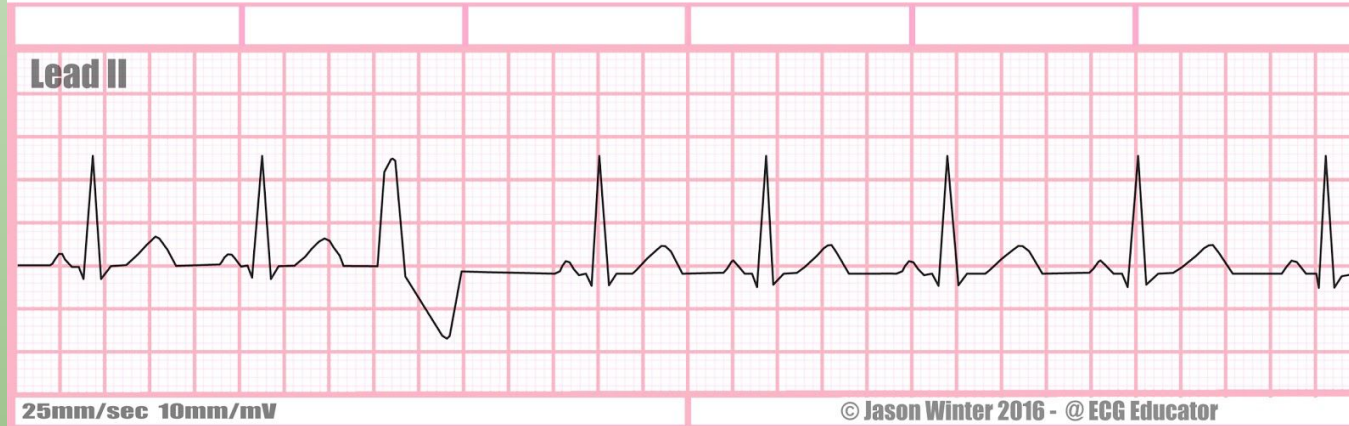
Premature Atrial Contraction (PAC)



Premature Beats

Premature Ventricular Contraction-Wide QRS, no preceding p wave, pause

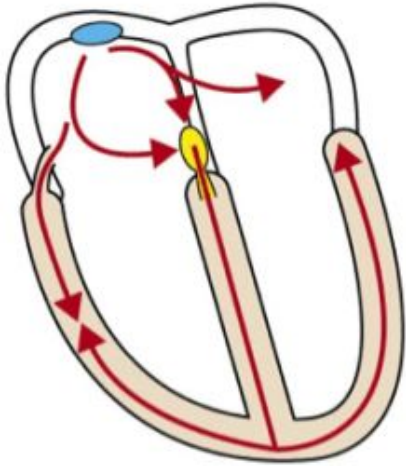
NSR with isolated PVC



SVT

- Generic term for tachycardia arising from above the ventricles
- AVRT-WPW is a pre-excitation pattern
 - Orthodromic-narrow QRS
 - Antidromic-wide QRS
- AVNRT-dependent on different characteristics of tissue around the node
- Atrial fibrillation
- Atrial flutter
- Ectopic atrial tachycardia

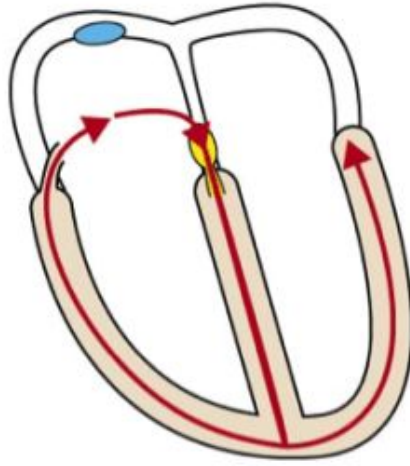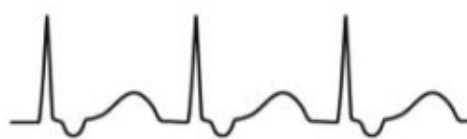
Pre-excitation



- Short PR interval
- In this case the PR segment cannot be seen.

Orthodromic AVRT

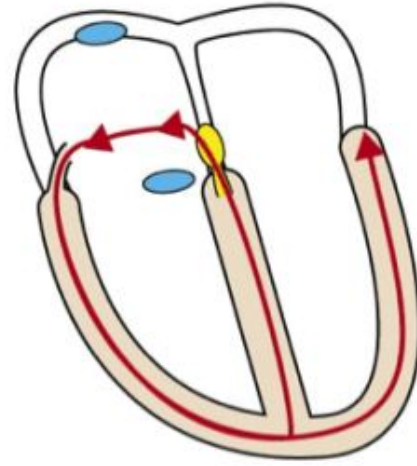
Antegrade conduction through atrioventricular node



- Normal QRS duration
- No delta wave
- Retrograde P-wave after QRS

Antidromic AVRT

Retrograde conduction through atrioventricular node



- Wide QRS complex with delta wave
- P-wave rarely seen
- If P-wave visible, it is retrograde and occurs just before the QRS

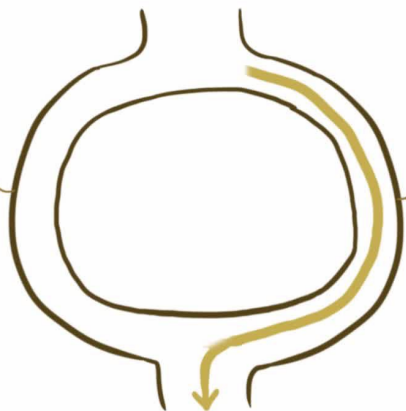
AVNRT

ATRIOVENTRICULAR NODAL REENTRANT TACHYCARDIA (AVNRT)

ATRIA

ALPHA PATHWAY

- SLOW CONDUCTION
 - SHORT [REFRACTORY PERIOD]
- time to be able to conduct again

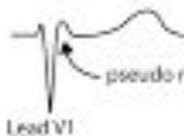
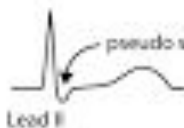

BETA PATHWAY

- FAST CONDUCTION
- LONG REFRACTORY PERIOD

VENTRICLES

A) Typical AVNRT (slow-fast): 90% of all cases



The P-wave is sometimes seen after the QRS complex. It will present itself as "pseudo s" in lead II and "pseudo r" in lead V1.

B) Atypical AVNRT (fast-slow): 10% of all cases



C) Very atypical AVNRT (slow-slow): <1% of all cases




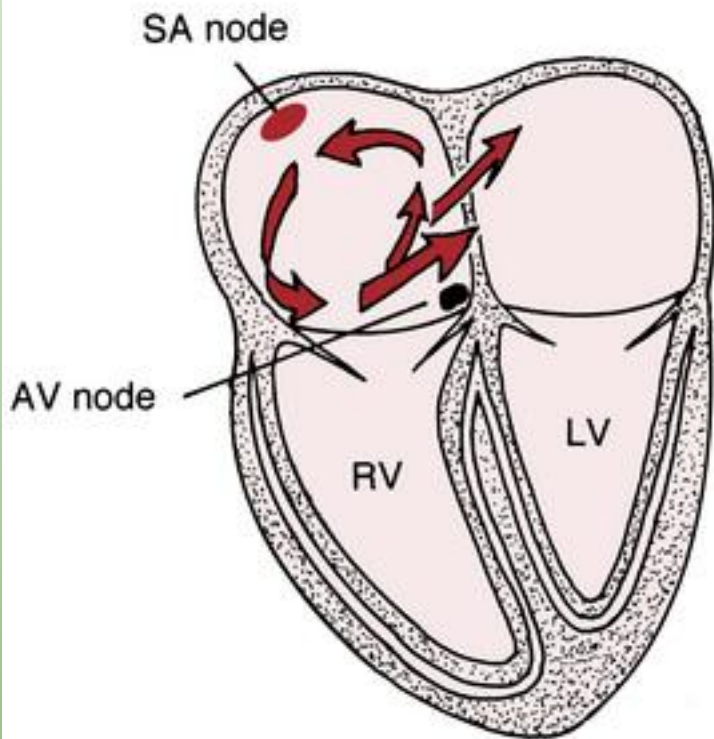
Atrial fibrillation

- Irregularly irregular
 - No p waves
 - Irregular RR intervals
- Cannot get the electrical conduction together, so it just kinda irregularly moves around and thus because it isn't a uniform signal, it cannot form a p wave, but the signal is able to get through (at varying intervals) to cause the AV node to fire to form QRS

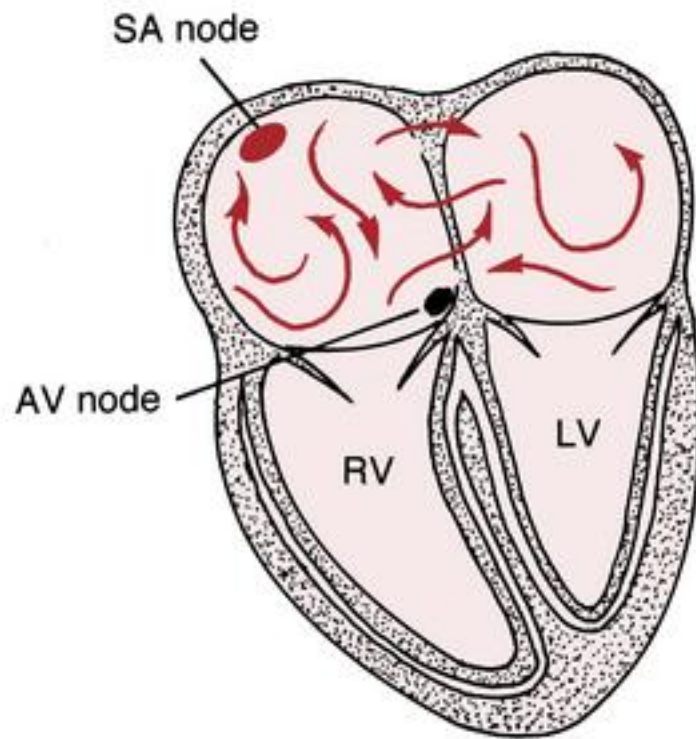
Atrial flutter

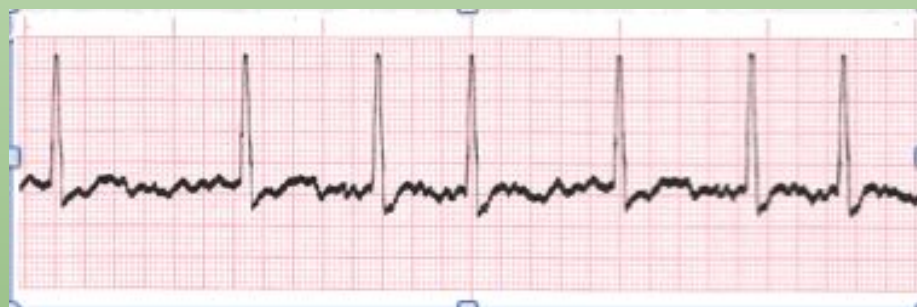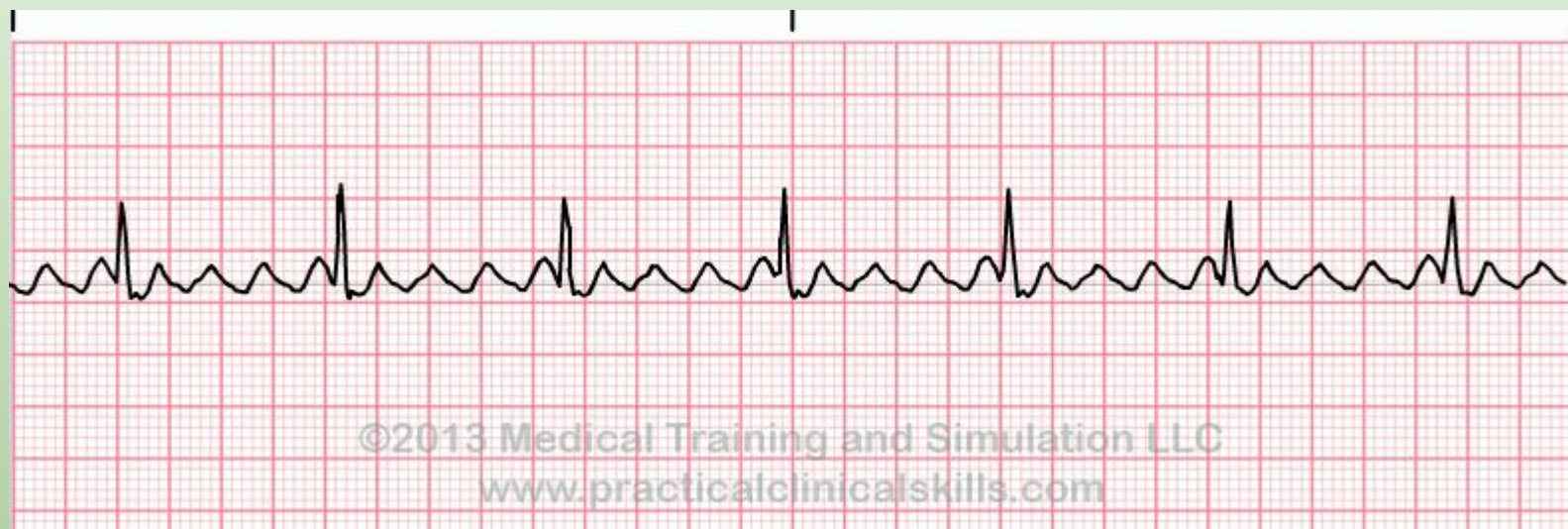- Consistent electrical circuit-but it just isn't the fastest
- Sawtooth appearance
- Consistent RR interval

ATRIAL FLUTTER



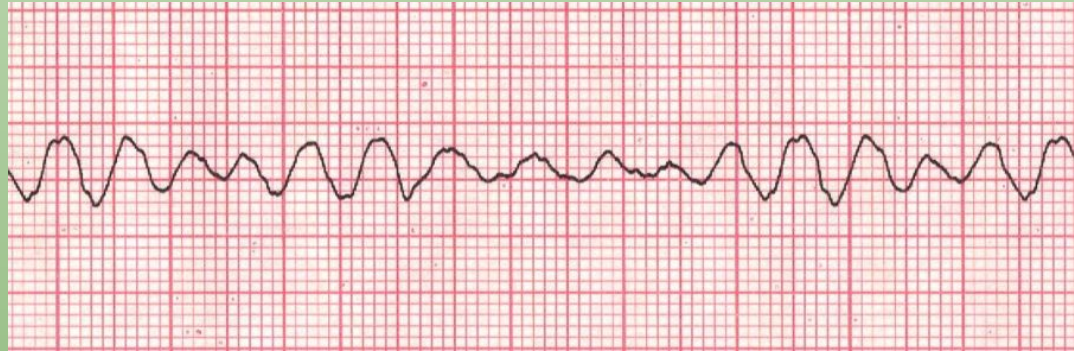ATRIAL FIBRILLATION





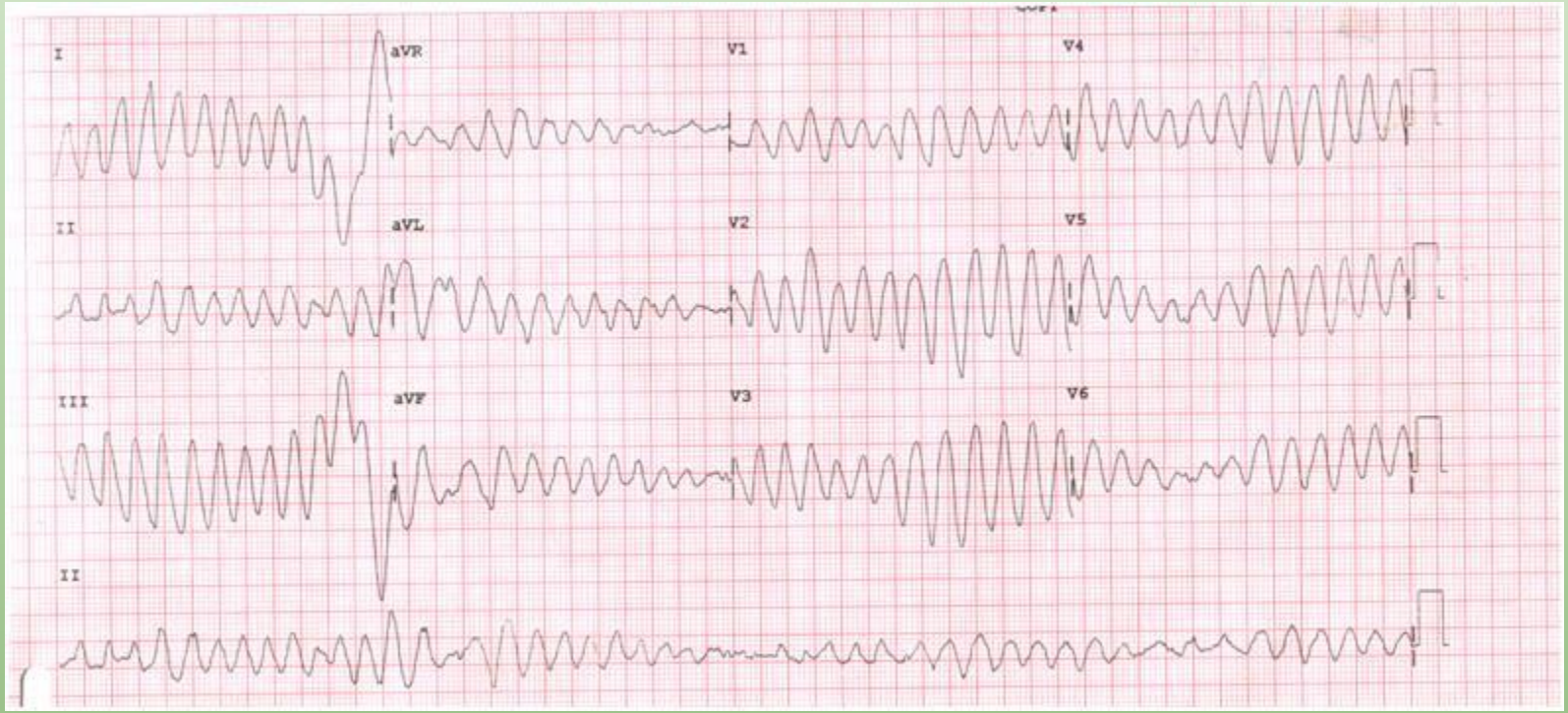
Ventricular fibrillation

- Not using the right conduction pathway
- Wide QRS
- CPR and defibrillation



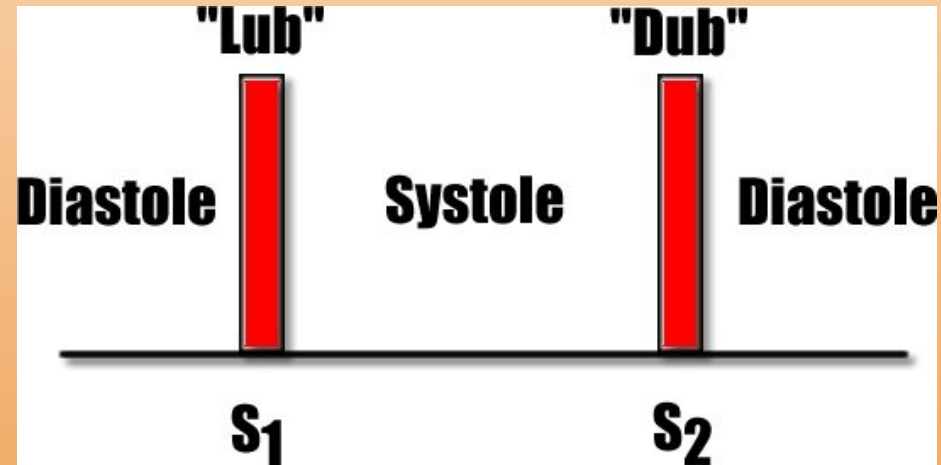
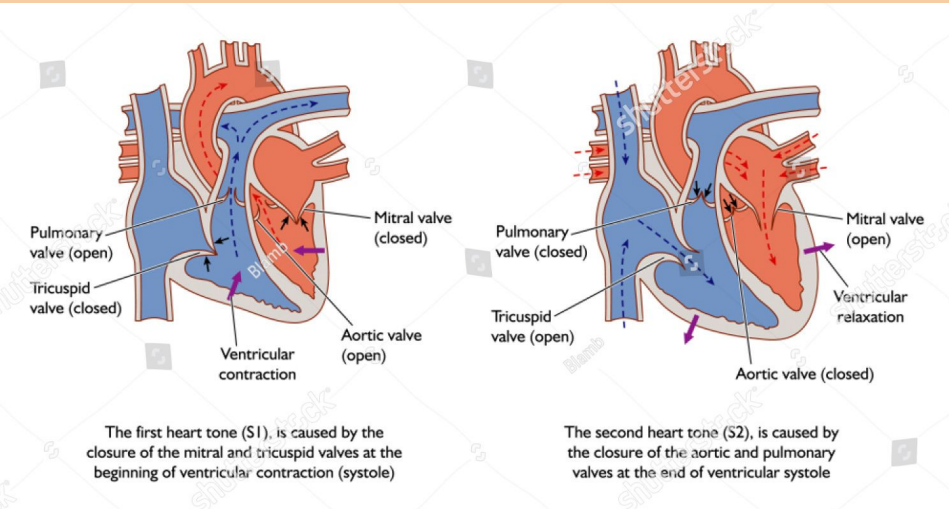
Torsades

- Form of VTach that can quickly deteriorate into VFib
- Treatment-magnesium sulfate
- Can be caused by lots of drugs
 - Ondansetron
 - TCA-give sodium bicarb in TCA poisoning
 - Anti-arrhythmics
 - Antipsychotics
 - Antibiotics-macrolides, FQN



Cardiac Cycle

- Sounds-S1 and S2
 - S1 from closure of mitral and tricuspid (onset of systole)
 - S2 from closure of aortic and pulmonic (end of systole)



Cardiac Cycle

- Murmurs occur when extra sounds are heard from obstructed blood flow
- Using knowledge of opened vs. closed valves in the cardiac cycle, you can deduce what is causing the murmur
 - Hearing a noise when a valve should be closed from regurgitant flow
 - Pulmonary valve/aortic valve-diastole
 - Tricuspid valve/mitral valve-systole
 - Hearing a noise when a valve should be opened from stenotic obstruction
 - Pulmonary valve/aortic valve-systole (ASS)
 - Tricuspid valve/mitral valve-diastole

Cardiac Cycle

- Extra heart sounds
 - S3-early diastole
 - S4-late diastole

Comparing the 3rd and 4th heart sounds

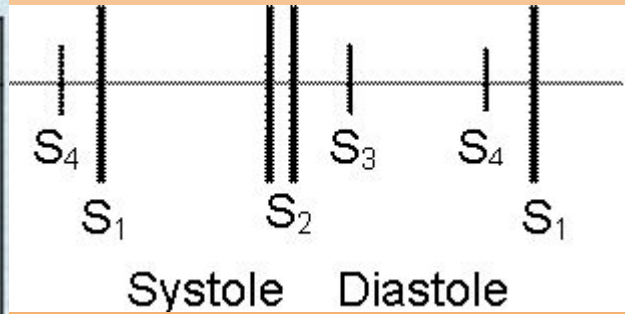
LearnTheHeart.com

S3 - "ventricular gallop"

Occurs in early diastole
Occurs during passive LV filling
May be normal at times
Requires a very compliant LV
Can be a sign of systolic CHF

S4 - "atrial gallop"

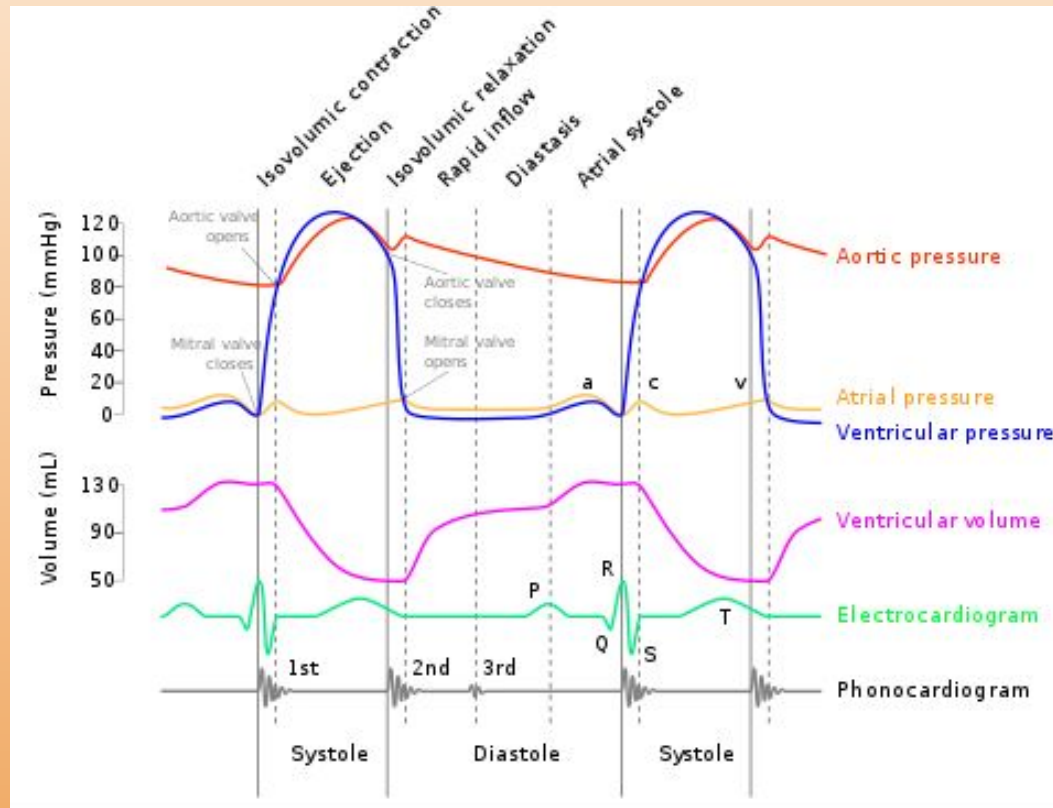
Occurs in late diastole
Occurs during active LV filling
Almost always abnormal
Requires a non-compliant LV
Can be a sign of diastolic CHF



Cardiac Cycle

- Quick advice about cardiac cycle
 - Easy to tie in lots of graphs
 - If you get lost-look at the axis and tie into the very basic concepts of cardiac physiology
 - Movement of blood dependent on pressure differentials
 - Opening of valves dependent on pressure differentials
 - Greater pressures on R side of heart than L side of heart

Cardiac Cycle



Cardiac Cycle

1. Atrial systole

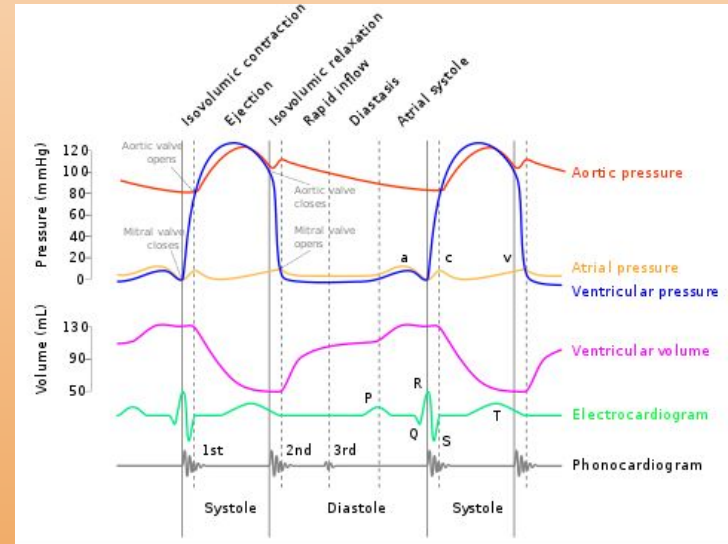
- P wave signifying atrial depolarization, ventricular filling
- Increase in atrial pressure
- Causes a wave

2. Isovolumic contraction

- Ventricular pressure > atrial pressure
- AV valve closes causing S1

3. Rapid Ejection

- Ventricular pressure > aortic pressure
- Atrial filling begins
- T wave marks end



Cardiac Cycle

4. Reduced Ejection

- Atrial filling continues
- Less pressure differential to facilitate ejection

5. Isovolumic Relaxation

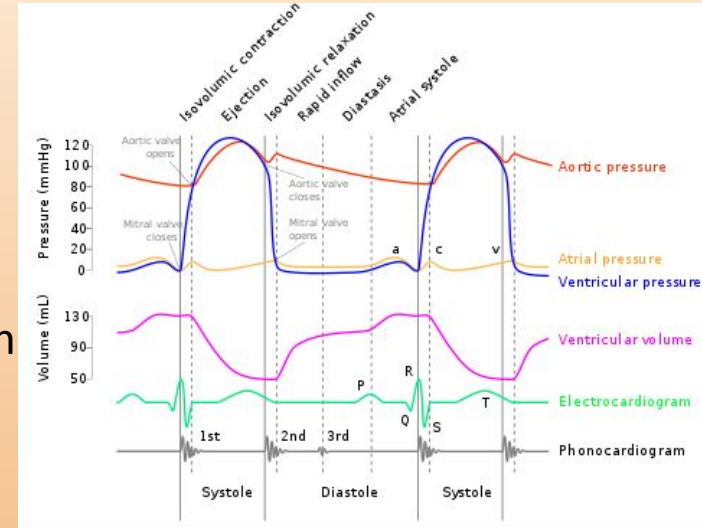
- Atrial pressure > ventricular pressure
- Mitral valve opens
- Pulmonic and aortic valve close (S2)

6. Rapid filling

- S3 can be heard (can be normal in children, fluid overload in adults)

7. Reduced filling

- Longest phase



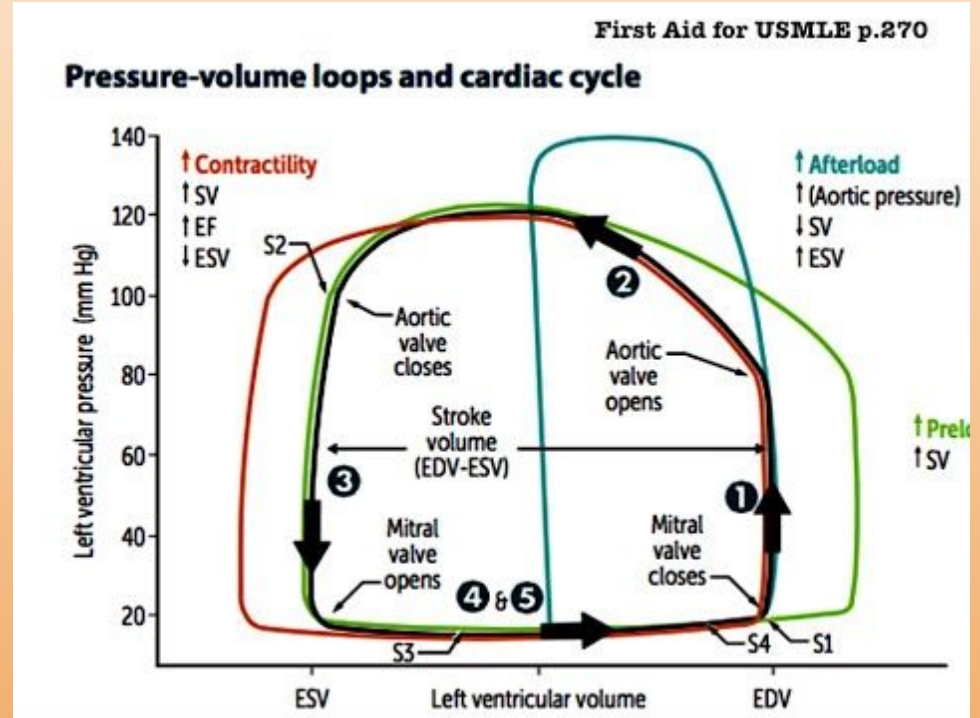
Pressure Volume Loops

$$CO = HR \times SV$$

SV affected by contractility, afterload, and preload

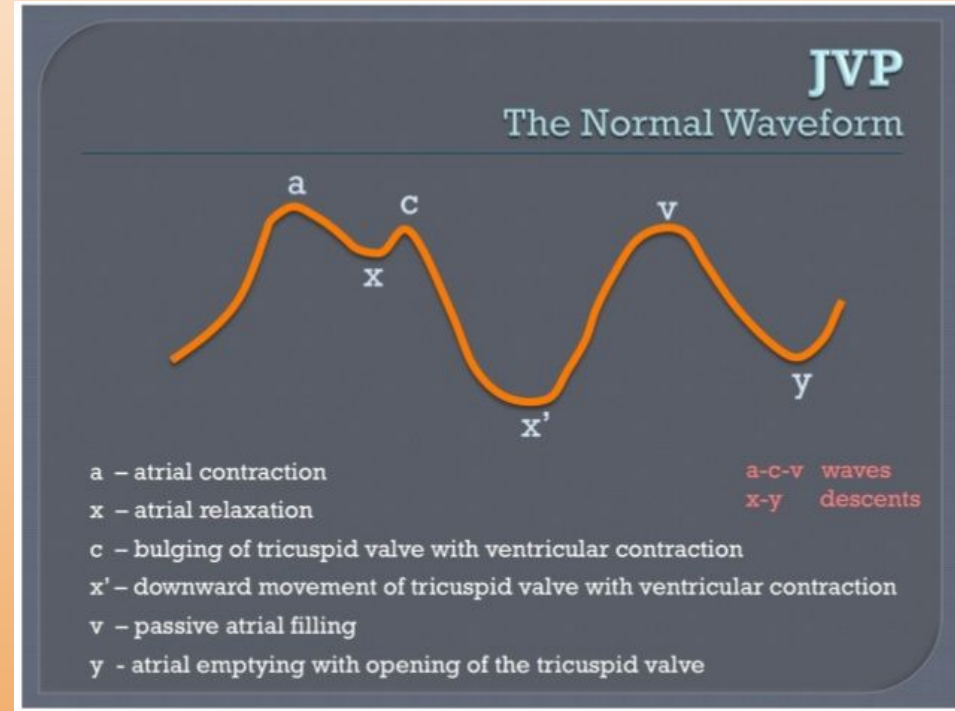
Important to understand components of cardiac cycle on this loop

1. Volume remains the same (isovolumetric contraction, pressure increases, systole)
2. Volume is now decreasing because aortic valve is open.
3. Aortic valve closes, volume remains the same because nothing can get out (isovolumetric relaxation)
4. Rapid filling into a now open ventricle

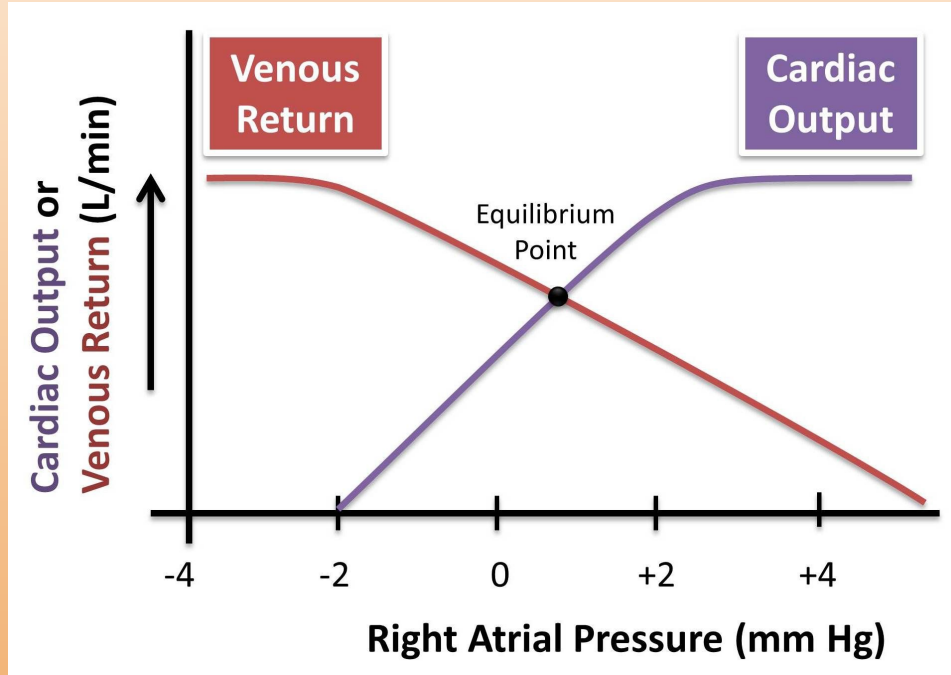


JVP Waves

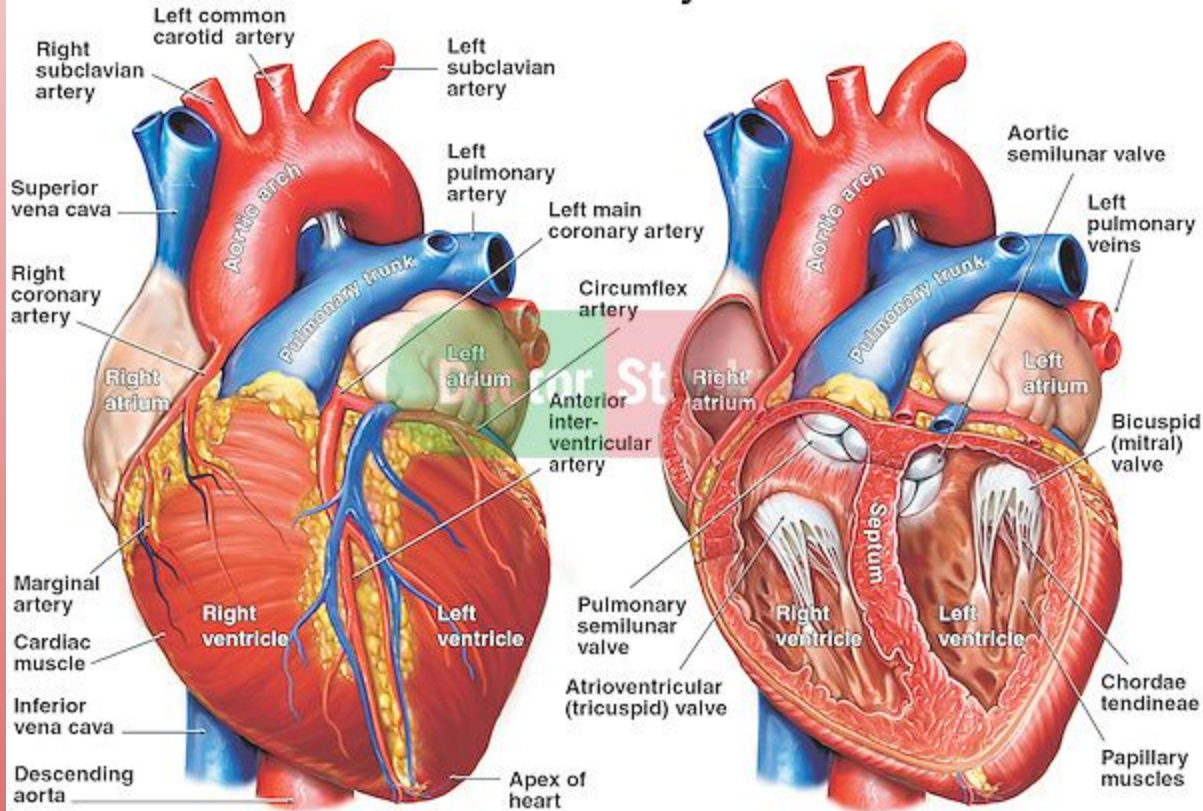
- JVP can tell you about R side of the heart
- If X is less prominent, that means too much blood is going back into the atrium (tricuspid regurgitation)
- Two normal descents-x and y
 - X is usually the dominant descent because it is occurring during contraction
 - Y is from passive early diastolic filling
 - Inflamed pericardium in pericarditis causes negative pressure making it easier to fill-prominent y
 - Tamponade causes fluid around heart that makes it difficult to fill-absent y



Cardiac Output

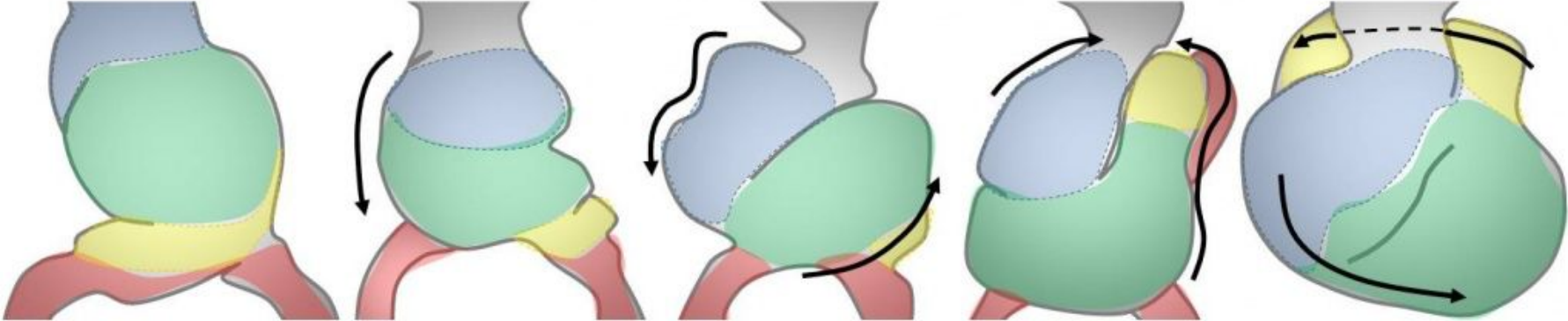


Normal Anatomy of the Heart



Embryology

Sequence of Events in Looping



Straight Heart Tube

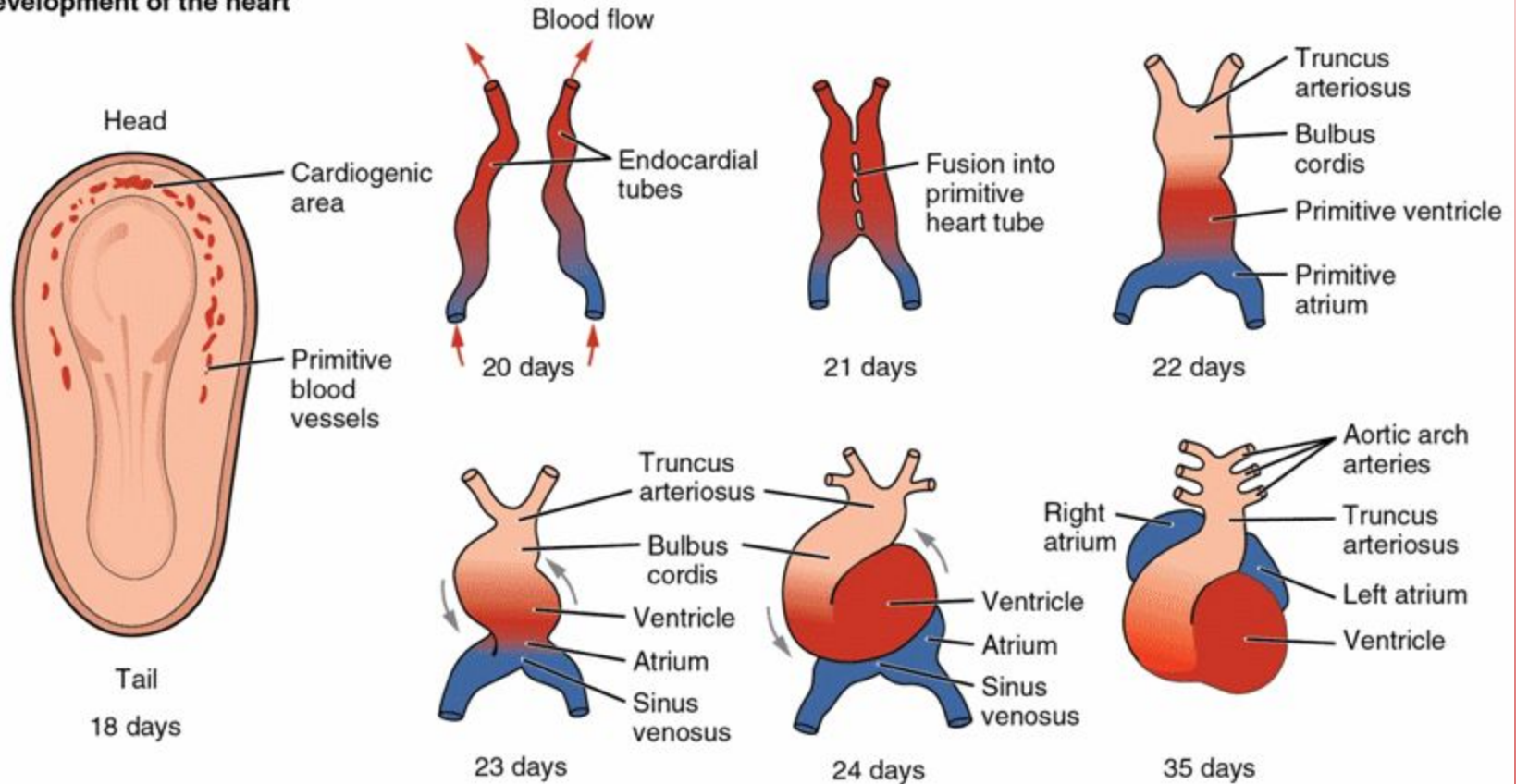
C-Shaped Loop

S-Shaped Loop

Blue = Bulbus Cordis
Green = Ventricle

Yellow = Atrium
Red = Sinus Venosus

Development of the heart



★ **Cardiogenic area begins right in the middle of head pole**

Embryology

- Truncus arteriosus-ascending aorta and pulmonary trunk
 - Failure to septate can give a cyanotic heart lesion called truncus arteriosus
- Bulbus cordis-smooth parts of left and right ventricle (LVOT, RVOT)
- Endocardial cushion-atrial septum, membranous interventricular septum; AV and semilunar valves
 - Endocardial cushion defects are common CHD with Trisomy 21 (LAD at birth)
- Primitive atrium-trabeculated LA and RA
- Primitive ventricle-trabeculated LV and RV
 - $RV > LV$, if too trabeculated indication for ASA
- Primitive pulmonary vein-smooth part of left atrium
- Left horn of sinus venosus-coronary sinus
- Right horn of sinus venosus-smooth part of right atrium
- Right common cardinal vein and right anterior cardinal vein-superior vena cava

Embryology

- Ductus arteriosus-ligamentum arteriosum
- Ductus venosum-ligamentum venosum
- Foramen ovale-fossa ovalis
- Umbilical vein-ligamentum teres hepatis

Embryology

- Aortic arches
 - 1st-maxillary artery
 - 2nd-stapedial artery
 - 3rd-common carotid artery
 - 4th-aorta
 - 5th-nothing
 - 6th-pulmonary trunk
 - 7th intersegmental-left subclavian



AORTIC ARCH ARTERIES

+ Key Features

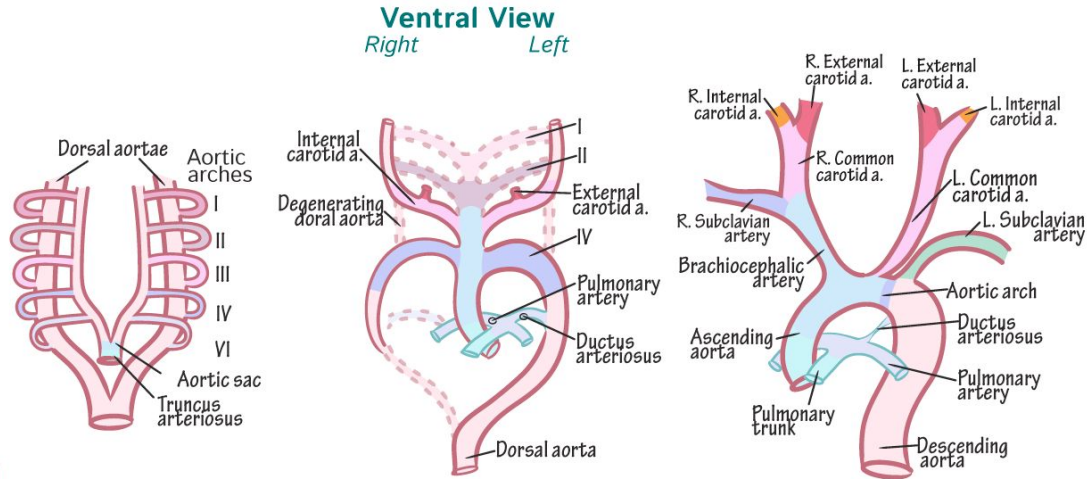
- ✓ Pharyngeal arches —
- ✓ Form weeks 4 -5
- ✓ Each arch has its own cranial nerve and artery

§ Clinical Correlation

- ✓ Patent ductus arteriosus — Persistent ductus arteriosus allows L-to-R shunt; size of opening determines degree of subsequent defects.

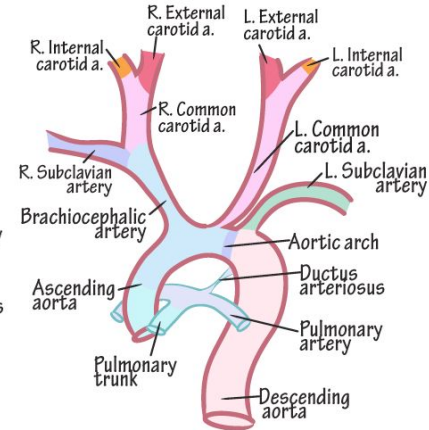
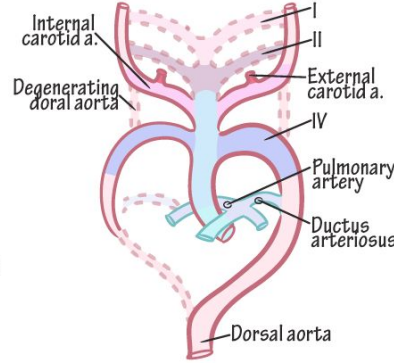
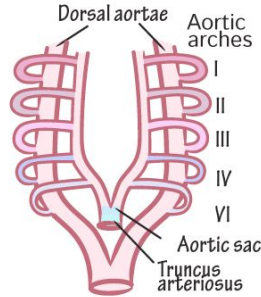
Derivatives of Aortic Arch Arteries

■ I —	Maxillary aa. (contributes)
■ II —	Stapedial aa. (contributes) Hyoid aa.
■ III —	Common carotid aa. Prox. Internal carotid aa.
■ IV —	Aortic arch (left) Right subclavian a. (proximal)
■ VI —	Left & right pulmonary aa. Ductus arteriosus (ligamentum arteriosum)



Ventral View

Right Left



Week 5

- ✓ Arches arise ventrally from aortic sac
- ✓ Arches terminate at dorsal aortae

Week 7

- ✓ Dorsal aortae degenerate
- ✓ I & II degenerate
- ✓ III grows, forms common & internal carotid arteries
- ✓ IV grows asymmetrically
- ✓ VI forms pulmonary aa., Ductus arteriosus

Week 8

- ✓ Single aorta w/arch
- ✓ Three major branches
- ✓ L. recurrent laryngeal nerve wraps under arch;
- ✓ R. recurrent laryngeal nerve wraps under r. subclavian artery.

Vessels and Circulation

- Lymphatics
 - Junction of adjacent endothelial cells overlap forming a valve
 - Muscles work to pump lymphatics (myogenic response)
- Filtration and absorption determined by permeability and pressure differentials
 - $P_c - P_i - (\text{ONC}_c - \text{ONC}_i)$
 - Positive leads to filtering
 - Edema occurs when filtration exceeds rate of capillary reabsorption
 - Negative leads to reabsorption

Circulation

- Heart
 - Because of origin of coronary arteries, as HR increases, less time for perfusion
- Cerebral
 - Autoregulation between 60 and 130 mmHg
 - Sensitive to changes in pCO₂
- Autonomics
 - Parasympathetic-Ach to muscarinic vasodilates
 - Sympathetic-Epi to adrenergic vasoconstricts

Radiology

- PA CXR is standard (chest against film)
- AP CXR if patient is supine (super common in hospital for admitted patients)
- L higher than R due to stomach, gas bubble should be seen
- Spinous processes midline, clavicle medial
- Inspiration-6/7 anterior, 9/10 posterior
- Penetration-how much XR goes through, over penetration is black, under penetrated cannot see intervertebral discs

Radiology

PA

VS

AP

