

MS 2 Cardiology Exam

Amanda Krauss, Alex Ratnani, Adeel El-Hamdani

General Advice

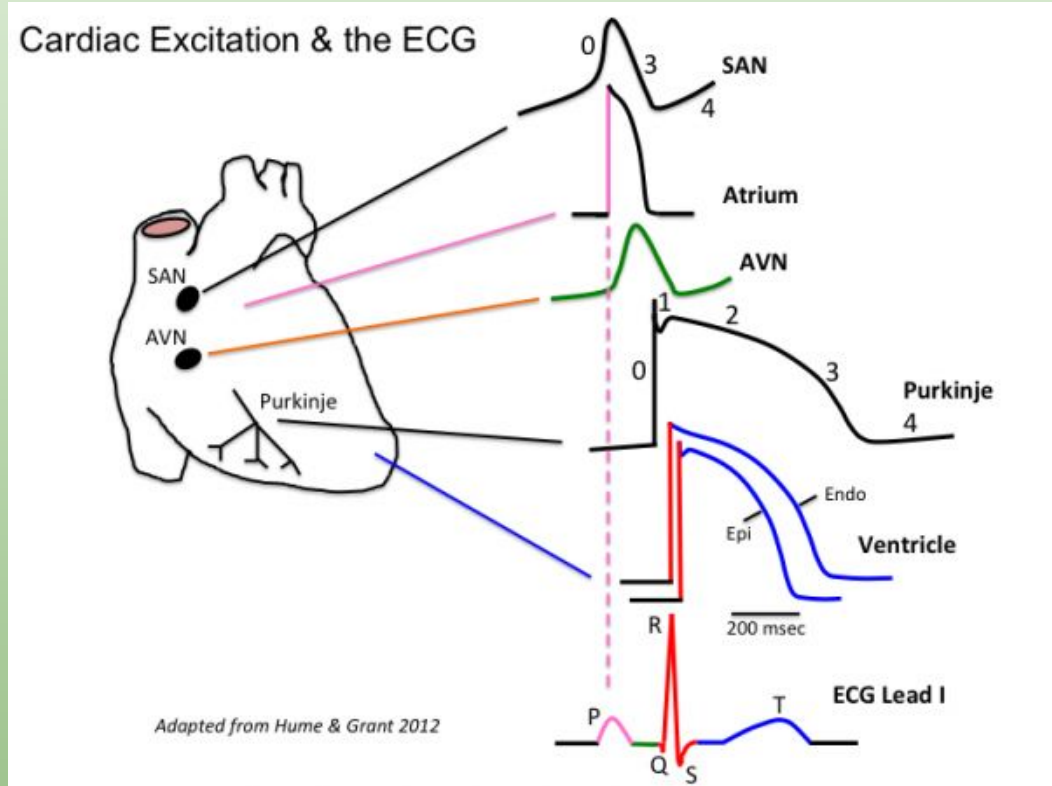
Having a good grasp on cardiology will serve you well on every exam from this day out-high yield on Step 1, Step 2 CK, and most of the shelf exams next year

Cardiology is an easy topic to tie genetics and embryology into. It is also easy to tie in graphs to confuse you.

As a disclaimer, the lecturers for this block have changed since I took the exam. I have consulted some classmates to ensure I cover difficult lectures and high yield topics. However, I did not look through all your lectures. This is a compilation of notes I have from two years ago, difficult lectures, First Aid, and NBME style questions.

Cardiac Physiology-Electrical Conduction

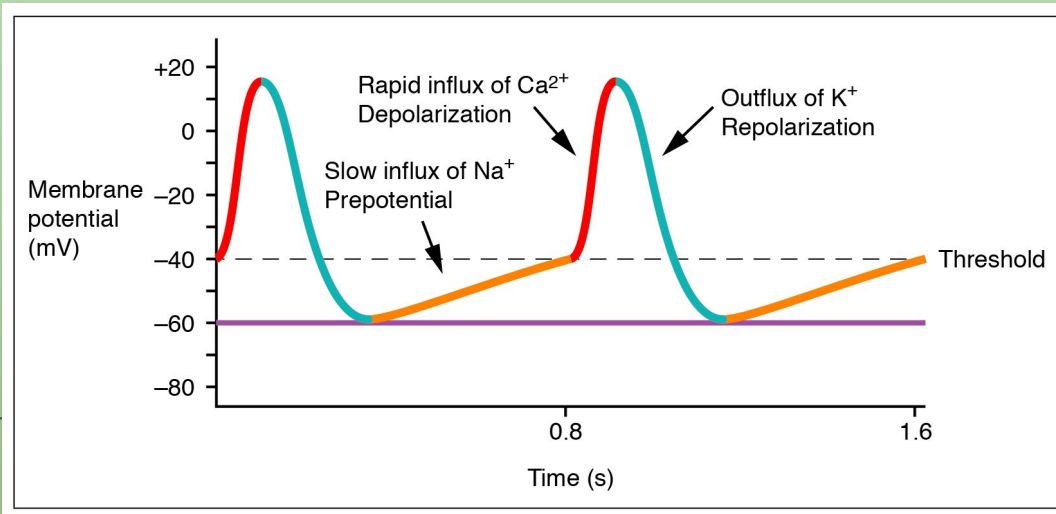
- Normal conduction system goes SA to AV to Bundle of His to Bundle Branches (Right, Left Anterior and Left Posterior), Purkinje fibers
- Two different electrically conducting cells
 - SA node and AV node
 - Funny current adds to rhythmicity of these pacemakers
 - Purkinje and Bundles
 - Lacks funny current
- The small differences in ion conduction play into autonomics and medications



Cardiac Physiology-Electrical Conduction

- Pacemaker (SA and AV)

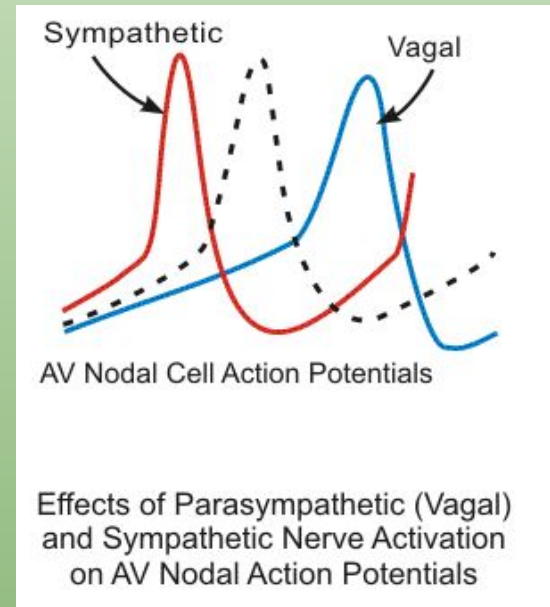
- SA goes faster, delay in AV allows for the ventricles to fill with blood for an effective SV
 - SA fires, depolarizes atria (P wave)
 - Delay in AV before AV fires, depolarizes ventricles (QRS)
 - Delay in AV represented by PR interval



4-Na funny current
0-Ca influx
3-K efflux

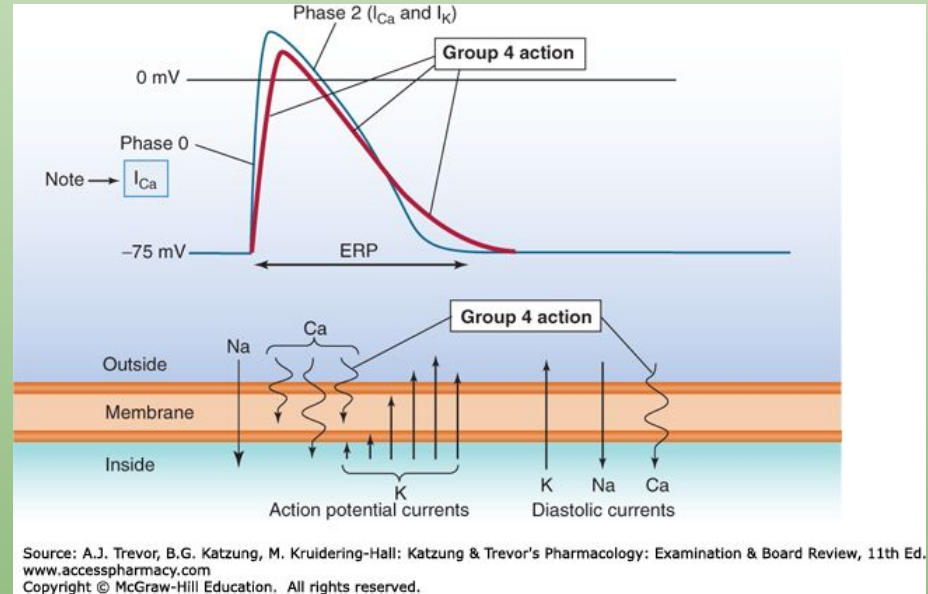
Cardiac Physiology-Electrical Conduction

- Sympathetics-Increased conduction of Ca (increase HR)
 - Beta 1 activation leads to increased Ca, steeper 4
- Parasympathetics-Increased conduction of K (decrease HR)
 - M2 activation leads to increased K, further from threshold



Cardiac Physiology-Electrical Conduction

- Anti-arrhythmics
 - Class II-Beta blockers (nodal)
 - Class IV-Calcium channel blockers (nodal)

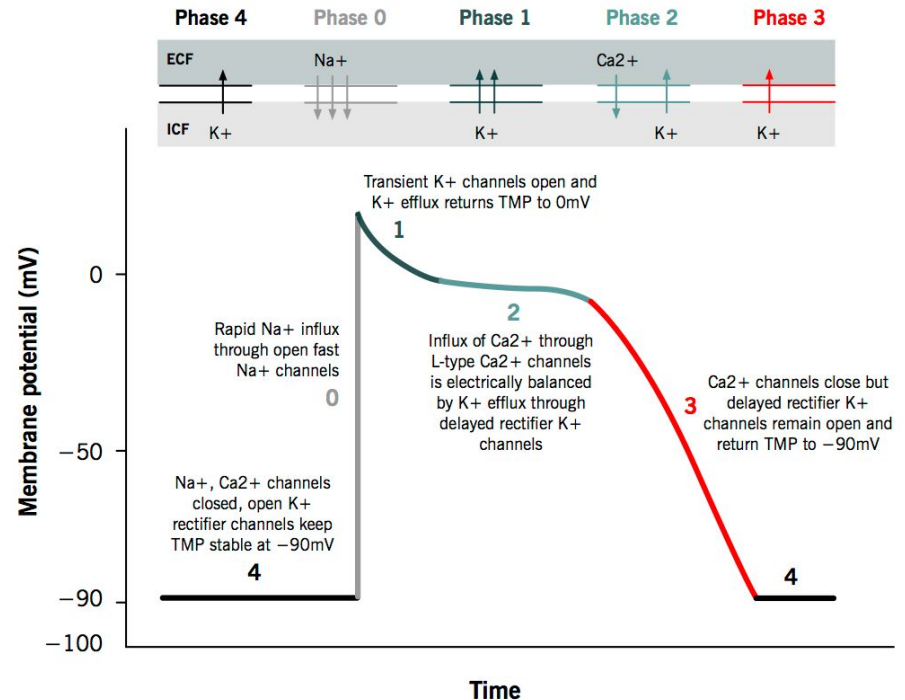


Cardiac Physiology-Electrical Conduction

- Conduction at non-nodal sites
 - Bundles, Purkinje, etc.

Action potential of cardiac muscles

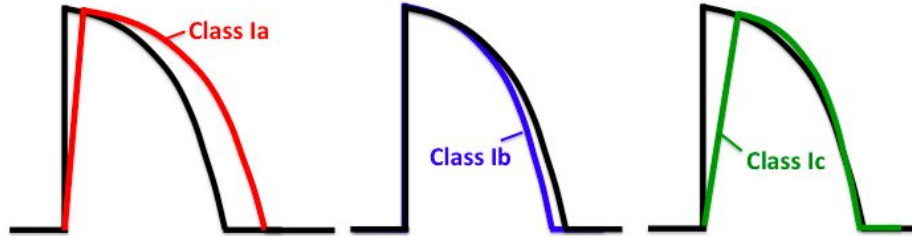
Grigoriy Ikonnikov and Eric Wong



Cardiac Physiology-Electrical Conduction

Class I Antiarrhythmic Drug Effects

On the Ventricular Action Potential:

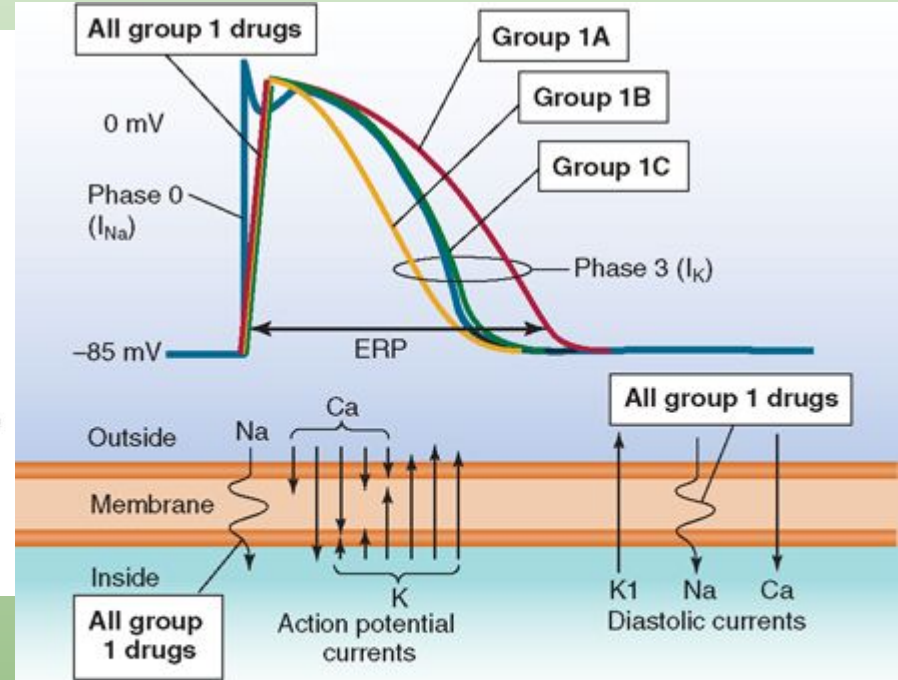


On the ECG:

↑QRS & ↑QT

↓QT

↑↑QRS



Source: Trevor AJ, Katzung BG, Kruidering-Hall M, Masters SB: *Katzung & Trevor's Pharmacology: Examination & Board Review*, 10th Edition: www.accesspharmacy.com

Copyright © The McGraw-Hill Companies, Inc. All rights reserved.

Anti-arrhythmic drugs

- IA: Quinidine, Procainamide, Disopyramide***
 - Procainamide-WPW, can cause drug induced SLE
- IB: Lidocaine, Mexiletine, Phenytoin
 - Post-MI
- IC: Flecainide, Propafenone
 - Cannot use if ischemic heart disease is present
- III: Amiodarone, Ibutilide, Dofetilide, Sotalol***
 - Amiodarone has TONS of SE (gray skin, hypo or hyperthyroid, pulmonary fibrosis, cirrhosis)
 - Used frequently to treat a. Fib, requires hospital admission to initiate because of QT monitoring

***Know which drugs cause torsades

Anti-arrhythmic Drugs

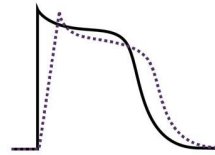
Antiarrhythmics

Class I

Decreased slope of phase 0 depolarization

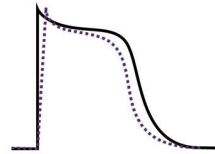
Class IA

↑ ERP
↑ AP duration



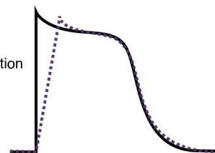
Class IB

↓ ERP
↓ AP duration



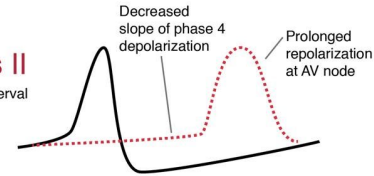
Class IC

Normal ERP
Normal AP duration



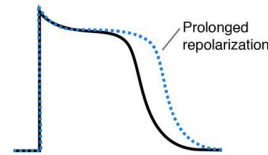
Class II

↑ PR interval



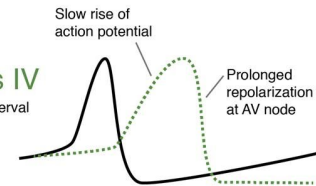
Class III

↑ ERP
↑ AP duration



Class IV

↑ PR interval
↑ ERP

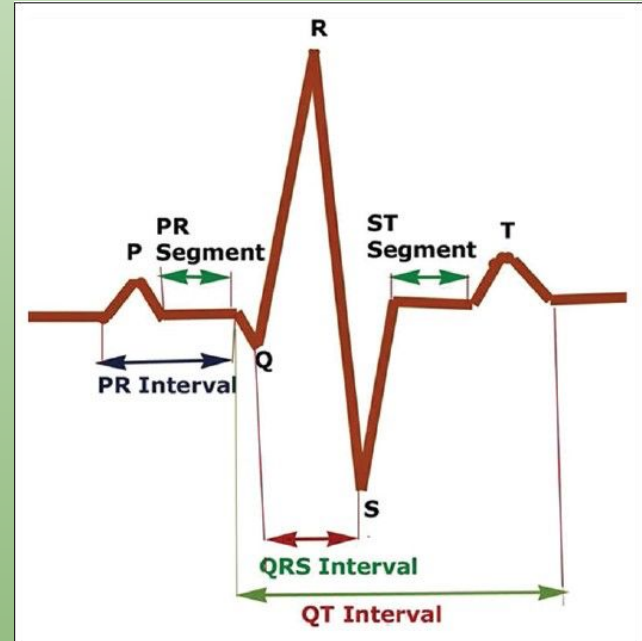
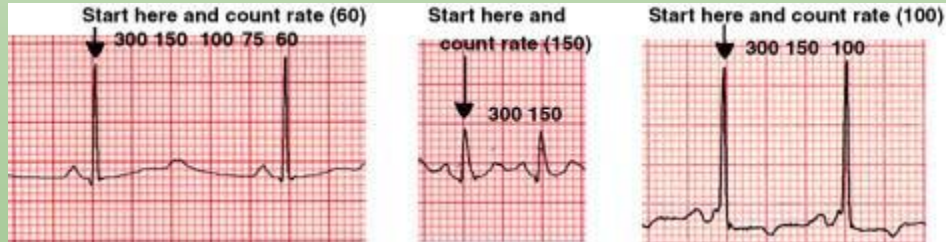


EKG

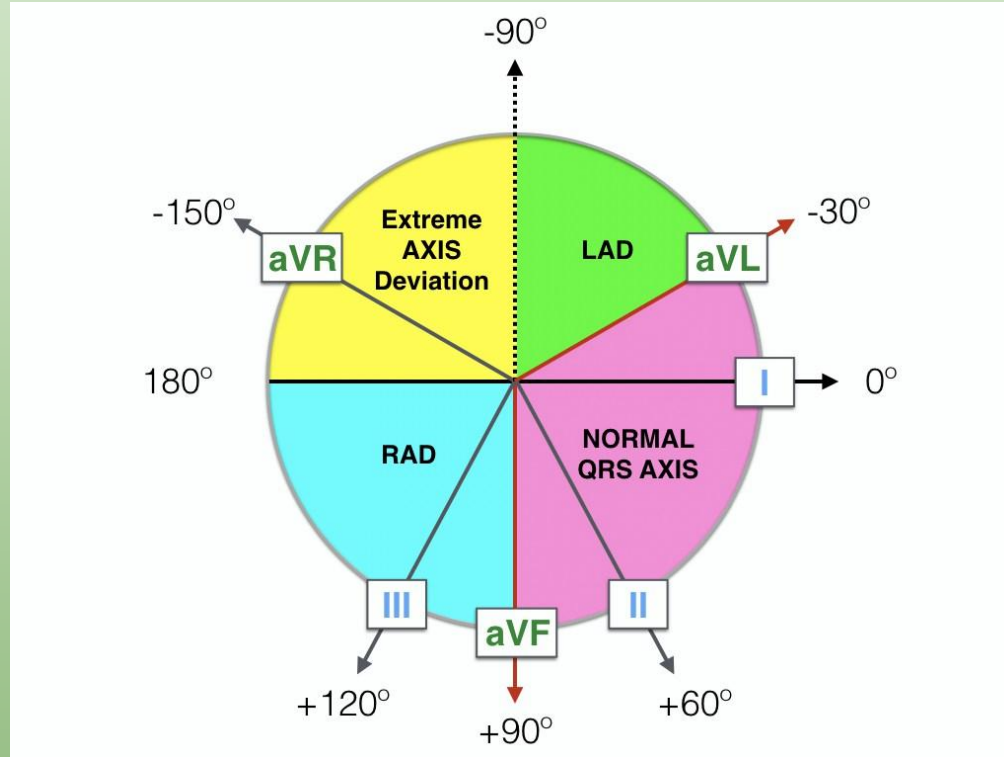
- Hard to know the basics because they seem so simple until you are put on the spot
- Try to understand rather than just memorize and recognize a pattern
- Dr. Petrany does a great job teaching a systematic way of going through EKGs-rate, rhythm, axis, PR, QRS, ST, QT
 - Admittedly lower yield for Step 1 but high yield for shelf exams and Step 2
 - Regardless of which field you go into-you WILL order an EKG on your patient at some point-so know how to read them

Back to Basics-lower yield for Step 1

- Rate 60-100, count off method (300, 150, 100, 75, 60)
 - If they give you a 12 lead with a rhythm strip-x6

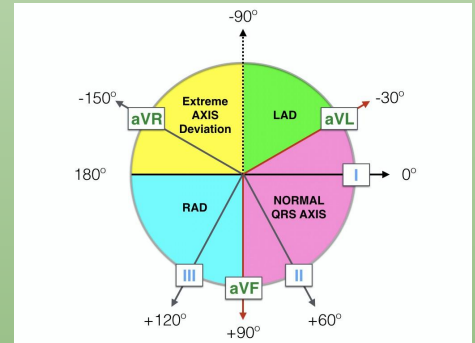


Back to Basics-Axis



Back to Basics

- Axis-normal from -30 to 90
 - Remember that positive currents mean that the net depolarization is going towards that lead
 - Lead I lines up with 0 and aVF lines up with 90
 - If they are both positive you are between 0 and 90
 - If aVF is positive and I is negative you have RAD
 - If I is positive and aVF is negative, you are between 0 and -90
 - To determine if LAD or normal, look at II
 - If II is positive-NAD
 - If II is negative-LAD



PR Interval

- Atrial depolarization to ventricular depolarization
 - Tells you if the conduction from SA to AV node is working
- Shortened ($<.2$) in WPW because the Bundle of Kent depolarizes before the conduction from SA to AV occurs
- Prolonged ($>.2$) in AV Blocks

QRS

- Back to the rule that normal conduction is the fastest-if the QRS is prolonged that means that the normal conduction pathway is not working
- Recall that the heart depolarizes SA->AV->Bundle of His (RBB and LBB, LBB further splits into anterior and posterior fascicles->Purkinje)
- If the heart is using the normal conduction pathway, the QRS (ventricular depolarization) should be less than .12s
- If the heart cannot use that conduction pathway because there is a block or current is going the wrong direction, it will take $>.12s$
 - RBBB, LBBB, pacemaker, WPW

ST

- ST segment will change as a reflection of ischemia and infarction
 - Can only be called if there are reciprocal changes
 - ST depression-ischemia
 - ST elevation-infarction
 - Occurs in group of leads
 - Inferior leads-II, III, aVF, give fluids (not nitroglycerin) because problem is preload and vasodilation decreases preload
 - Septal-V1-V2
 - Lateral-I, aVL
 - Diffuse STE seen in setting of pericarditis
 - NSAIDS and colchicine

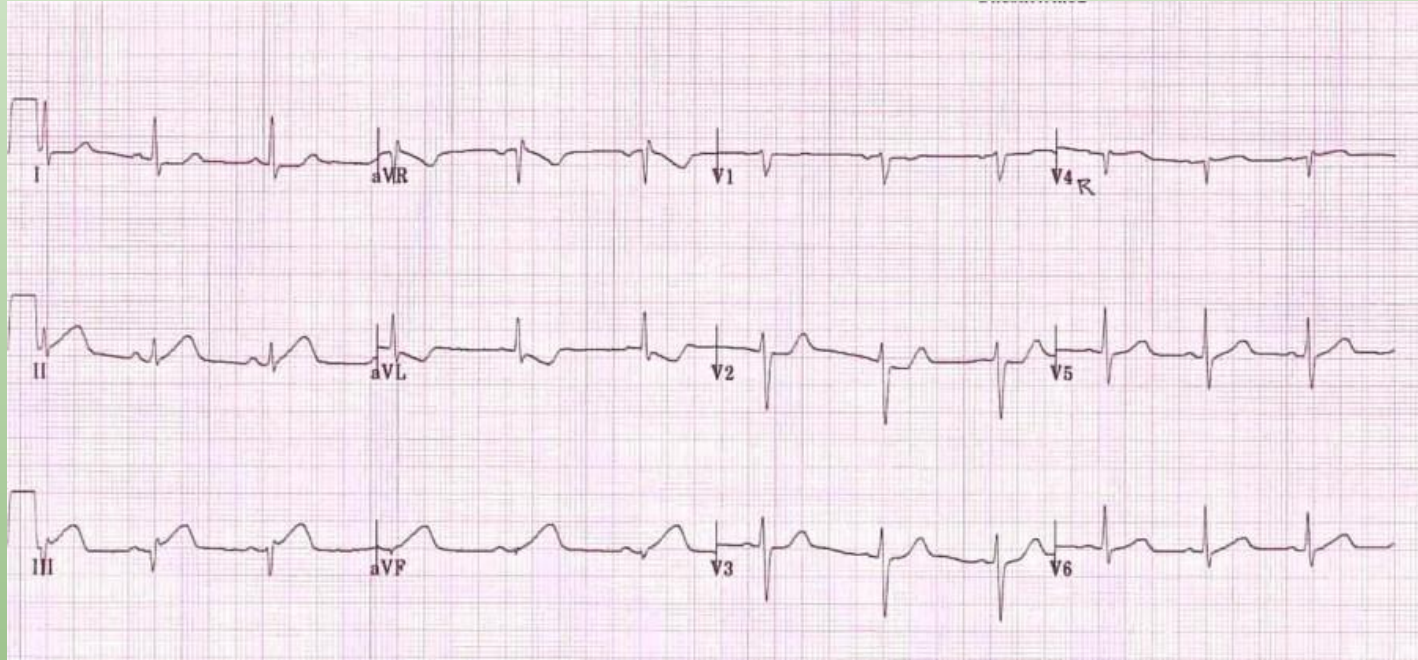
ST

- Important to know groupings because they signify which artery is occluded
 - Nodes supplied by RCA
 - Can get HB from inferior MI
 - Dominance becomes important
 - MC PDA from RCA (R dominant)
 - PDA from LCX (L dominant)

Lead Summary

I Lateral Circumflex Artery	aVR	V1 Septal Left Anterior Descending Artery	V4 Anterior Right Coronary Artery
II Inferior Right Coronary Artery	aVL Lateral Circumflex Artery	V2 Septal Left Anterior Descending Artery	V5 Lateral Circumflex Artery
III Inferior Right Coronary Artery	AVF Inferior Right Coronary Artery	V3 Anterior Right Coronary Artery	V6 Lateral Circumflex Artery

ST

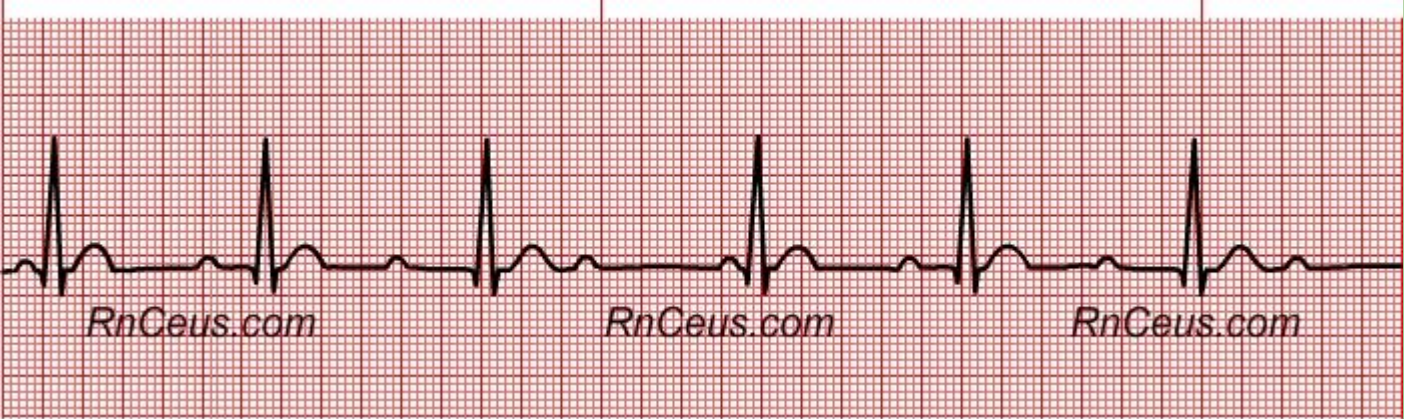
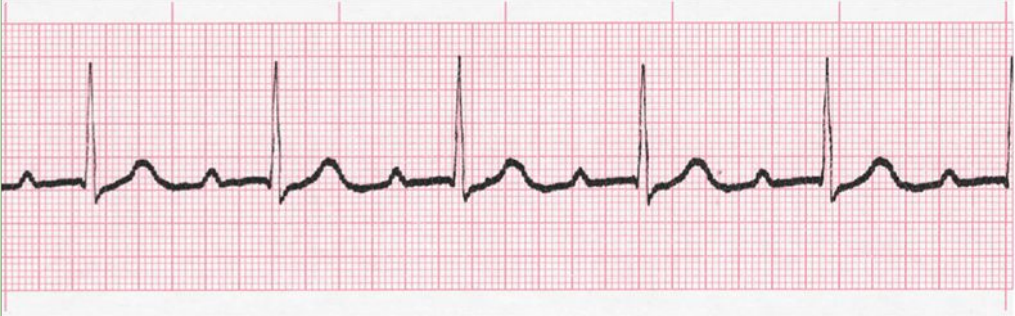

AV Blocks

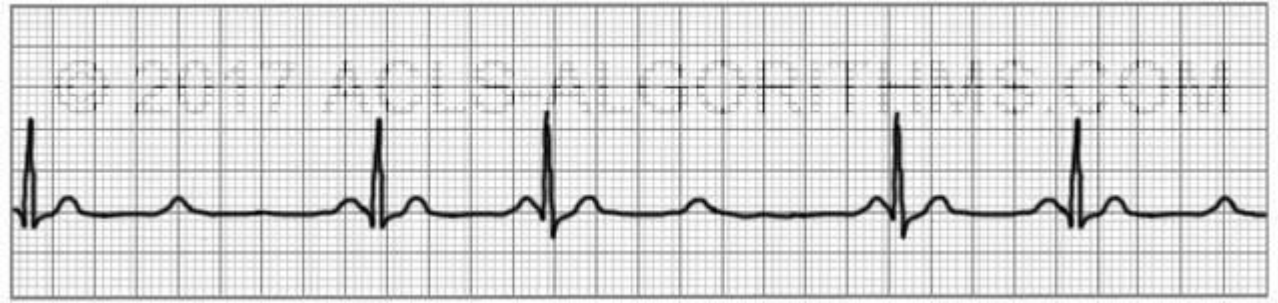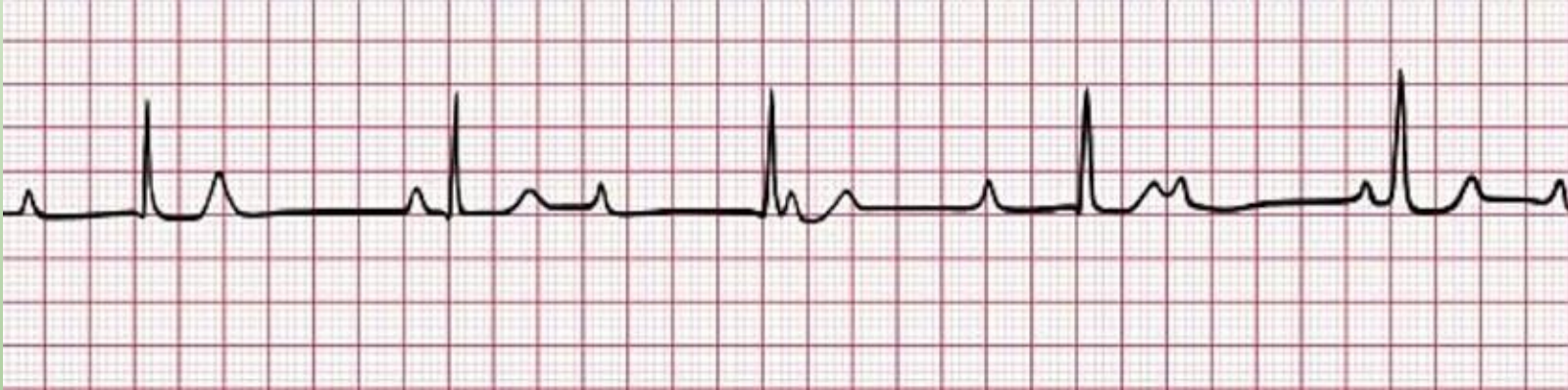
- Heart Block

- 1st Degree is no big deal, just a long PR interval
- 2nd Degree type 1-PR lengthens then drops
 - “Longer, longer, drop, then you have a Wenckebach.”
- 2nd Degree type 2-drops a beat without lengthening
 - “If some P’s don’t go through, then you have a Mobitz II.”
- 3rd Degree-no association with P and QRS
 - Highest yield associations are with 3HB
 - Lyme disease, baby from mother with Lupus
 - Just for kicks and giggles-PE finding of 3HB is cannon a-waves
 - No association between cardiac cycle so you are shooting blood against a closed valve at times

AV Blocks



AV Blocks



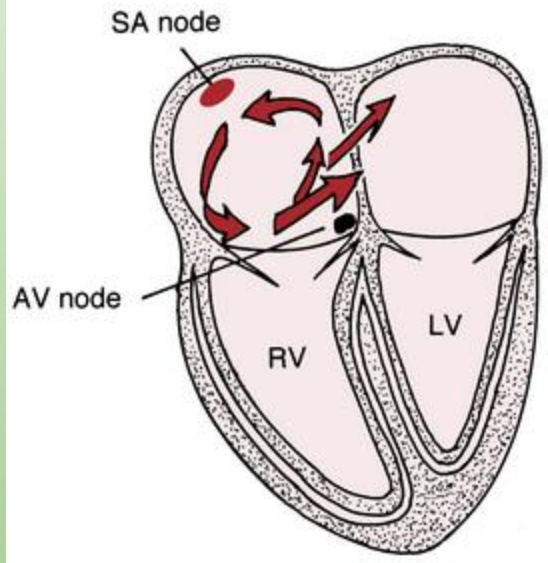
Atrial Fibrillation

- Irregularly irregular
 - No p waves
 - Irregular RR intervals
- Risk factors-at the basic level is from AE
- Conduction in the heart relies on gap junctions-when structural changes occur, messes with gap junctions and conduction problems can occur
 - AE from HTN or CAD
 - Risk for stroke
 - Thrombus formation in the LA appendage
 - Rate or rhythm control and anti-coagulation
 - Cardioversion-TEE to ensure no thrombus in LA appendage
- MCC of new onset Afib is hyperthyroidism-reflexively check TSH/T4

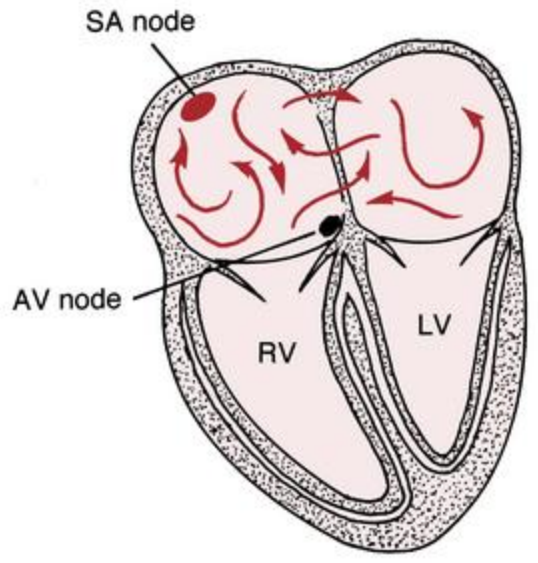
Atrial flutter

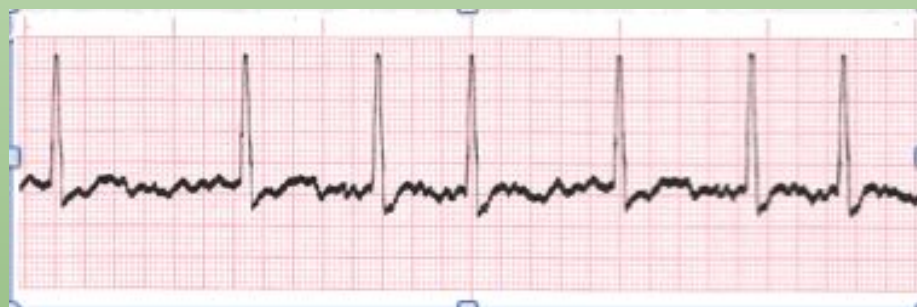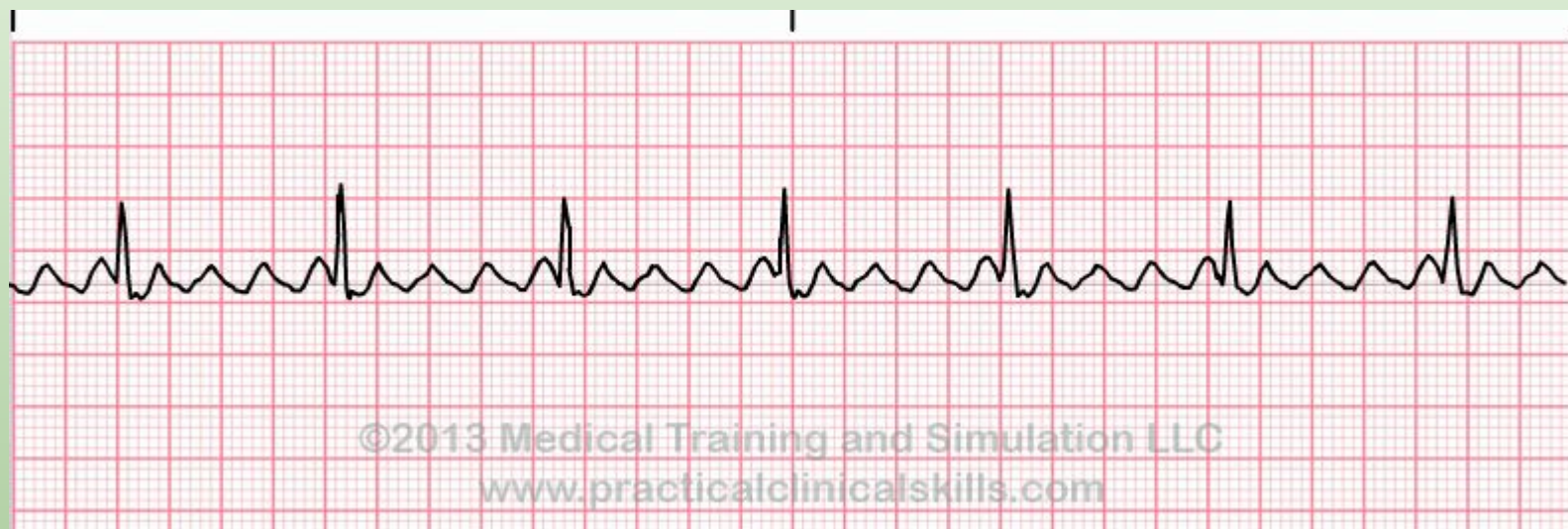- Consistent electrical circuit
- Sawtooth appearance
 - For kicks and giggles-direction of the sawtooth pattern dictates if it can be ablated (RA>LA, medical management of LA ectopic circuit)
- Consistent RR interval
- Treat with OAC, rate or rhythm control

ATRIAL FLUTTER



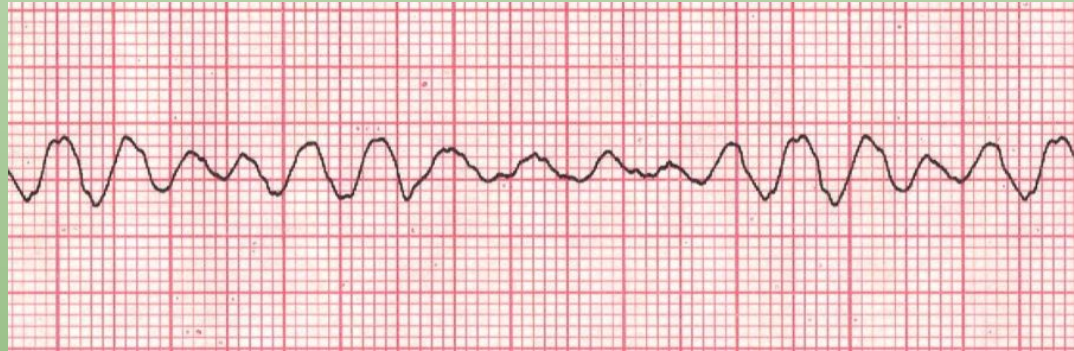ATRIAL FIBRILLATION





Ventricular fibrillation

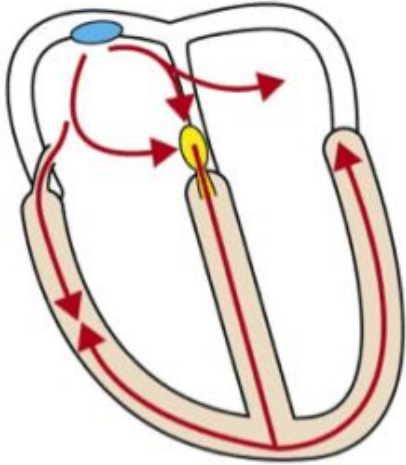
- Not using the right conduction pathway
- Wide QRS
- CPR and defibrillation



WPW

- Short PR and prolonged QRS
- Accessory pathway in Bundle of Kent
- Treat with procainamide (IA antiarrhythmic)
 - Possible drug side effect-lupus

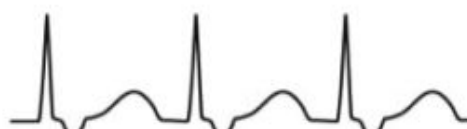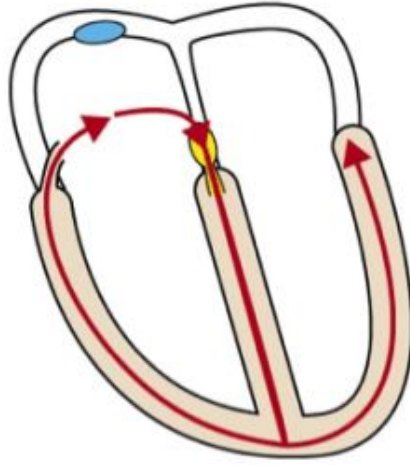
Pre-excitation



- Short PR interval
- In this case the PR segment cannot be seen.

Orthodromic AVRT

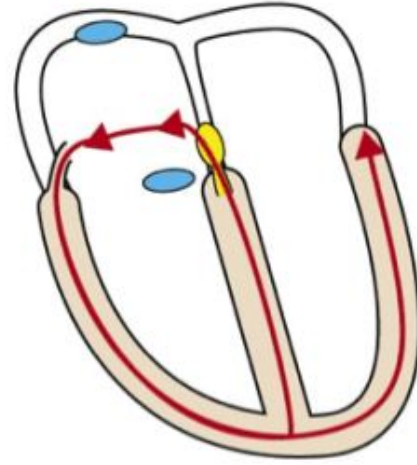
Antegrade conduction through atrioventricular node



- Normal QRS duration
- No delta wave
- Retrograde P-wave after QRS

Antidromic AVRT

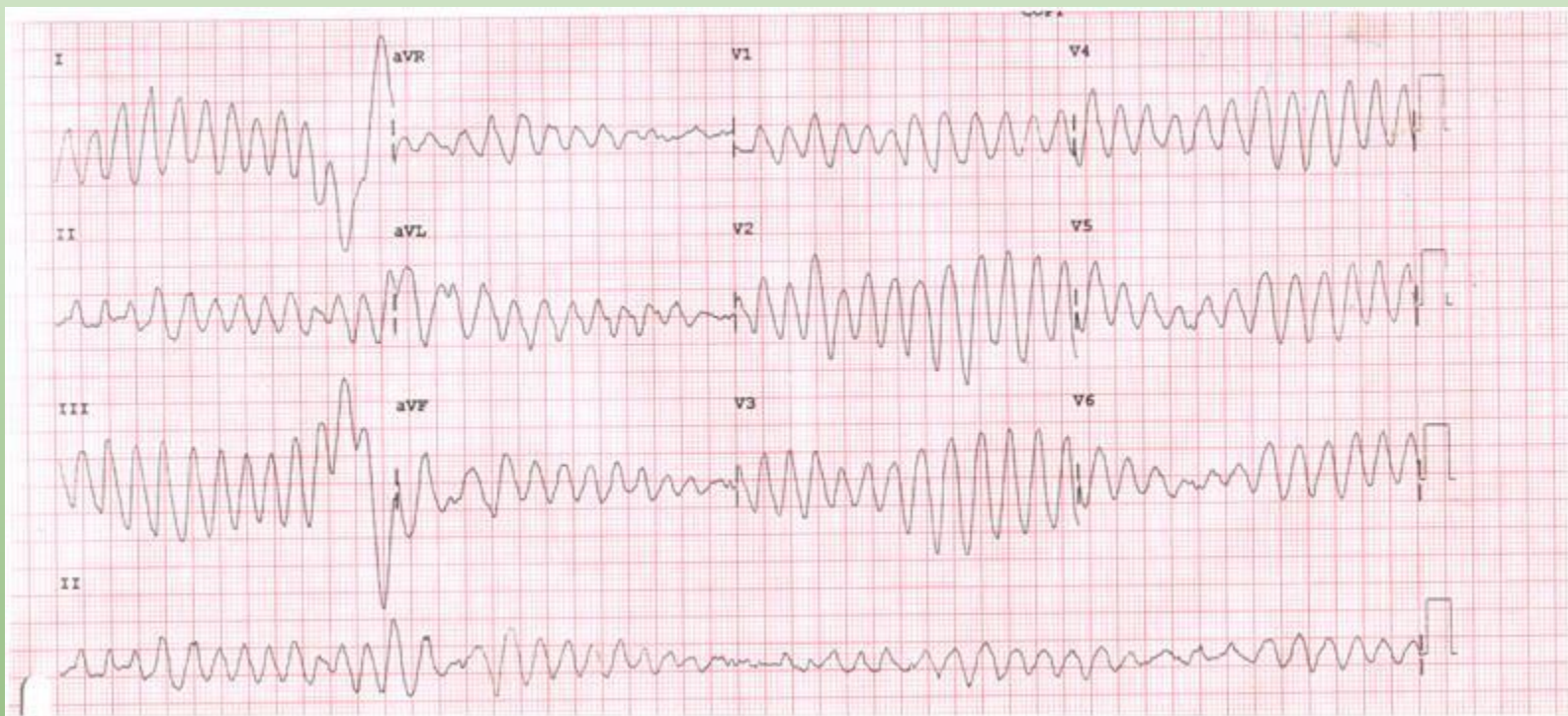
Retrograde conduction through atrioventricular node



- Wide QRS complex with delta wave
- P-wave rarely seen
- If P-wave visible, it is retrograde and occurs just before the QRS

Torsades

- Form of VTach that can quickly deteriorate into VFib
- Treatment-magnesium sulfate
- Can be caused by lots of drugs
 - Ondansetron
 - TCA-give sodium bicarb in TCA poisoning
 - Anti-arrhythmics
 - Antipsychotics
 - Antibiotics-macrolides, FQN



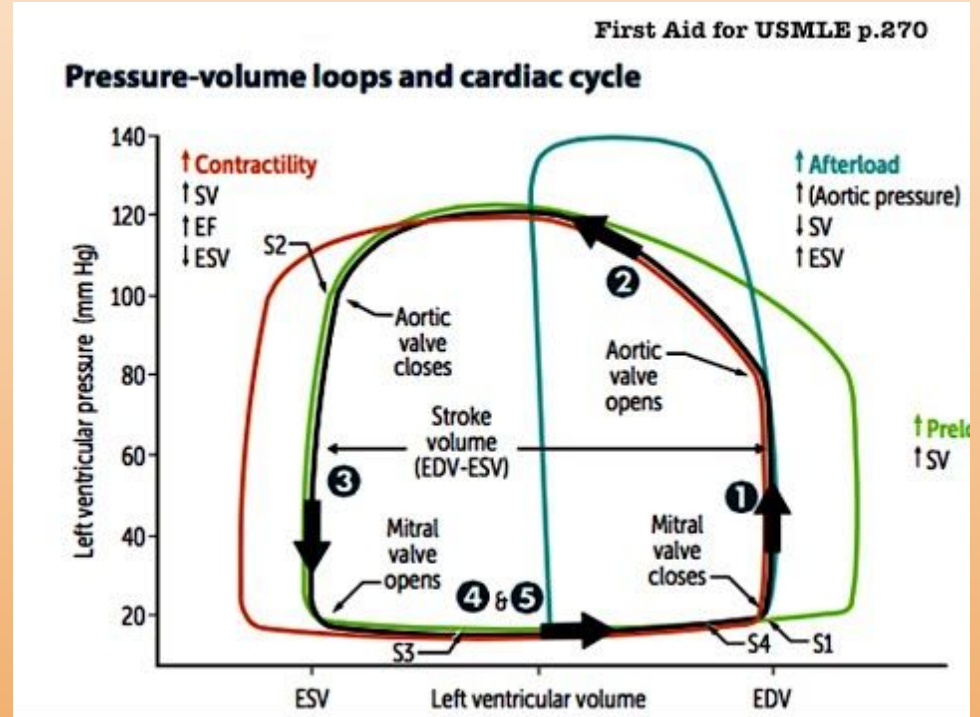
Pressure Volume Loops

$$CO = HR \times SV$$

SV affected by contractility, afterload, and preload

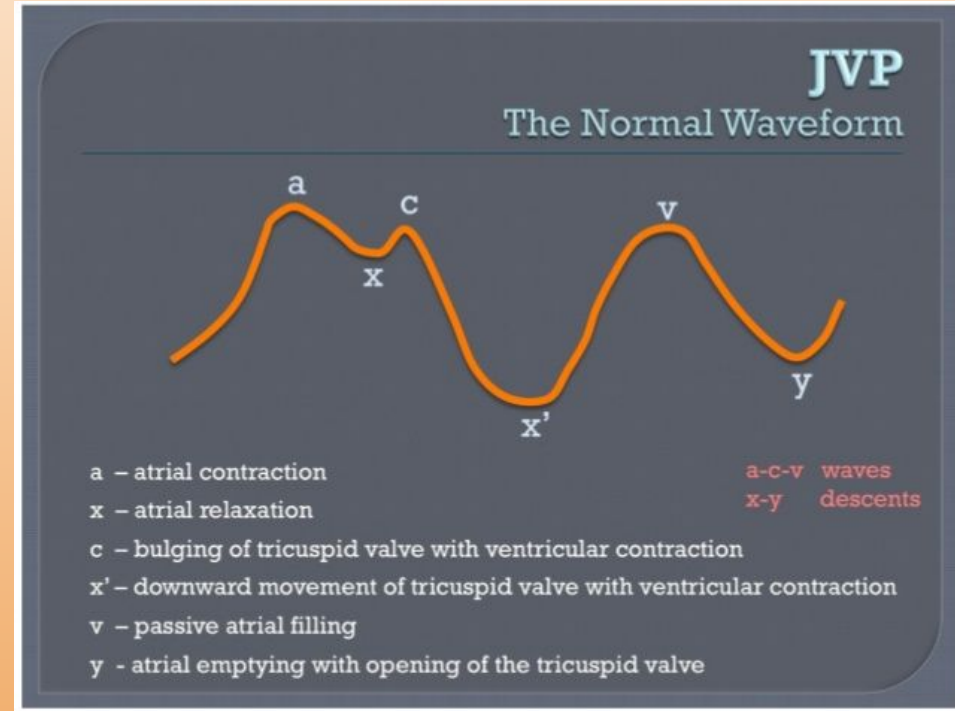
Important to understand components of cardiac cycle on this loop

1. Volume remains the same (isovolumetric contraction, pressure increases, systole)
2. Volume is now decreasing because aortic valve is open.
3. Aortic valve closes, volume remains the same because nothing can get out (isovolumetric relaxation)
4. Rapid filling into a now open ventricle



JVP Waves

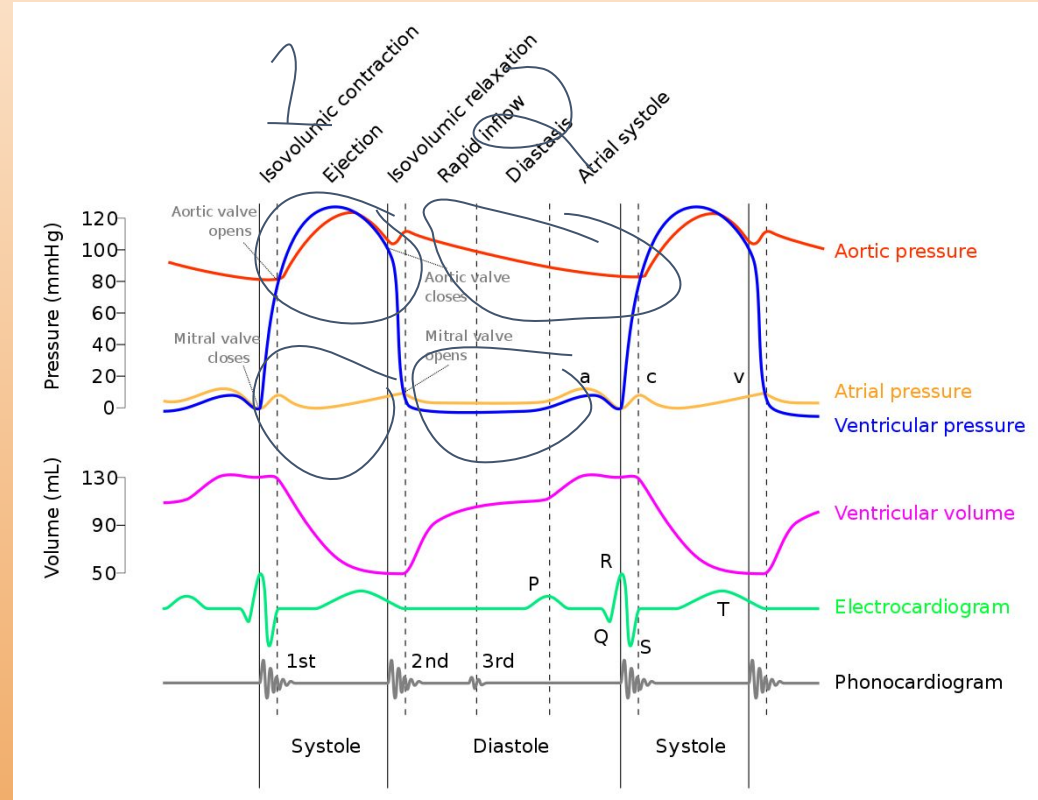
- JVP can tell you about R side of the heart
- If X is less prominent, that means too much blood is going back into the atrium (tricuspid regurgitation)
- Two normal descents-x and y
 - X is usually the dominant descent because it is occurring during contraction
 - Y is from passive early diastolic filling
 - Inflamed pericardium in pericarditis causes negative pressure making it easier to fill-prominent y
 - Tamponade causes fluid around heart that makes it difficult to fill-absent y



Wigger's Diagrams

Normal

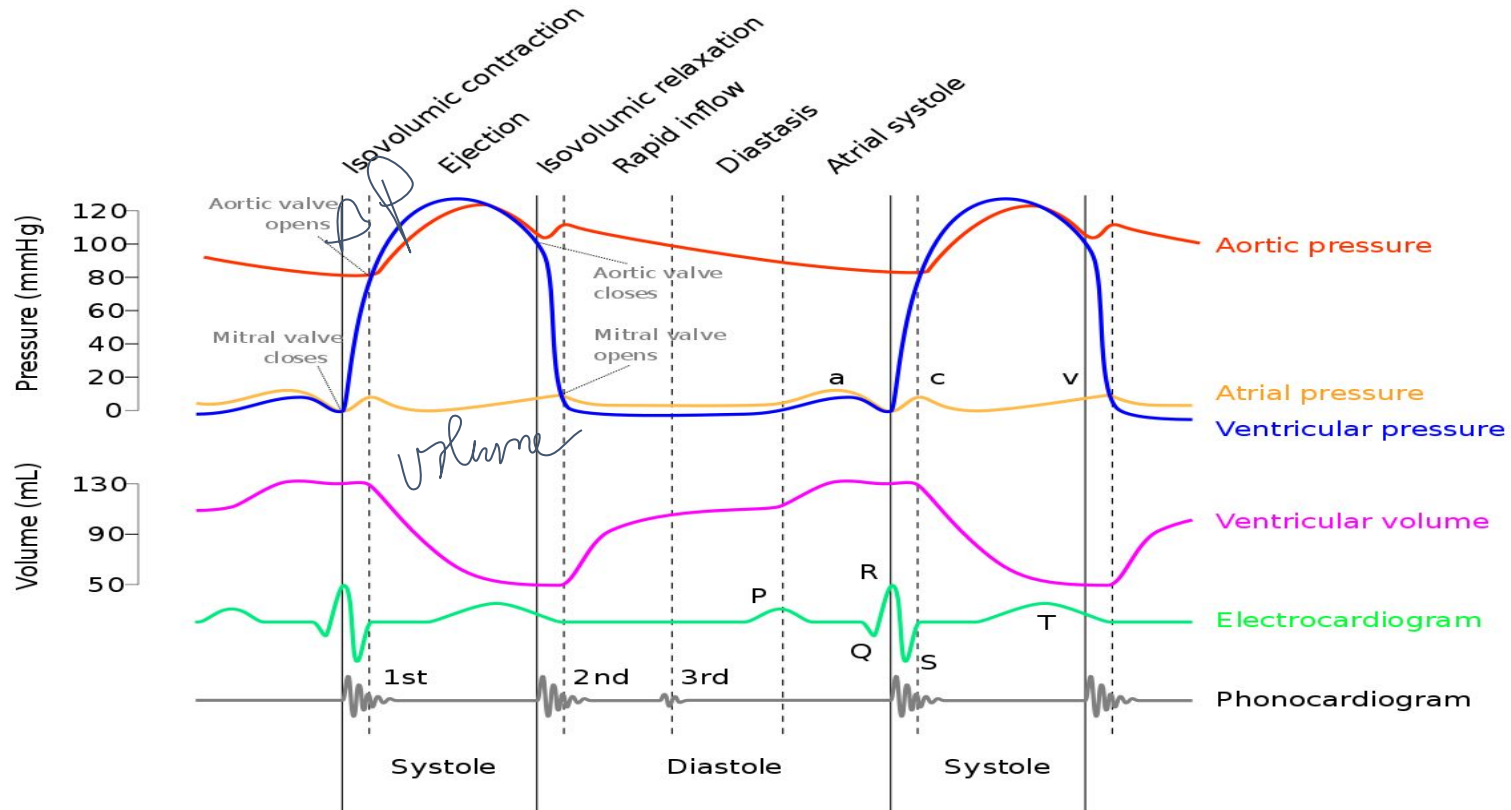
- Ventricular pressure is the portion that moves the most
- Opening of valves depends on pressure changes



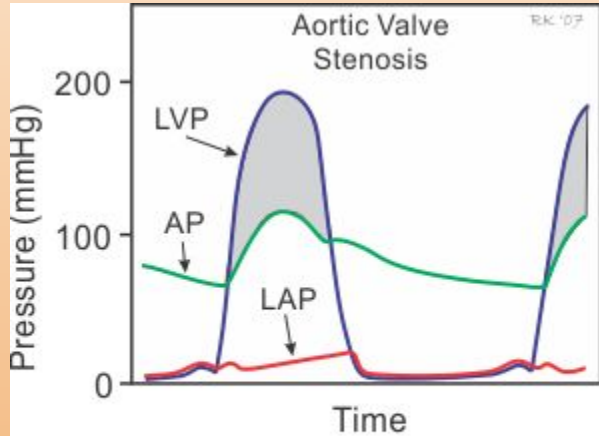
Systole (1 on the diagram)

- Think of these graphs in two ways
 - Pressure differences that are too great
 - Occurs with stenotic valves
 - Filling too quickly
 - Occurs with regurgitation
- In systolic portion-pressure from AS/PS, filling from MR/TR

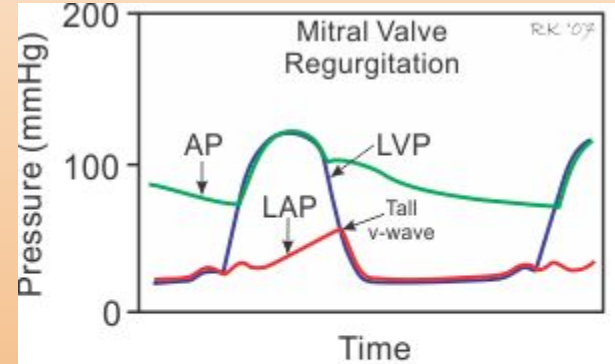
Systole (1 on the diagram)



Systole

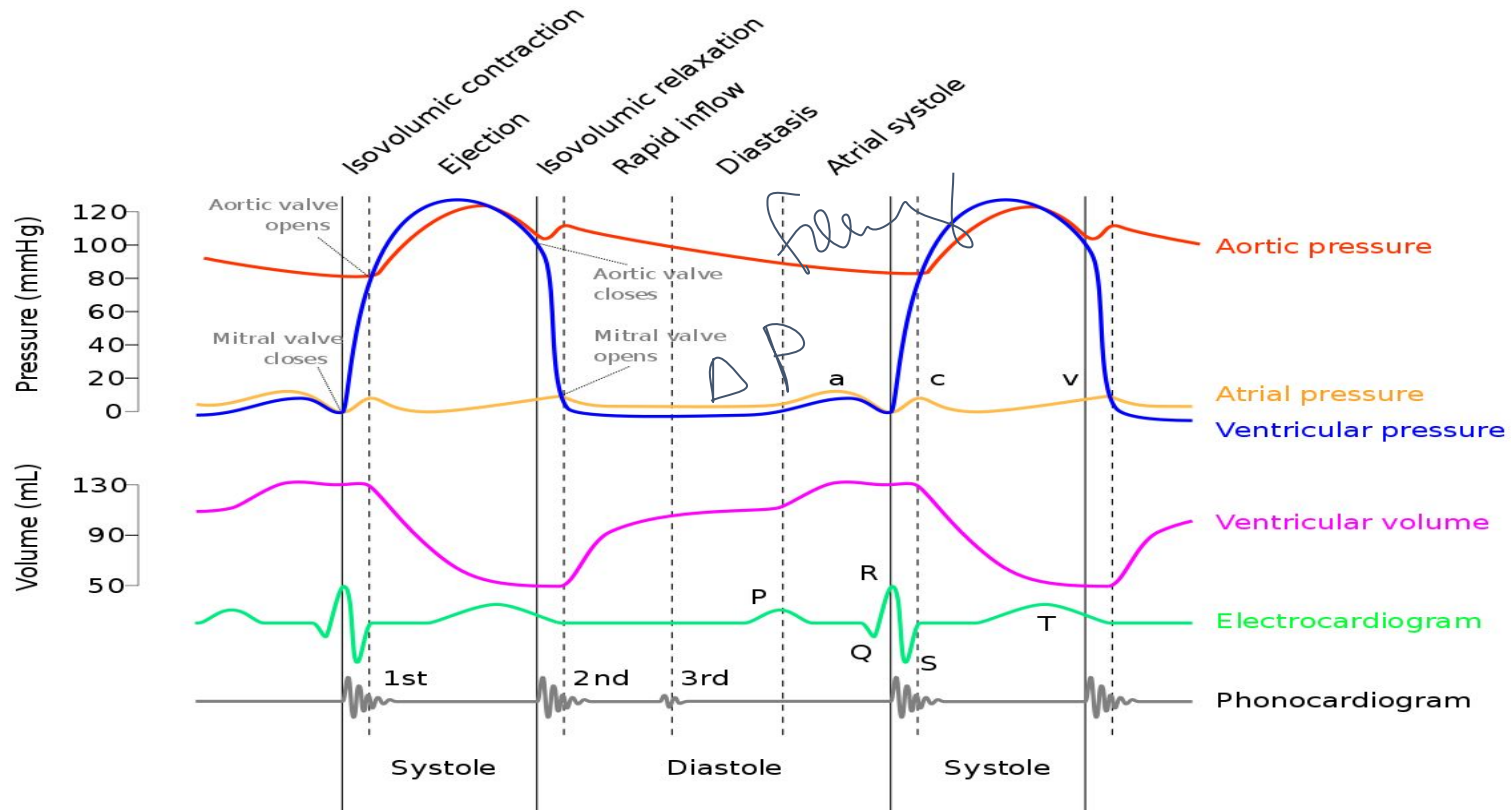


During ventricular ejection, LVP exceeds AP (gray area, pressure gradient generated by stenosis).
Abbreviations: LAP, left atrial pressure; LVP, left ventricular pressure; AP, aortic pressure.

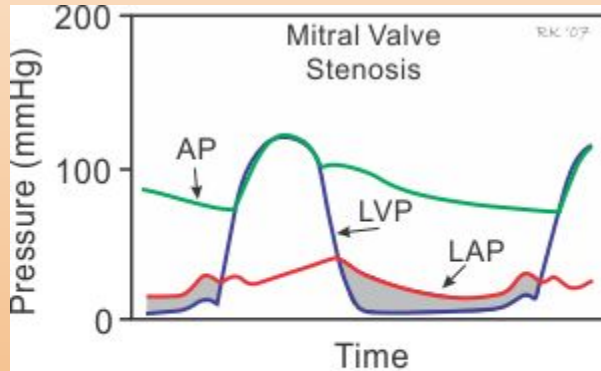


During ventricular contraction (systole), the left ventricle ejects blood back into the left atrium as well as into the aorta, thereby increasing LAP, particularly the v-wave. *Abbreviations:* LAP, left atrial pressure; LVP, left ventricular pressure; AP, aortic pressure.

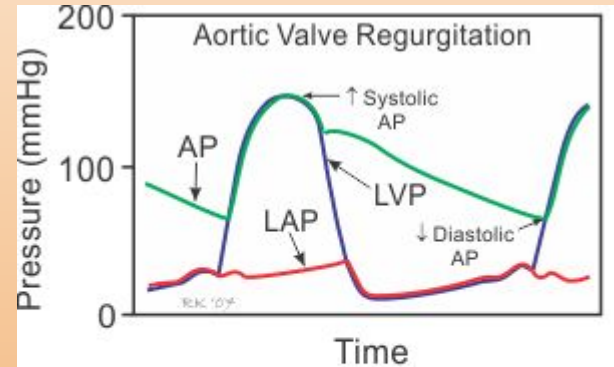
Diastole (2 on the diagram)



Diastole



During ventricular filling (diastole), LAP exceeds LVP (gray area, pressure gradient generated by stenosis). *Abbreviations:* LAP, left atrial pressure; LVP, left ventricular pressure; AP, aortic pressure.



During ventricular relaxation, blood flows backwards from aorta into the ventricle. Aortic systolic pressure increases, aortic diastolic pressure decreases, and pulse pressure increases; LAP increase. *Abbreviations:* LAP, left atrial pressure; LVP, left ventricular pressure; AP, aortic pressure.

Summary

- Pressure differences greater than expected from stenotic valves
 - Systolic-AS
 - Diastolic-MS
- Filling too quickly from regurgitation
 - Systolic-MR
 - Diastolic-AR

Murmurs

- If it is a text question-go to the description of the murmur and start eliminating (Megri's Method)
 - Systolic
 - ASS (Aortic stenosis, pulmonic stenosis, tricuspid regurg, mitral regurg)
 - Diastolic
 - Aortic regurg, pulmonic regurg, tricuspid stenosis, mitral stenosis
 - Holosystolic
 - VSD, tricuspid and mitral regurg
- If you get in trouble-try to think about the murmur relative to the cardiac cycle
 - Murmurs-think of as feed forward issues or backflow issues
 - Feed forward-from valves that should be open but are not good at opening because they are stenosed
 - Backflow-valves that should be closed that are allowing backflow
 - Systole-open A/P, closed M/T
 - Diastole-open M/T, closed A/P

Murmurs

- Best initial test?
- What kind of murmurs are we concerned about?
- Echo
- Grade III or more, diastolic, pansystolic, radiating, or symptomatic

Aortic stenosis

- Pathophysiology of AS
- Presentation
- Murmur
- Senile calcifications (MC>70), bicuspid aortic valve (association with Turner's), late manifestation rheumatic heart
- Syncope, CHF, angina
- Systolic murmur, radiates to carotids

MVP

- Murmur?
 - Pathology?
 - Treatment?
 - Repercussions?
- Late systolic with click
 - Myxomatous degeneration
 - Treatment only indicated if symptomatic with heart palpitations, treat with BB
 - Predisposes to IE (Strep Viridans-only damaged valves)

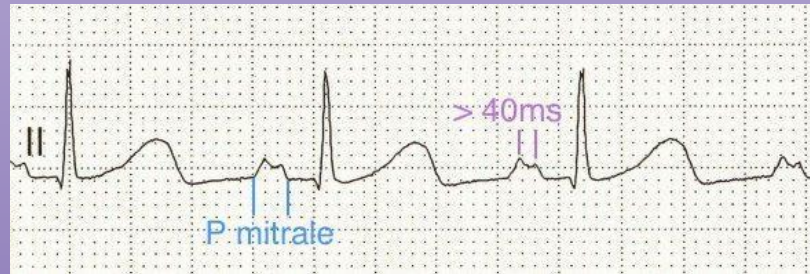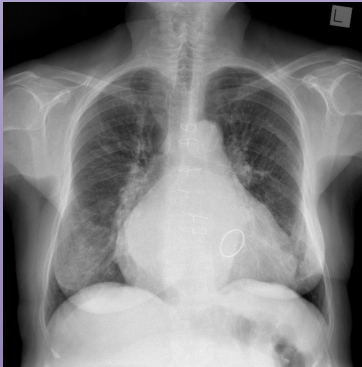Aortic regurgitation/dissection

- Widened pulse pressure and diastolic murmur?
- Patient experience of AR?
- Associations?
- Pain radiating to the back, pressure >20 between arms, new onset aortic regurgitation?
- Most specific and sensitive?
- Aortic Regurgitation
- Aware of heart beat due to LV enlargement
- Connective tissue diseases, syphilis, ankylosing spondylitis
- Aortic dissection
- TEE

Mitral regurgitation

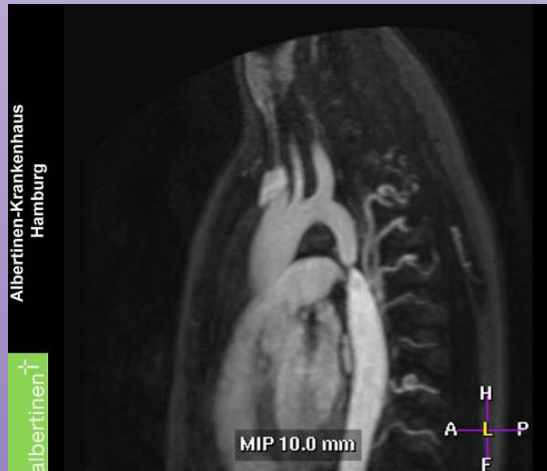
- Murmur and radiation
- Cause?
- In setting of IE or MI?
- P wave abnormalities in EKG?
- Manifestations of LAE?

- Holosystolic, radiation to axilla
- Can be manifestation of RF, MVP is the most common cause of MR in developed countries
- Chordae in IE, papillary muscle rupture
- Looks like m
- Predisposes to A. Fib, splays carina on XR, can cause hoarseness and dysphagia

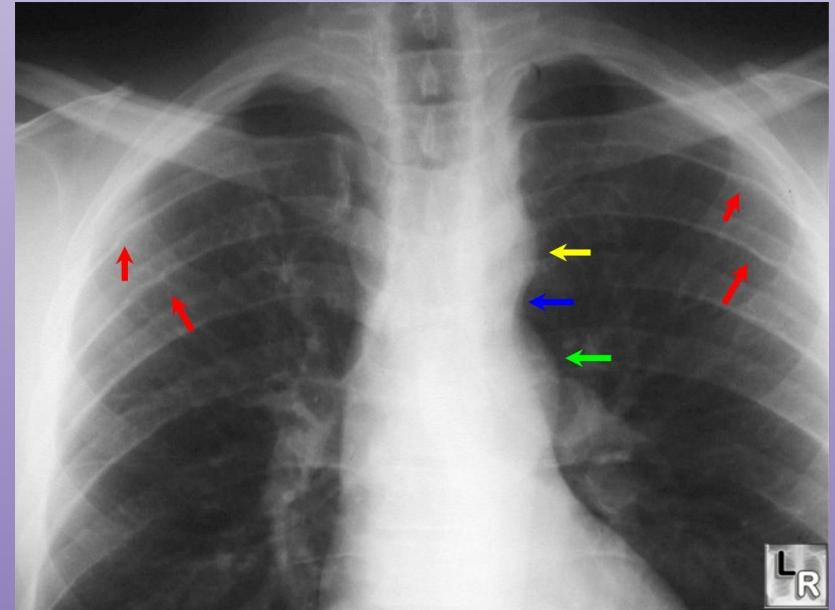


Coarctation of the aorta

- Underdeveloped lower extremity with brachial-femoral pulse delay
 - EKG?
 - CXR?
 - High yield association-genetics?

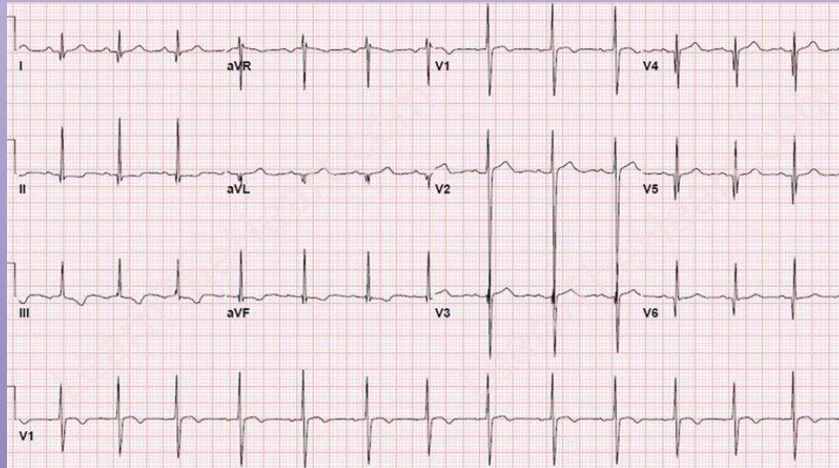


- Coarctation of the aorta
 - LVH
 - 3 sign with rib notching
 - Turner syndrome



HOCM

- Dysfunction in HOCM?
- Physiology?
- Murmur?
- EKG?
- Treatment?



- Diastolic then systolic due to fibrous replacement of sarcomeres
- Asymmetric septal hypertrophy & systolic anterior motion of mitral valve → aortic outflow obstruction → dyspnea & possible syncope
 - During exercise, could lead to sudden death
- Mitral regurg
- Septal Q waves
- CCB or BB

Teenager/young adult who's an athlete.

AD → (+) family hx of someone dying suddenly at a young age.

Maneuvers on Murmurs

	Venous Return / Preload		Afterload		Drugs	
	Increase	Decrease	Increase	Decrease	Diuretic	ACEIs
	(Leg raise / Squat)	(Valsalva / Standing)	(Handgrip)	(Amyl Nitrate)		
MS, AS	↑	↓	↓(AS)	↑(AS)	Yes, but better	
			Negligible Effect in (MS)		AS (Replace)	×
MR, AR	↑	↓	↑	↓	✓	✓
VSD	↑	↓	↑	↓	✓	✓
HOCM	↓	↑	↓	↑	×	×
MVP	↓	↑	↓	↑	×	×

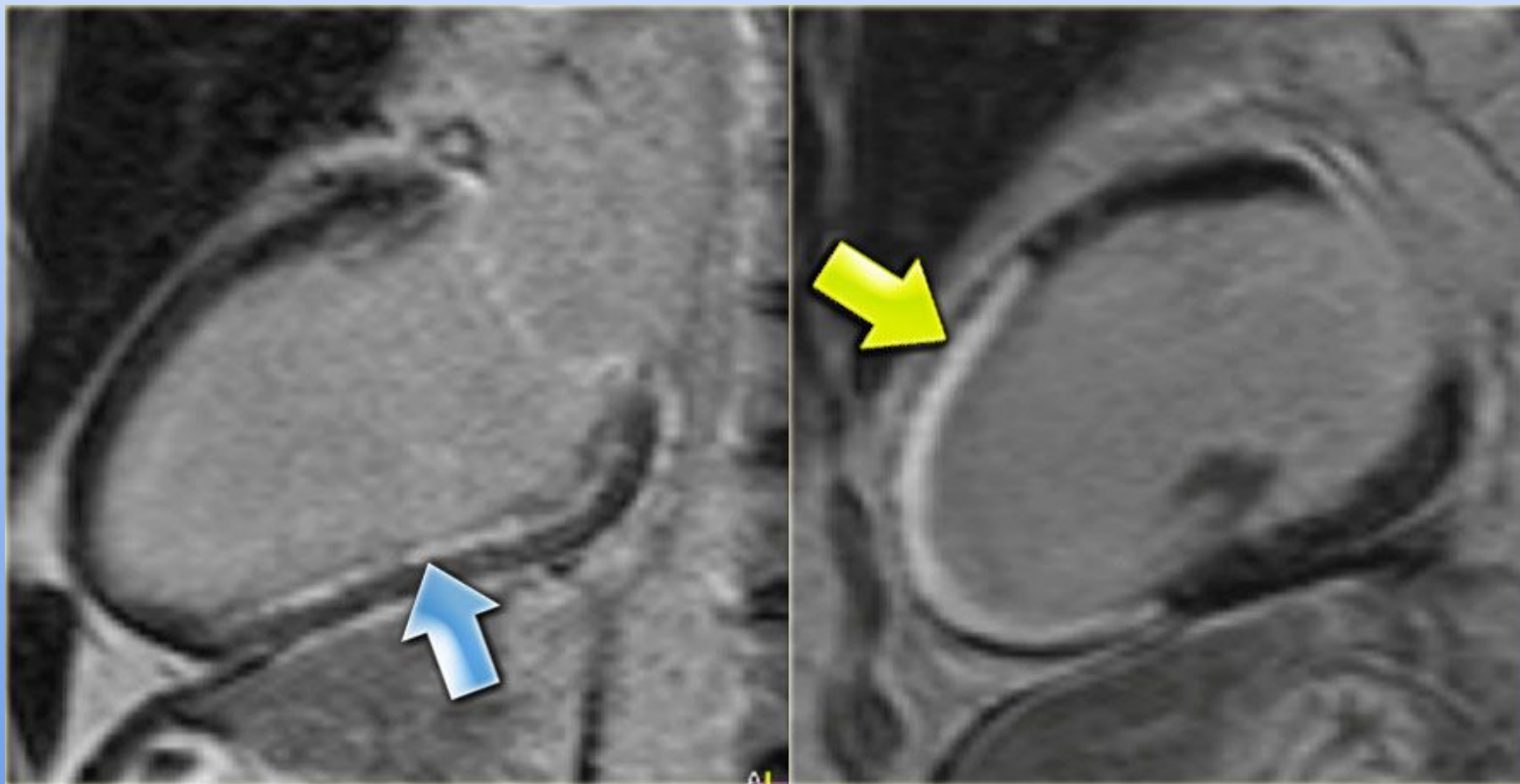
Murmur buzzwords

- Holosystolic(MR, VSD, TR)
- Early systolic (AS, PS, HOCOM)
- Mid systolic (MVP, ASD)
- Diastolic (MS, TS, AR, PR)
- Murmur with Click-MVP
- Radiates to the Axilla-MR
- Opening snap-MS
- Hyperdynamic circulation or signs-AR

Pathology-CAD

- Atherosclerosis of coronary arteries leading to variable levels of symptoms/interventions
 - Stable Angina-CP with exertion, not present at rest, no STE, no troponin leaks
 - Treat with nitroglycerin to vasodilate
 - Unstable Angina-CP without exertion, no STE, no troponins
 - NSTEMI-CP without exertion, no STE, troponins
 - Subendocardial
 - MONA BASH
 - Morphine, O2, Nitrates, ASA, BB, ACEi, Statin, Heparin
 - STEMI-CP without exertion, STE. troponins
 - Transmural
 - PCI (90 mins), Thrombolytics if in the middle of nowhere

Pathology-CAD



Pathology-CAD

Post-MI

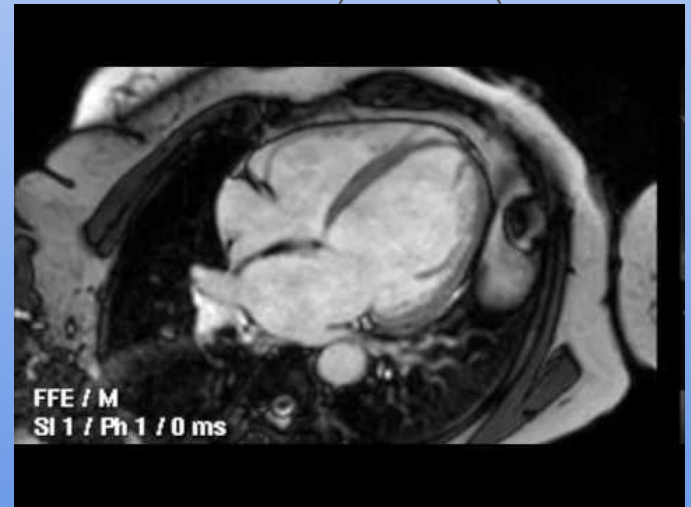
- Early-coagulative necrosis (1)
- Neutrophils come-inflammation (1-3)
- Macrophages come, start digesting and granulation tissue formation (3-14)
- Complete scar by 2 weeks

Post MI Complications

- RCA occlusion-leads
 - Initial treatment
 - Severe pulmonary edema and new holosystolic murmur 3-5 days post MI
- LAD occlusion-leads
 - New onset chest pain, shock, distant heart sounds
- LAD or RCA-new holosystolic murmur, step up in O2 level from RA to RV
- HR <60 post MI
- Re-infarction?
- Pleuritic CP weeks later?
- Persistent STE?
- II, III, aVF
 - Fluids-nitro will not help because the issue is preload
 - Papillary muscle rupture, leads to new MR murmur
- V1, V2, V3, V4
 - Free wall rupture, leads to a new tamponade presentation
- Interventricular septum rupture, leads to VSD murmur
- Bradycardia post MI
- Myoglobin
- Dressler-give NSAIDS
- Aneurysm

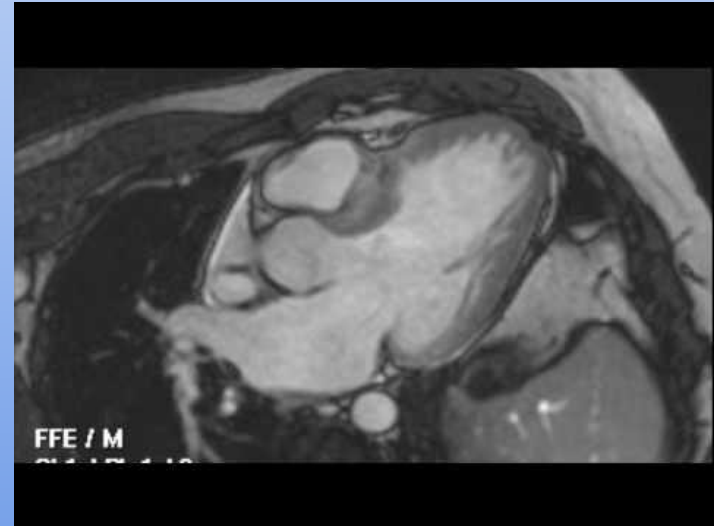
Pathology-Cardiomyopathies

- Dilated Cardiomyopathies
 - Too big, cannot squeeze efficiently, volume overload with S3
 - Alcohol, Wet Beriberi, Chagas, Coxsackie, Doxorubicin, PPCM, Hemochromatosis, Sarcoidosis
 - Eccentric hypertrophy
 - Treat with volume restriction (decrease volume in heart with diuretics) and BB (decrease HR)



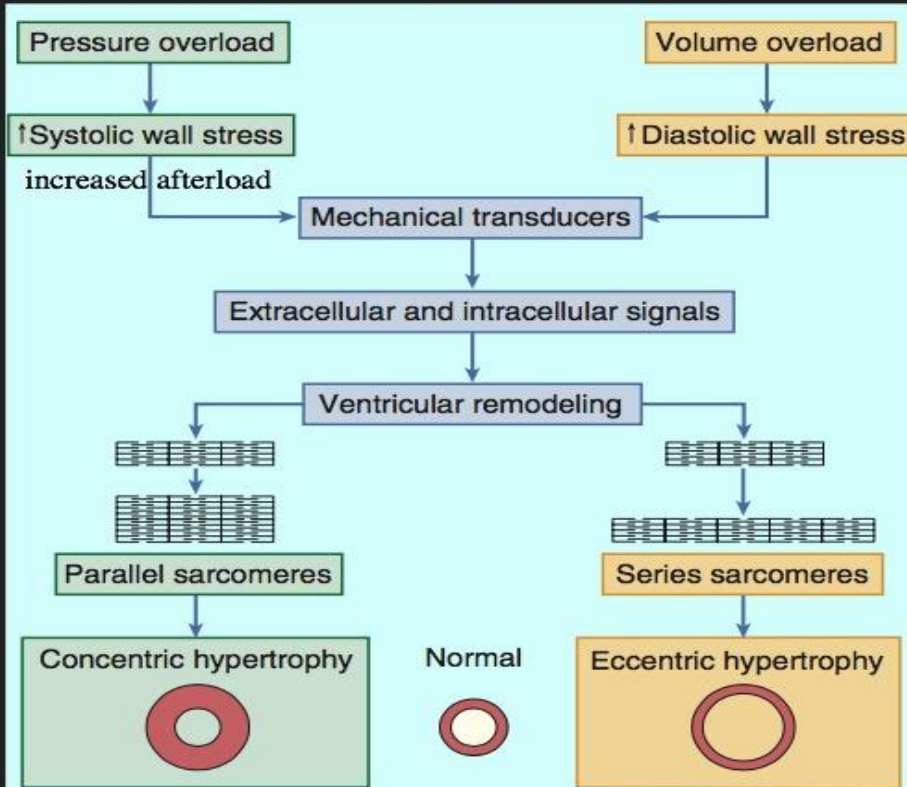
Pathology-Cardiomyopathies

- Hypertrophic Cardiomyopathy
 - MC AD sarcomere dysfunction causing thick ventricles
 - Stiff-S4
 - Too thick that it cannot relax-diastolic dysfunction
 - Concentric hypertrophy
- HOCM
 - Outflow obstruction from movement of mitral valve
 - Systolic murmur that increases with valsalva
 - Decreases with squat (decreased obstruction)
 - Treated with myomectomy or EtOH ablation



LEFT VENTRICULAR REMODELING!!!

LV REMODELING IS INFLUENCED BY HEMODYNAMIC, NEUROHORMONAL, EPIGENETIC, AND GENETIC FACTORS



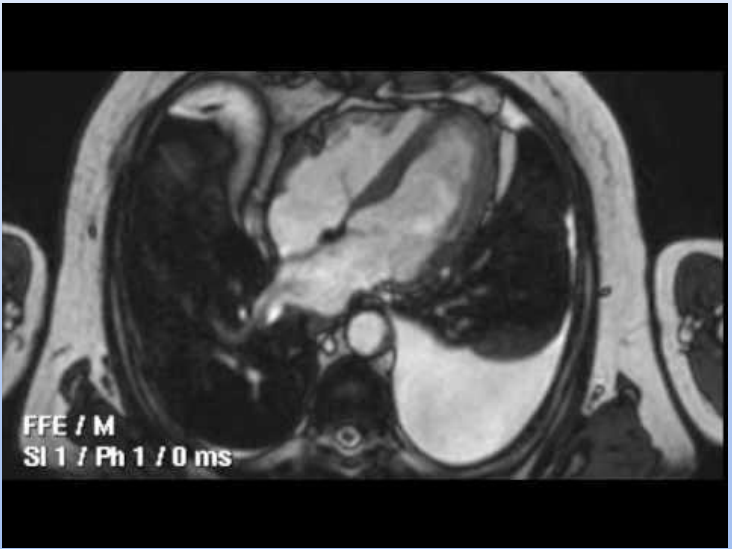
Cardiac hypertrophy is seen in all patients with HF:

1. Systolic failure usually presents with eccentric hypertrophy
2. Diastolic failure tends to have concentric hypertrophy, with or without LV dilation

Pathology-Cardiomyopathies

- Restrictive cardiomyopathy
 - Infiltrative process that results in difficulty relaxing during diastole
 - Radiation, Loeffler (post MI), Amyloidosis, Sarcoidosis, Hemochromatosis
 - Low voltage EKG

		Constrictive pericarditis	Restrictive cardiomyopathy
Patient history		Cardiac procedures	Genetic disease
		Radiation	Radiation
		Connective tissue disease	Connective tissue disease
		Infection (TB)	Infection (eosinophilic disease) Amyloidosis
Jugular venous pressure (JVP)		↑y ↑x	↑y ↓x
		Kussmaul's sign	Kussmaul's sign
Lab/ECG/X-ray		Nonspecific	Nonspecific
Advanced cardiac imaging	Echocardiogram Cardiac MRI Cardiac CT	↑ Pericardial thickness	↑ Wall thickness
		Pericardial calcification	Biatrial enlargement
		Pericardial effusion	Systolic and diastolic dysfunction
		↑ Imaging correlates of ventricular interdependence	Pulmonary hypertension
		Pericardial inflammation	Tissue characterization abnormalities
Invasive hemodynamics		Discordant respirophasic ventricular pressure changes	Concordant respirophasic ventricular pressure changes



S3 & S4 (“Gallops”)

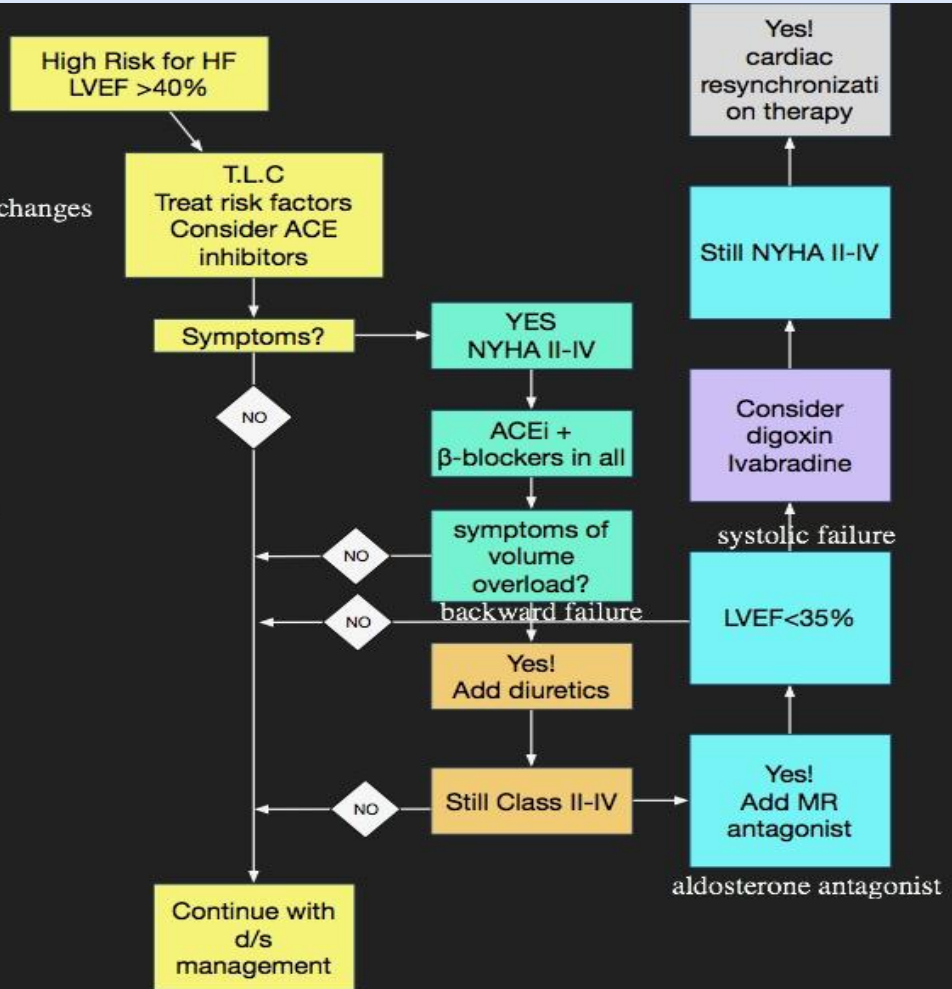
- S3
 - Occurs in early diastole (passive LV filling)
 - From Sketchy Path: “**Slushing in**”
 - Can be a normal finding in children
 - Systolic dysfunction
 - Dilated cardiomyopathy
- S4
 - Occurs in late diastole (active LV filling)
 - From Sketchy Path: “**A stiff wall**”
 - ALWAYS abnormal
 - Diastolic dysfunction
 - HOCM
 - Restrictive cardiomyopathy

Pathology-Heart Failure

- Can be categorized into RHF or LHF based mostly on symptoms
 - RHF causes congestion in systemic circulation (JVD, edema, hepatic congestion and hepatomegaly)
 - LHF causes lung congestion (rales, orthopnea, PND)
- Can be categorized into systolic or diastolic dysfunction
 - HFrEF (reduced EF from systolic dysfunction)-dilated CM or ischemic
 - HFpEF (preserved EF from diastolic dysfunction)-hypertrophic CM
- Medications that decrease mortality
 - Spironolactone
 - BB (carvedilol, bisoprolol, metoprolol)
 - ACEi/entresto
- Acute exacerbation-Lasix (furosemide), Morphine, Nitrates, O2, Position

WHAT IS THE COMPOSITE TREATMENT PLAN FOR HF_{REF}?

TLC = therapeutic lifestyle changes



Congestion at rest?
(orthopnea, rales, S3)

NO

YES

Low perfusion at rest?
(narrow PP, hypotension, cool
extremities)

NO

**Warm
and dry**

**Warm
and Wet**

BF

YES

**Cool and
Dry**

**Cool and
Wet**

FF

BF + FF

Treatment of ADHF

Congestion at Rest?

No

Yes

Warm and Dry
PCW normal
CI normal
(compensated)

Warm and Wet
PCW elevated
CI normal

Cold and Dry
PCW low/normal
CI decreased

Cold and Wet
PCW elevated
CI decreased

Normal SVR

High SVR

IV diuretics
Nesiritide
or

Vasodilators
Nitroprusside
Nitroglycerin

Inotropic Drugs
Dobutamine
Milrinone

**Low
Perfusion
at Rest?**

No

Yes

Nohria et al. Medical Management of Advanced Heart Failure. JAMA. 2002; 287:628-640

Stevenson LW. Eur J Heart Failure 1999;1:251-257

Pathology-Shock

- Poor perfusion
- Hypovolemic (decreased CO, increased afterload, decreased preload)
- Cardiogenic (decreased or increased preload, decreased CO, increased afterload)
- Distributive (warm, decreased preload, decreased CO, decreased afterload)

To Summarize

Type of Shock	Insult	Physiologic Effect	Compensation
Cardiogenic	Heart fails to pump blood out	↓CO	BaroRc ↑SVR
Obstructive	Heart pumps well, but the outflow is obstructed	↓CO	BaroRc ↑SVR
Hemorrhagic	Heart pumps well, but not enough blood volume to pump	↓CO	BaroRc ↑SVR
Distributive	Heart pumps well, but there is peripheral vasodilation	↓SVR	↑CO

Pathology-Endocarditis

- Fever, murmur, Roth (white in eye), Osler (painful on hands and feet), emboli, splinter hemorrhages
- Acute-Staph aureus (Tricuspid)
- Subacute-Viridans, HACEK tend to be culture negative

Pathology-Pericarditis

- Sharp pleuritic pain, relieved by leaning forward
 - Diffuse ST-segment elevation, friction rub
 - MC-post viral (coxsackie B) (others-SLE, radiation, uremia)
-
- Pericardium innervated by phrenic nerve → can have referred pain to shoulder

Pathology-Cardiac Tamponade

- Fluid in pericardium compressing, equalizing pressures
- Low voltage, electrical alternans
- Pulsus paradoxus-decrease >10 with inspiration
- Hypotension, JVD, distant heart sounds (Beck's Triad)

Pathology-Aorta

- Aortic aneurysm-thoracic (cystic medial degeneration), Marfans, HTN, bicuspid aortic valve (Turners)
 - Can lead to root dilation and AR
- Aortic aneurysm-abdominal (atherosclerosis)
 - Palpable pulsatile abdominal mass (infrarenal)
- Aortic dissection-Marfans, HTN, BAV
 - Back pain, unequal BP, mediastinal widening
 - A can go back-SURGERY
 - B treat with BB

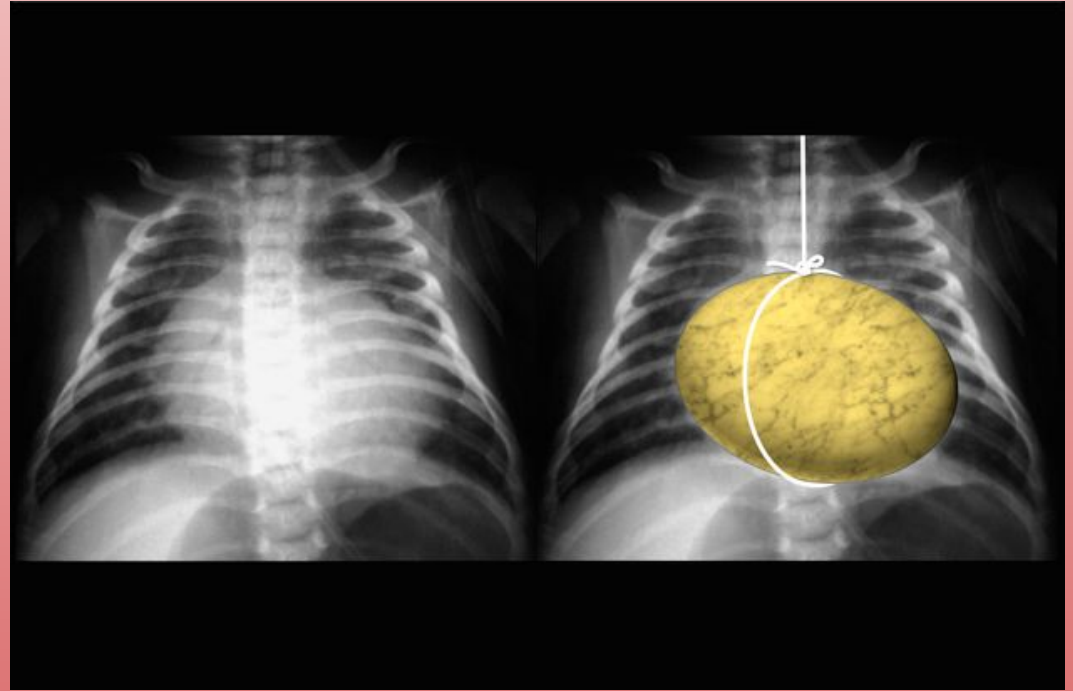
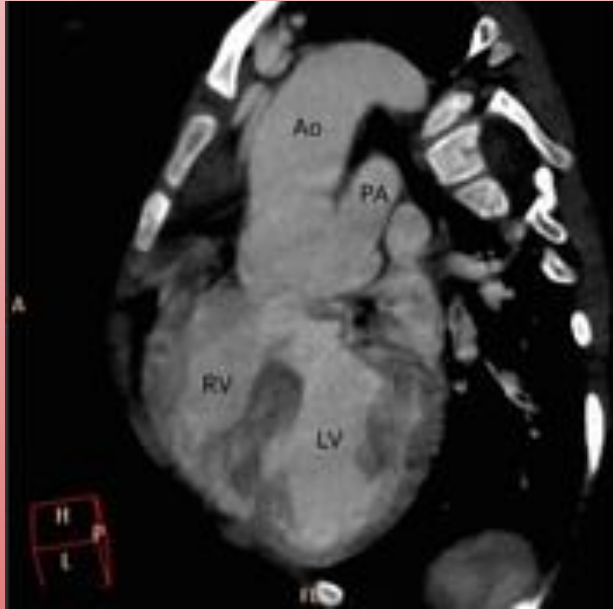
CHD-Cyanotic Lesions (EaRLy)

- Some of them are ductus dependent-ductus arteriosus helps mix the blood; ASD and VSD are helpful too
 - Truncus Arteriosus
 - Septation fails to occur (failure of neural crest cell migration)
 - 22q11 (DiGeorge)
 - Transposition of the Great Vessels
 - Failure of the AP septum to spiral
 - Aorta-anterior, Pulmonary arteries-posterior
 - Requires shunt for mixing-life
 - Diabetic mothers
 - Tricuspid Atresia
 - Hypoplastic RV/tricuspid
 - Only congenital heart disease that has left axis deviation (LAD)
 - ASD and VSD
 - Tetralogy of Fallot (“PROVe”) (boot-shaped heart) (22q11-DiGeorge)(tet spells)
 - Pulmonary stenosis
 - RVH
 - Overriding aorta
 - VSD
 - Total Anomalous Pulmonary Vascular Return
 - Pulmonary veins to RA

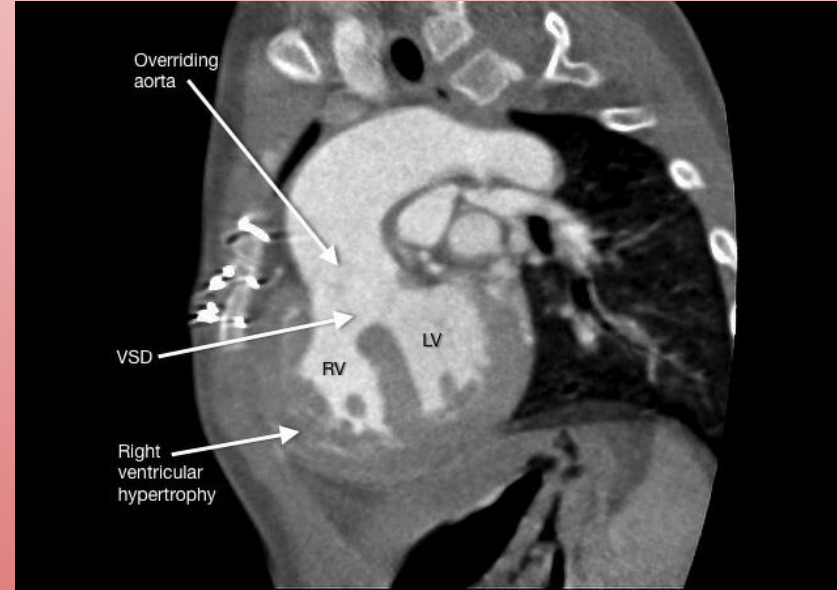
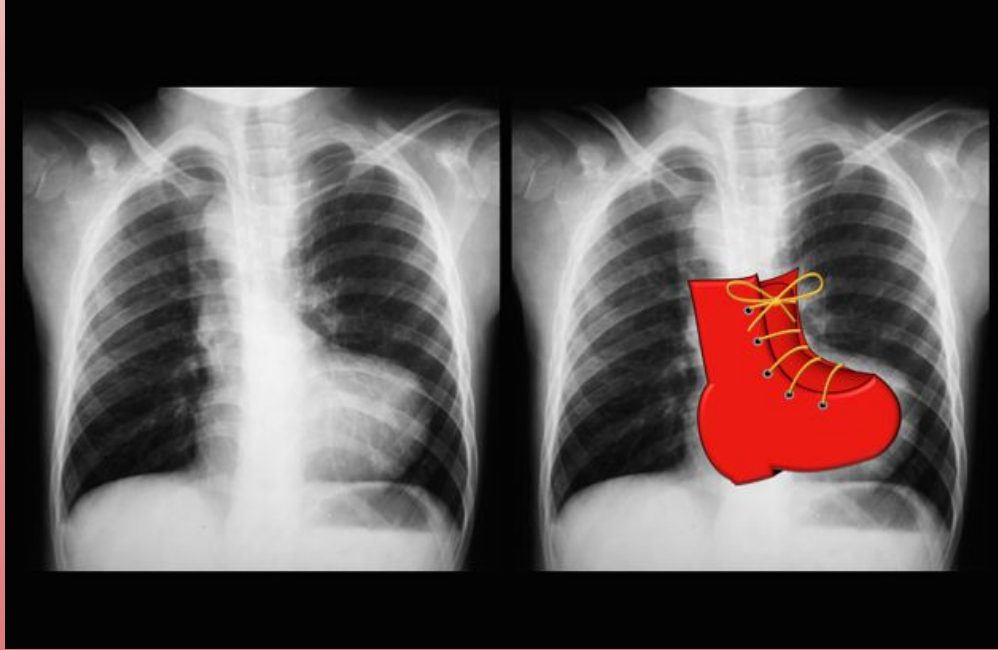
CHD-Cyanotic Lesions (EaRLy)

- Ebstein's Anomaly
 - Displacement of tricuspid valve leaflets into RV → atrializes RV
 - Murmur: tricuspid regurg
 - Lithium exposure in utero (mother with bipolar disorder)


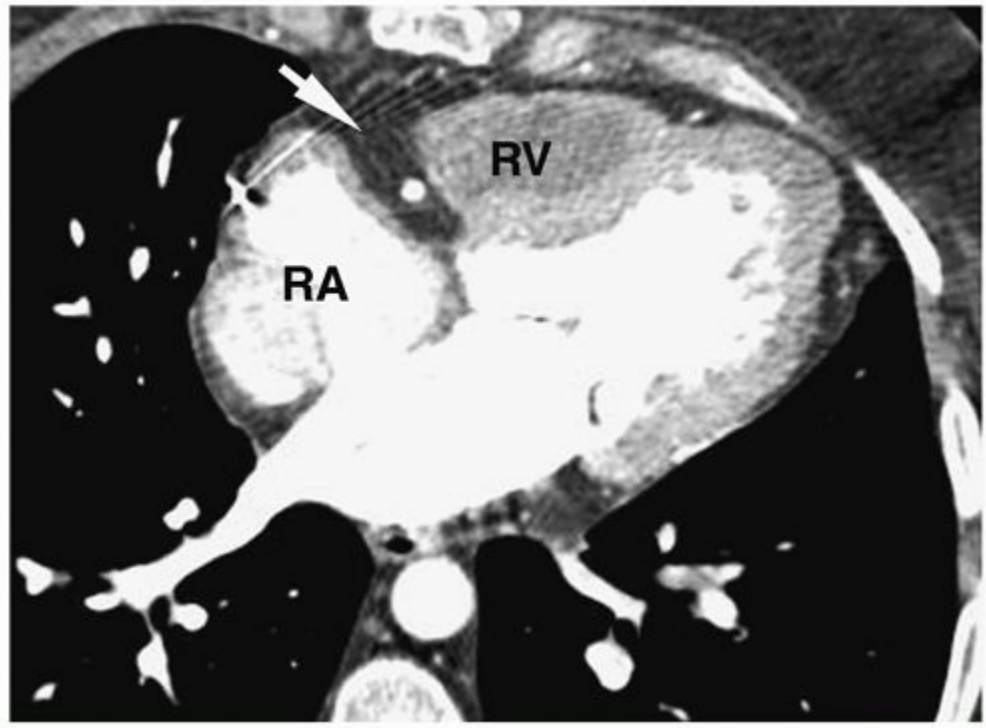
CHD - Transposition of the Great Vessels



CHD - Tetralogy of Fallot



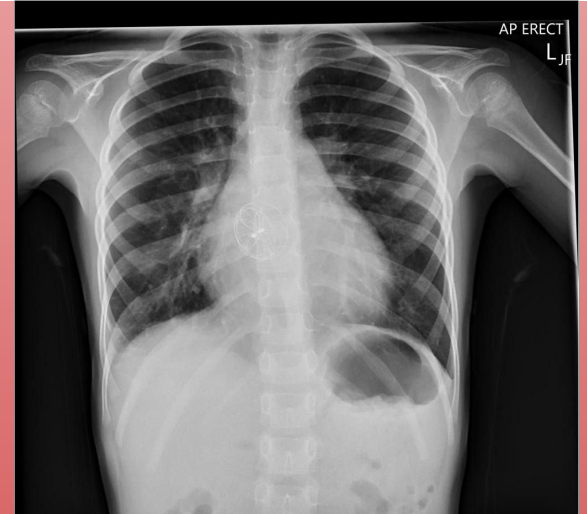
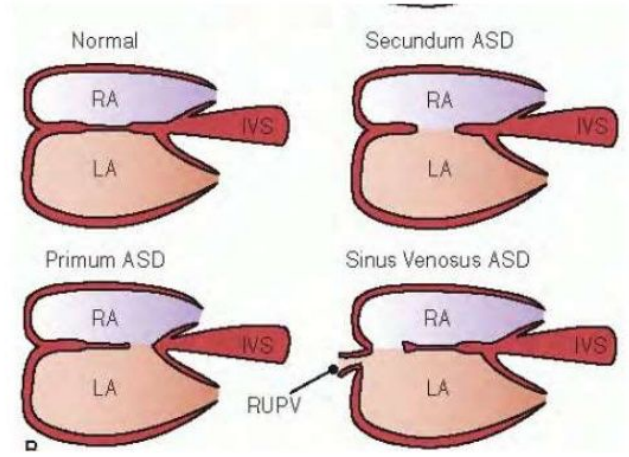
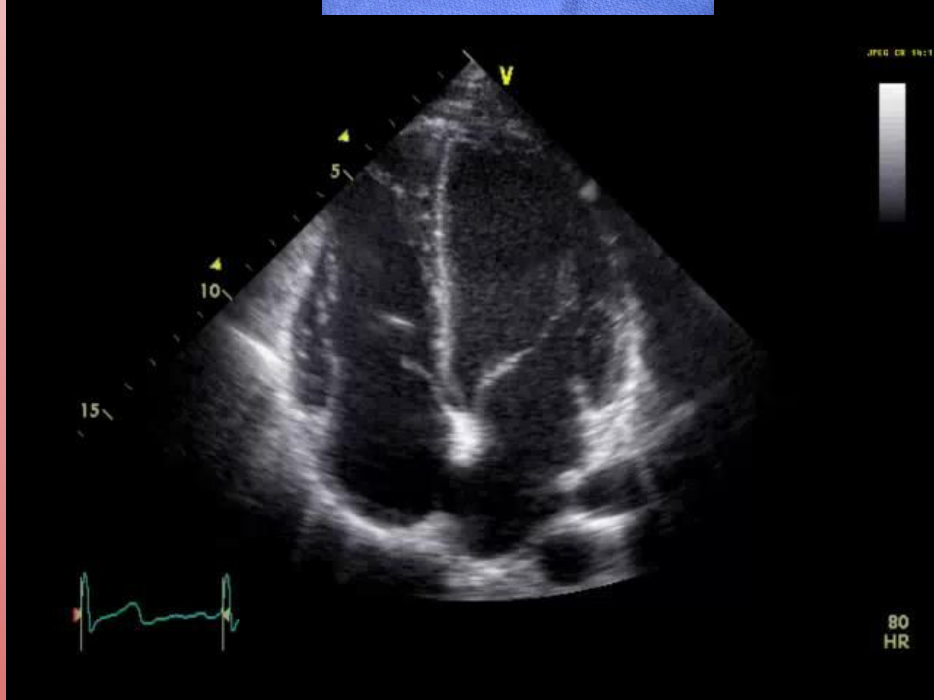
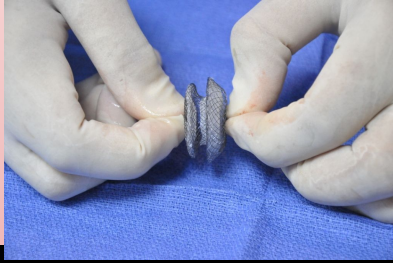
CHD



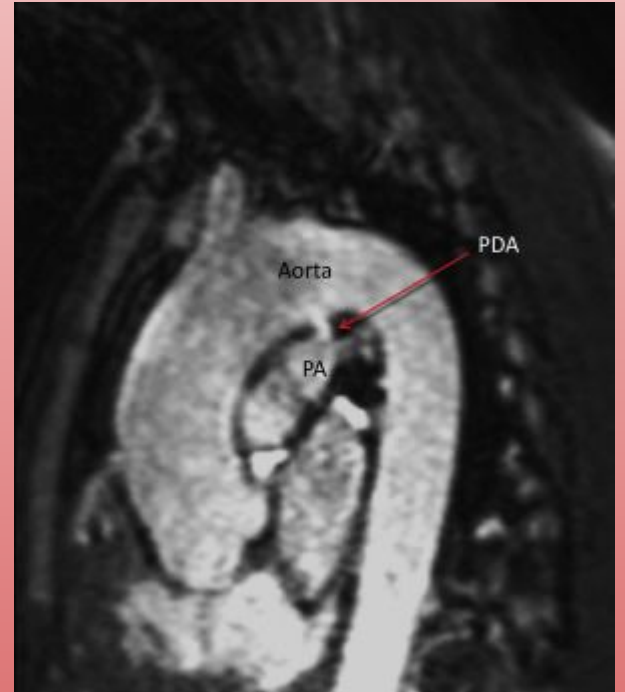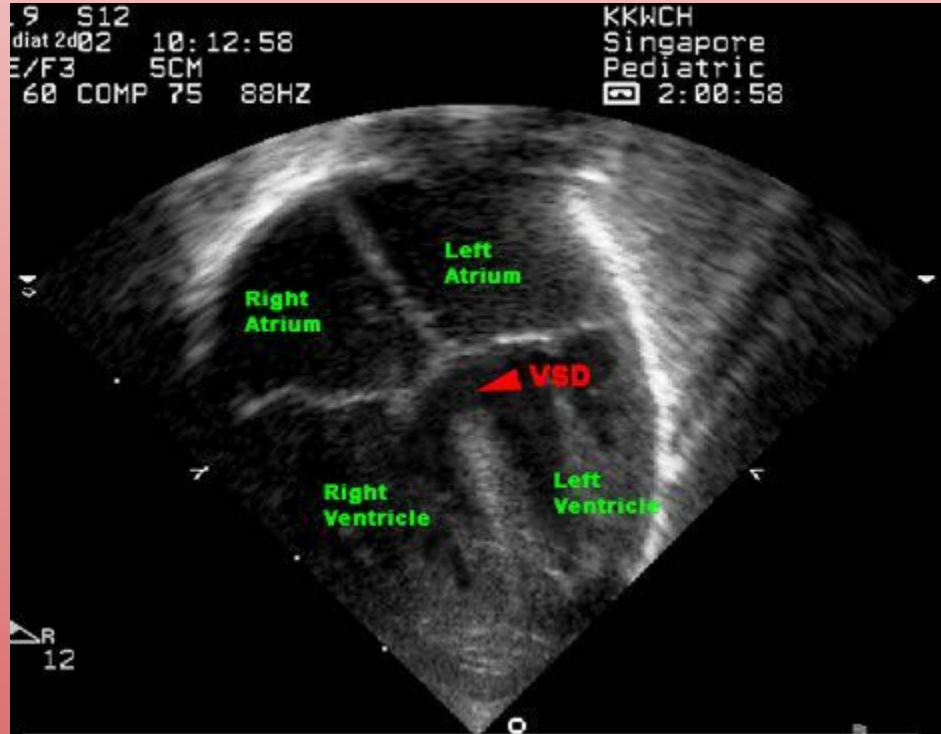
CHD-Non-cyanotic lesions (LateR)

- Atrial Septal Defects
 - “Fixed and split S2”-increased L to R shunting leads to increased blood across pulmonic valve causing it to close earlier
 - May lead to paradoxial emboli
- Ventricular Septal Defects
 - MC defect
 - Can lead to CHF
 - Poor weight gain early in life
 - Larger the VSD, smaller the murmur (holosystolic)
- Patent Ductus Arteriosus
 - PGE keeps open
 - Indomethacin closes
 - Rubella → PDA
 - Continuous “machine like” murmur

CHD



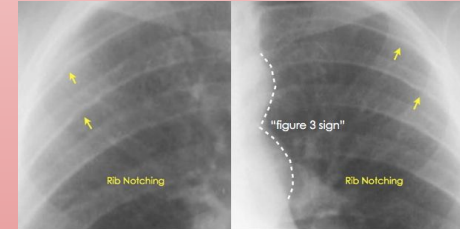
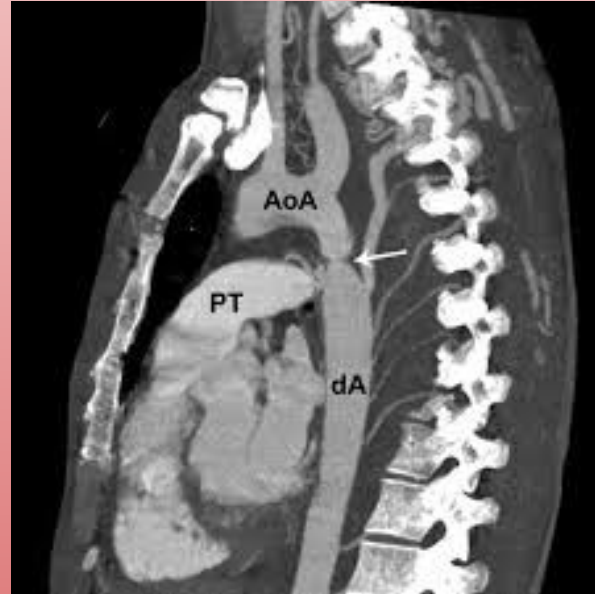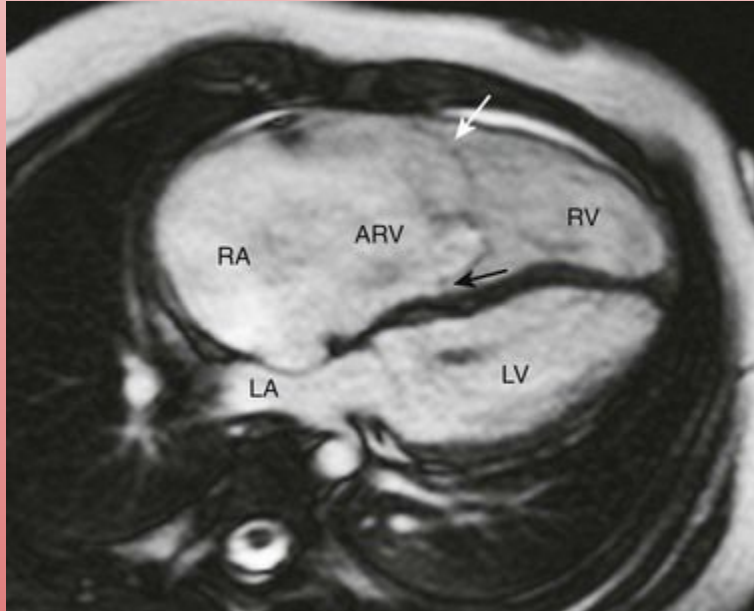
CHD



CHD-Non-cyanotic lesions

- Eisenmenger-over time L to R (redundant) shunting leads to changes in the RV, pressure begins to increase and shunt reverses to R to L because that becomes the high to low flow
- Coarctation of the Aorta-narrowing, associated with BAV and Turner
 - Sequence of CoA leading to BAV
 - HTN in UE, weak and delayed pulses LE

CHD



Coarctation of the Aorta

- Hypertension (upper extremity > lower extremity pulse/BP)
- CHF symptoms
- Systolic murmur
- Higher incidence of subarachnoid hemorrhage
- Associated with Turner syndrome (webbed neck and short stature)
- CXR reveals rib notching and the "figure 3 sign" (prestenotic dilation of aortic arch and left subclavian)

DISORDER

DEFECT

Alcohol exposure in utero (fetal alcohol syndrome)

VSD, PDA, ASD, tetralogy of Fallot

Congenital rubella

PDA, pulmonary artery stenosis, septal defects

Down syndrome

AV septal defect (endocardial cushion defect), VSD, ASD

Infant of diabetic mother

Transposition of great vessels, VSD

Marfan syndrome

MVP, thoracic aortic aneurysm and dissection, aortic regurgitation

Prenatal lithium exposure

Ebstein anomaly

Turner syndrome

Bicuspid aortic valve, coarctation of aorta

Williams syndrome

Supravalvular aortic stenosis

22q11 syndromes

Truncus arteriosus, tetralogy of Fallot

Kawasaki Disease

- Medium vessel vasculitis
- Young children
- **CRASH and burn**
 - Conjunctival injection
 - Rash (desquamating)
 - Adenopathy (cervical)
 - Strawberry tongue
 - Hand-foot changes (erythema, edema)
 - Burn: fever
- Complication: development of coronary artery aneurysms → MI
- Tx: IVIG and aspirin***
 - Only disease where you would treat a child with aspirin

Drugs

- CCB-important to differentiate non-dihydropyridines (verapamil and diltiazem)
- Nitrates-decrease preload by venodilation, contraindicated in RCA infarct
- Statins-HMG CoA reductase inhibitor, myalgia, LFTs (decrease LDL cholesterol)
- Fibrates-never with statins because of risk of myalgias (decrease TG)
- Adenosine-K⁺, terminates SVT

Thanks! Extra Slides

These upcoming slides are to help you prepare for the exam. They have high yield associations.

Any questions or concerns?

*Thank
You*

EKGs

- Irregularly irregular with no p waves and inconsistent RR intervals
 - High Yield new onset
 - MC risk factors
- Regular PP intervals and RR intervals but no association between P and R
 - High Yield associations (2)
- Greater than 3 distinct P morphologies
 - High Yield association
- Short PR interval with prolonged QRS
 - High yield medication and side effects
- Undulating QRS
 - High yield causes (6), treatment
- Atrial fibrillation
 - Hyperthyroidism
 - CAD, HTN
- Third Degree Heart Block
 - Lyme Disease, Baby from Lupus mom
- Multifocal Atrial Tachycardia
 - COPD
- Wolff Parkinson White
 - Procainamide, SLE
- Torsades
 - Ondansetron, macrolides, FQN, haloperidol, IA antiarrhythmics, TCA
 - Magnesium for treatment

EKGs

- Low amplitude with beat variation, pulsus paradoxus and distant heart sounds, JVD
- Disorder of repolarization leads to prolonged QT
 - W/ deafness, Mode of inheritance
 - W/o deafness, Mode of inheritance
- Pseudo RBBB
 - MC, mode of inheritance
- Diffuse STE
- Cardiac tamponade
- Long QT
 - Jervell and Lange-Nielsen syndrome, AR
 - Romano Ward, AD
- Brugada
 - Asian males, AD
- Pericarditis

Murmurs

(bolded phrases words are essentially pathognomonic)

- Systolic, crescendo-decrescendo, **radiates to carotids**, louder with squatting, quieter with valsalva
 - MC pathology, earlier onset
- Systolic, louder with valsalva, quieter with squatting, S4 auscultated
 - Path, MC genetics
- Holosystolic murmur that **radiates to the axilla**
- Late systolic murmur with **midsystolic click**, louder with valsalva
- Aortic Stenosis
 - Calcification aortic valve, bicuspid valve
- HOCM (subset of hypertrophic)
 - Myofibril disarray, AD
- MR
- MVP

Murmurs

(bolded phrases words are essentially pathognomonic)

- **Continuous machine-like murmur**
 - High yield infection
- **Wide, fixed and split S2**
- Holosystolic, harsh-sounding murmur
 - High yield association
- Diastolic murmur with **opening snap**
- Blowing diastolic murmur
 - PE findings
 - High yield associations
- Late systolic/continuous murmur, may radiate to back
- PDA
 - Rubella
- ASD
- VSD
 - Down Syndrome, Alcohol
- MS
- AR
 - Widened pulse pressure, **head bobbing, bounding pulses in nails**
 - Aortic root dilation in setting of connective tissue disorders, syphilis (tree bark)
- Coarctation of the Aorta
 - Turner Syndrome
 - **High BP in upper extremities, low BP in lower extremities, notched ribs on CXR**

Post-MI

- MC death cause of death post MI (first 24 hours)
- New friction rub (1-3 days)
- New holosystolic murmur radiates to axilla (2-7)
 - Cause, arterial supply
- Hypotension, JVD, low voltage EKG (5-14 days)
- Step-up in O₂ concentration, holosystolic murmur
 - Cause
- Low fever, CP, friction rub weeks after MI
- Arrhythmia
- Fibrinous pericarditis
- MR
 - Rupture of papillary muscle, posterior descending artery
- Ventricular free wall rupture (leads to tamponade)
- VSD
 - Rupture interventricular septum
- Dressler

CHF

- Causes systolic HF (reduced EF)
 - DCM causes
 - Type of hypertrophy
- Causes diastolic HF (preserved EF)
 - HCM type of hypertrophy
 - RCM causes
- MI or dilated CM
 - Coxsackie B, wet beriberi, Chagas, Doxorubicin, hemochromatosis, sarcoidosis, peripartum CM
 - Eccentric
- Hypertrophy or restrictive CM
 - Concentric hypertrophy
 - Postradiation fibrosis, Loffler, amyloidosis, sarcoidosis, endocardial fibroelastosis, hemochromatosis

CHD

- Treatment early cyanotic CHD
 - Drug of choice
- Embryology failure truncus arteriosus
- Transposition of great vessels
 - embryology
 - MC association
- Kid playing and all of a sudden squats
 - How does this work?
- Association Ebstein anomaly
- High yield coarctation of aorta
- Surgery and maintenance of PDA
 - PGE
- Failure of aorticopulmonary septum formation
- Failure of spiraling aorticopulmonary septum
 - Babies of diabetic mothers
- Tetralogy of Fallot
 - Exercising increased R to L shunting, squatting increased resistance in systemic system so that R sided circulation to the lungs became the lower pressure system
- Lithium
- Turners

CHD

- VSD associations
- Marfan cardiac manifestations
- 22q11 syndromes
- Alcohol, Down syndrome
- MVP, thoracic aortic aneurysm, aortic regurgitation, aortic dissection
- Truncus arteriosus, tetralogy of Fallot