

# 25<sup>TH</sup> ANNUAL RESEARCH DAY MARCH 18-19, 2013

Oral and Poster Presentations  
Marshall University Medical Center  
Huntington, West Virginia

Planning Committee • Page 4

Guest Speaker • Page 11

Oral Session I, 8:30 AM - 9:45 AM • Page 23

Oral Session II, 10:30 AM - 11:30 AM • Page 31

Oral Session III, 1:15 PM - 2:15 PM • Page 37

Oral Session IV, 3:15 PM - 4:30 PM • Page 43

Poster Session I, 9:45 AM - 10:30 AM • Page 51

Poster Session II, 2:30PM - 3:15 PM • Page 103

List of Presenters | Page 13

Conference Agenda | Pages 14-22



**This event is supported annually by educational grants from the following Endowments:**

Roland H. Burns Memorial  
Anagene Bartram Heiner Memorial  
Thelma V. Owen Memorial  
Richard J. Stevens Memorial

**Faculty Disclosure Policy 2013**

As a sponsor accredited by the ACCME, Marshall University Joan C. Edwards School of Medicine must insure balance, independence, objectivity, and scientific rigor in all its individually sponsored or jointly sponsored educational activities. All event faculty participating in a sponsored activity are expected to disclose to the activity audience any significant financial interest or other relationship with the manufacturer(s) of any commercial product(s) and/or provider(s) of commercial services discussed in an educational presentation and 2) with any commercial supporter(s) of the activity. Also, all event faculty are required to disclose any planned discussion of an unlabeled use of a commercial product or an investigational use not yet approved for any purpose by the FDA.

**No Faculty Disclosure or conflicts of interest are indicated for this CME activity.**

**Disclosure of Conflicts of Interest**

Marshall University Joan C. Edwards School of Medicine (MUJCESOM) requires instructors, planners, managers and other individuals who are in a position to control the content of this activity to disclose any real or apparent conflict of interest they may have as related to the content of this activity. All identified real or apparent conflicts of interest are thoroughly reviewed and resolved by MUJCESOM's planning process for fair balance, scientific objectivity of studies mentioned in the materials or used as the basis of content, and appropriateness of patient care recommendations. Disclosure information will be presented verbally or in print to participants before presentation of the agenda lectures.

Completed faculty disclosure forms are on file in the CME Office.



Marshall University Joan C. Edwards School of Medicine is accredited by the Accreditation Council for Continuing Medical Education (ACCME) to provide continuing medical education for physicians.

The program will consist of a series of oral and poster presentations highlighting basic and clinical research performed by School of Medicine students, residents and fellows. Please use pages 11 through 16, to locate presenters, their abstracts, presentation times and location of presentation. The complete agenda is available at <http://www.musom.marshall.edu> (research link)

### **INTENDED AUDIENCE**

The 25th Annual Research Day is designed for physicians, residents, basic scientists, medical students, graduate students, and other interested health professionals.

### **GOALS**

- 1) To involve faculty, medical and graduate students in the process required to formally present their research in either oral or poster presentations.
- 2) To inform and involve the community in ongoing research at Marshall University Joan C. Edwards School of Medicine.
- 3) To encourage the attitude among faculty, residents, and students for Continuing Medical Education in the area of clinical research.

### **GLOBAL LEARNING OBJECTIVES**

By the end of these lectures the participant will be able to:

- 1) Compare different approaches to medical investigation.
- 2) Compare and contrast the importance of basic research and cellular mechanisms as it relates to human disease.
- 3) Discuss and review research related to current and future improvements in the clinical management of patients.
- 4) Interpret and analyze data for medical investigation to potentially determine the effectiveness towards improving patient care.
- 5) Stress the importance of translational research benefits to the basic scientist in support of the practicing physician.
- 6) Discuss the quality of research in medical education and its application to educational practice in undergraduate and graduate medical education.

**CREDIT STATEMENT**

Marshall University Joan C. Edwards School of Medicine designates this educational activity for a maximum of 5.0 AMA PRA Category 1 Credits™. Physicians should only claim credit commensurate with the extent of their participation in the activity. (Session Registration and Evaluation are required).

**EVALUATION FORM Completion**

Please follow specific instructions for completing the bar coded evaluation form. Keep your “X’s” in the bubbles and your written comments in the designated boxes. Your input is needed for planning future events.

**ASSISTED SERVICES**

If special arrangements are required for an individual with a disability to attend these events, please contact Continuing Medical Education at (304) 691-1770 no later than 1 week before the event date or See a CME Representative at the Registration Area on the day of the event.


**PLANNING COMMITTEE - NO CONFLICTS INDICATED**

- David N. Bailey, MBA, CME
- Todd Gress, MD
- Richard Niles, PhD, Chair
- Darshana Shah, PhD

**STAFF COORDINATORS - NO CONFLICTS INDICATED**

- Anita Mathis .....BMS Coordination & Registration
- Patricia “Trish” Martin ....Registration
- Brian Patton .....Web Publications, Online Abstract  
Submission Form Design and  
Content Retrieval, Judging  
tabulations summary

# RESEARCH DAY



## PAST INVITED LECTURERS

### **2012 - William Thies, Ph.D.**

Vice President, Medical Scientific Affairs  
Alzheimer's Association  
Chicago, IL

1) *Alzheimers Today and the Future*

### **2011 – Susan S. Smyth, MD, Ph.D.**

Professor of Medicine  
Director, MD/Ph.D. Program  
University of Kentucky

1) *Cardiovascular Complications of Obesity*

### **2010 – Gregory Germino, MD**

Deputy Director of the National Institute of Diabetes and Digestive  
& Kidney Disease (NIDDK) at the National Institutes of Health (NIH)  
Bethesda, Maryland

1) *Dia-besity: converging problems, emerging science*

### **2008 – Gregory Alan Hale, MD**

Associate Professor of Pediatrics  
University of Tennessee

1) *Transplantation and Cellular Therapies: Current Research  
and Future Opportunities*

2) *An introduction to Hematopoietic Cell Transplantation*

### **2007 –Daniel D. Bikle, M.D., Ph.D.**

Professor of Medicine and Dermatology  
In residence University of California

1) *The skin game: Calcium and vitamin D regulated cellular  
differentiation*

2) *Vitamin D: how much do we need and why*

### **2006 - Mark E. Shirliff, Ph.D.**

Assistant Professor, Department of Biomedical Sciences  
Dental School, University of Maryland-Baltimore  
Baltimore, Maryland

1) *Staphylococcus aureus biofilms: in vitro and in vivo studies*

### **2006 - J. William Costerton, Ph.D.**

Director & Professor, Center for Biofilms, School of Dentistry  
University of Southern California  
Los Angeles, California

1) *Biofilms in Device-related and other Chronic Bacterial Diseases*

### **2005 – William F. Balistreri, MD**

Director, Gastroenterology  
Cincinnati Children's Hospital Medical Center

1) *Inborn Errors of Bile Acid Biosynthesis*

2) *Viral Hepatitis 2005*

## PAST INVITED LECTURERS

### **2004 – Joseph S. McLaughlin, MD**

Professor Emeritus of Surgery  
University of Maryland

- 1) *Traumatic Ruptured Aorta*
- 2) *Strange Tumor I Have Known*

### **2003 – W. Jackson Pledger, Ph.D.**

Professor, Interdisciplinary Oncology  
University of South Florida College of Medicine  
Tampa, Florida

- 1) *Regulation of proliferation by cyclin dependent kinase*
- 2) *Functional genomics and cancer therapy*

### **2002 – Alan H. Jobe, M.D., Ph.D.**

Professor of Pediatrics  
Cincinnati Children's Hospital Medical Center  
Cincinnati, Ohio

- 1) *Mechanisms of lung injury in the preterm*
- 2) *Translational research on lung maturation based on clinical observations*

### **2001 - Arnold Starr, M.D.**

Director, Alzheimers' Research Center  
Institute Brain Research of California, Irvine

- 1) *Hearing but not understanding: auditory nerve dysfunction in the presence of preserved cochlear receptors*
- 2) *Patients' stories and their seminal importance for research*

### **2000–Fredrick L. Brancati, M.D., M.H.S.**

Associate Professor, Medicine and Epidemiology  
John Hopkins Medical Institute

- 1) *Novel risk factors for type 2 diabetes mellitus and their implications for treatment*
- 2) *Prevention and clinical epidemiology in the new millenium*

### **1999 – Robert B. Belshe, MD**

Director and Professor, Div. of Infectious Diseases and Immunology  
St. Louis University

- 1) *Live attenuated influenza vaccine: using genetics to defeat the flu*
- 2) *Vaccines for the 21<sup>st</sup> century*

### **1998 – Jerome S. Brody, MD**

Vice-Chairman of Medicine for Research, Professor of Medicine  
Director, Pulmonary Center  
Boston University School of Medicine

- 1) *Lung development: lesson from flies connections to cancer*
- 2) *Molecular approaches to the diagnosis of lung cancer*

### **1997 – Rochelle Hirschhorn, MD**

Professor of Medicine, Department of Medicine  
NYU School of Medicine

- 1) *Advances in defects in host defense*
- 2) *Reflection on the changing face of medicine*

## PAST INVITED LECTURERS

### **1996 – Stuart F. Schlossman, MD**

Baruj Benacerraf Professor of Medicine  
Harvard Medical School  
Chief, Division of Tumor Immunology  
Dana-Barber Cancer Institute, Boston

- 1) *Human T-cell activation*
- 2) *What's in a name – cd nomenclature*

### **1995 – Frank M. Torti, MPH, MD, FACP**

Director, Comprehensive Cancer Center  
Professor Charles L. Spurr Professor of Medicine  
Section Head for Hematology/Oncology, Wake Forest University  
Chairman, Department of Cancer Biology  
Bowman Gray School of Medicine

- 1) *New pathways for the regulation of iron*
- 2) *Popeye spinach and iron: the politics*

### **1994 – Abner Louis Notkins, MDB**

Director, Intramural Research Program  
Chief, Laboratory of Oral Medicine National Institute of Dental Research,  
National Institutes of Health, Bethesda, MD

- 1) *Polyreactive antibody molecules and matter*
- 2) *The Bethesda experiment*

### **1993 – Erling Norrby, MD, Ph.D.**

Dean of Research and Professor of Virology  
Karolinska Institute, Department of Virology Sweden

- 1) *Immunization against HIV-2/SIV in monkeys*
- 2) *The selection of Nobel Prize winners*

### **1992 – Simon Karparkin, MD**

Professor of Medicine  
New York University School of Medicine  
1) *Role of thrombin, integrins and oncogenes*  
2) *How scientific discoveries are made*

### **1991 – Robert M. Chanock, MD**

Chief, Laboratory of Infectious Diseases  
National Institute of Allergy & Infectious Diseases  
National Institutes of Health, Bethesda, MD  
1) *Epidemiology, pathogenesis, therapy*  
2) *New approaches to development of treatment plans*

### **1990 – Dewitt S. Goodman, MD**

Director, Institute of Human Nutrition  
Director, Arteriosclerosis Research Center  
Tiden-Weger-Bieler Professor of Preventative Medicine  
Professor of Medicine, Columbia University,  
College of Physicians and Surgeons  
Director, Division of Metabolism and Nutrition  
Department of Medicine  
Columbia-Presbyterian Medical Center, New York  
*Retinoid and retinoid-binding proteins*



## PAST INVITED LECTURERS

**1989 – Michael A. Zasloff, MD, Ph.D.**

Charles E.H. Upham, Profess of Pediatrics  
University of Pennsylvania School of Medicine  
Chief, Division of Human Genetics & Molecular Biology  
The Children's Hospital of Philadelphia

- 1) *The flow of genetic information*
- 2) *Magainin peptides*

**24TH RESEARCH DAY CONFERENCE PRESENTATION WINNERS**

---

**MARCH 20, 2012**

---

**THELMA V. OWEN MEMORIAL  
CLINICAL VIGNETTE POSTER WINNER  
M. Allison Wolf**

*"Benzyl isothiocyanate targets chemoresistant and metastatic head and neck squamous cell carcinoma cells"*

---

**ROLAND H. BURNS MEMORIAL  
CLINICAL SCIENCE POSTER WINNER  
Kimberly Weaver**

*"Community hospital experience with SILS cholecystectomy"*

---

**ANAGENE B. HEINER MEMORIAL  
BASIC SCIENCE POSTER WINNER  
Tilahun Belay**

*"Relapse after 40 years, follicular non-hodgkin's lymphoma reoccurring after 40 years from treatment"*

---

**ROLAND H. BURNS MEMORIAL  
CLINICAL SCIENCE ORAL WINNER  
Lauren Thompson**

*"Abusive head trauma in West Virginia in children <2 years of age: a statewide multicenter analysis"*

---

**THELMA V. OWEN MEMORIAL  
CLINICAL VIGNETTE ORAL WINNER  
Andrea Lauffer**

*"Endoscopy suite explosion: a rare complication of a screening colonoscopy"*

---

**ANAGENE B. HEINER MEMORIAL  
BASIC SCIENCE ORAL WINNER  
Clayton M. Crabtree**


*"Capsaicin induces apoptosis in human small cell lung cancer via the TRPV pathway"*

---

**ACADEMY OF MEDICAL EDUCATORS POSTER WINNER  
Richard G. Irwin**

*"A unique global health didactic course for preclinical medical students at Marshall University"*

***"The Use of Vitamin D in Clinical Practice"***



**John J. Cannell, MD**  
*Executive Director*  
Vitamin D Council  
San Luis Obispo, CA

***No Conflicts Indicated***

**Learning Objectives:**

- 1) To discuss whether vitamin D can and should be used in clinical practice.
- 2) To review some of the diseases that are implicated by vitamin D deficiency.
- 3) To identify what diseases can be treated or prevented by use of vitamin D supplementation, and what the level of evidence is for use.
- 4) To review some of the most recent phase IIb trials in vitamin D research

## **ABOUT THE RICHARD J. STEVENS, MD MEMORIAL LECTURE**

The Richard J. Stevens, MD Memorial Lecture is supported annually by the family of Dr. Stevens. Dr. Stevens was an outstanding medical practitioner characterized by Dean Charles H. McKown, Jr., of the Marshall University Joan C. Edwards School of Medicine as a pioneer “who was never in a hurry but always on the move.”

Born in Portsmouth, Ohio, Dr. Stevens received his undergraduate degree from Marshall University, attended West Virginia School of Medicine for two years, then went on to earn his medical degree from Rush Medical School in Chicago.

Dr. Stevens returned to Huntington in 1941 as one of the first board certified practitioners in internal medicine in the area. He was a member of the Alpha Omega Alpha, the medical honorary, as well as gastroenterology and research societies.

Dr. Stevens was one of three physicians who first researched prothrombin testing for guidance in administering anticoagulants to patients with coronary occlusion.

Remembered as genuinely committed to his profession, his community and those around him, he had the unique ability to bring about a meeting of the minds among colleagues, patients and families.

The memorial lecture is presented each year at the Marshall University Joan C. Edwards School of Medicine’s Research Day. It was established by Dr. Steven’s wife, Dr. Sarah Louise Cockrell Stevens, and their seven children: Chari Louise Stevens Singleton, Mary Alice Stevens, Richard J. Stevens II, Johanna Stevens Holswade, Robert C. Stevens, and Randall C. Stevens.

## LIST OF PRESENTERS

### No Disclosures or Conflicts of Interest (Abstracts)

Adams, Jacquelyn.....	131	MA, Cain.....	49
Ahmad, Taha.....	52	Mahmood, M. Adeel.....	117
Ahmed, Saqib.....	76	Masannat, Yanal.....	64
Ahmed, Saqib.....	78	Masannat, Yanal.....	73
Ahmed, Saqib.....	106	Masannat, Yanal.....	139
Alabd Alrazzak B.....	26	Mathis, Sarah E.....	46
Alabd Alrazzak B.....	125	Matt, Laurie B.....	71
Alabd Alrazzak, B.....	140	McNees, Christopher A.....	81
Alabd ALrazzak, Baraa.....	143	Melvin, Kelly.....	119
Aljayoussi, Randa.....	34	Mesleh, Ghada.....	44
AL Ourani, Mohammed.....	150	Mo, Bi.....	54
Alshareef, Ameen.....	105	Mo, Bi.....	151
Alshareef, Ameen.....	133	Mulpuri, Nitisha.....	68
Ambrosia, Jerry.....	101	Nande, Rounak.....	35
Belay, Tilahun.....	87	Olajide, Omolara A.....	66
Belay, Tilahun.....	116	O'Malley, Kacey.....	65
Bell, Rebecca.....	138	Owen, Benjamin.....	118
Bronder, Jay.....	28	Panchal, Amar.....	95
Brown, Kelli.....	42	Phelan, Michael P.....	40
Brownfield, Jared.....	110	Pritt, Audra.....	152
Cannell, John.....	11	Racine, Christopher.....	108
Carper, Miranda B.....	98	Ray, Kristeena.....	84
Chambers, Michael James.....	33	Richardson, Russ.....	25
Chaudhry S.....	86	Roy, Aviral.....	55
Cottrell, Jesse.....	70	Roy, Aviral.....	120
Cummings, Kelly.....	41	Salava, Jonathon.....	85
DeChant, Ross.....	82	Salazar, Alexander.....	100
Denver, James.....	88	Salisbury, Travis.....	124
Devabhaktuni S.....	127	Sanford, Zachary.....	123
Douglas, Jilian.....	69	Schuetz, Carly.....	96
Douglas, Jillian.....	89	Shuler, Franklin D.....	24
Douglas, Jillian.....	132	Shuler, Franklin D.....	45
Eckerd, Morgan.....	99	Shuler, Franklin D.....	57
El Gassier, Atef.....	115	Shuler, Franklin D.....	62
Elgariad, Yousof.....	80	Shuler, Franklin D.....	77
Elgariad, Yousof.....	83	Shuler, Franklin D.....	121
Elgariad, Yousof E.....	130	Shuler, Franklin D.....	126
Etman, Yasser.....	137	Shuler, Franklin D.....	134
Evans, Joseph.....	79	Shuler, Franklin D.....	135
Fährmann, Elke.....	147	Stone, Ryan.....	149
Fahrman, Johannes F.....	27	Stover, Cody A.....	74
Feigal, David.....	142	Tamski, Holly L.....	36
Gabi, Alaa.....	112	Teklehaimanot, Senait.....	56
Garla, Vishnu.....	61	Tetteh, Shirley.....	75
Goyal, Neha.....	67	TETTEH, Shirley.....	93
Goyal, Neha.....	136	Tomblin, Justin K.....	47
Granger, Jessica.....	53	Touma, Susan.....	146
Harfoush, Obaeda.....	111	Valentine, Meagan.....	63
Hattab, Yousef.....	92	Van Meter, Stephanie.....	144
Israelsen, Stanford T.....	129	Vence, Lacey.....	60
Kanbour, Majid.....	122	Vence, Lacey.....	141
Kanbour, Majid.....	145	von Allmen, Douglas.....	109
Kim, Jeffery D.....	91	Weaver, Kimberly.....	72
Lau, Jamie K.....	29	Witte, Theodore R.....	48
Lavender, Chad.....	107	Woldegiorgis, Hailegiogis.....	90
Lavender, Chad.....	114	Wolf, M. Allison.....	39
Lewis, Robert J.....	128	Woods, Daniel.....	58
Loudin, Sean.....	104	Yan, Yanling.....	38
Ma, Bing.....	32	Yan, Yanling.....	113
Ma, Bing.....	94	Yousef, George M.....	59
		Zhang, Nan.....	97

## RESEARCH DAY AGENDA

**MARCH 19, 2013**

Specific learning objectives will be presented with each oral presentation.

Questions and answers encouraged throughout all sessions.

No apparent speaker conflicts indicated as supported by disclosure.

<b>OPENING LECTURES</b>	<b>REGISTRATION</b> <b>Welcome Joseph I. Shapiro, MD, Dean</b> <b>JCESOM, Marshall University</b> <b>Moderator: Richard Niles, PhD, Conference Chair</b>	<b>7:30AM</b> <b>8:15AM</b>
<hr/>		
<b>ORAL SESSION I</b>	<b>PAGE 23</b>	
<hr/>		
1 Franklin D. Shuler	Where can orthopaedic hardware safely be placed for syndesmosis fixation: An anatomic study	8:30AM
2 Russ Richardson	Cost-Savings Analysis of Telemedicine Use for Ophthalmic Screening in a Rural Appalachian Health Clinic	8:42AM
3 Alabd Alrazzak B	The Effect of Passive Smoking On Hemoglobin Level During The First 2 Years of Life	8:54AM
4 Johannes F. Fahrman	Eicosapentaenoic Acid and Docosahexaenoic Acid as Potential Chemo-sensitizing Agents for the Treatment of Chronic Lymphocytic Leukemia	9:06AM
5 Jay Bronder	Live lecture vs. online module for teaching musculoskeletal exam skills	9:18AM
6 Jamie K. Lau	Inhibition of cholinergic signaling causes apoptosis in human bronchioalveolar carcinoma	9:30AM
<hr/>		
<b>BREAK</b>	<b>POSTER SESSION I – ATRIUM – PAGE 51</b>	<b>9:30-10:30AM</b>
<hr/>		
<b>ORAL SESSION II</b>	<b>PAGE 31</b>	
<hr/>		
7 Bing Ma	Sandwich-type Nanofiber Scaffolds with Square Arrayed Wells and Structured Cues for Skin Regeneration Applications	10:30AM
8 Michael James Chambers	Anterior Cruciate Ligament (ACL) Reconstruction Outcomes in Obese Patients	10:42AM
9 Randa Aljayoussi	Assessment of The Efficacy of Two Protocols used for Radio Active Iodine (RAI) Treatment of Thyroid Cancer	10:54AM
10 Rounak Nande	Targeting a newly established spontaneous feline fibrosarcoma cell line by gene transfer	11:06AM
11 Holly L. Tamski	MicroRNA Regulation of Adipose Derived Stem Cells	11:18AM
<b>John Cannell, MD</b>	<b>The Use of Vitamin D in Clinical Practice</b>	<b>11:30AM</b>
	<b>BOX LUNCH</b>	<b>12:40PM</b>

## RESEARCH DAY AGENDA

<b>ORAL SESSION III</b>		<b>PAGE 37</b>	
12	Yanling Yan	Protein Carbonylation in Regulation of Renal Proximal Tubular Na/K-ATPase signaling and Sodium Transport	1:15PM
13	M. Allison Wolf	Benzyl isothiocyanate enhances chemotherapy and reduces migration and invasion of head and neck squamous carcinoma cells	1:27PM
14	Michael P. Phelan	Documentation of Endotracheal Tube Position Confirmation Among Different Emergency Department Providers	1:39PM
15	Kelly Cummings	How does the TEI indice correlate with bile acid levels in women with intrahepatic cholestasis of pregnancy?	1:51PM
16	Kelli Brown	Tic Disorders and Functional Constipation as Complicating Conditions in Children Presenting for Evaluation for Attention Deficit Hyperactivity Disorder (ADHD)	2:03PM
<b>BREAK</b>		<b>POSTER SESSION II- ATRIUM – PAGE 103</b>	<b>2:30-3:15PM</b>
<b>ORAL SESSION IV</b>		<b>PAGE 43</b>	
17	Ghada Mesleh	Clinical Features of Congestive Heart Failure Related Pleural Effusions by Echocardiographic Classification of Ventricular Dysfunction	3:15PM
18	Franklin D. Shuler	Teaching the Millennial Student: How well have the Baby Boomer /Generation X teachers adapted in an Academic Orthopaedic Department?	3:27PM
19	Sarah E. Mathis	Resveratrol suppresses lipogenesis, growth and viability of pancreatic and breast cancer stem-like cells	3:39PM
20	Justin K. Tomblin	Aryl Hydrocarbon Signaling Inhibits Mitogenic Adipokine Signaling in Breast Cancer Cells	3:51PM
21	Theodore R. Witte	Promotion of Breast Cancer Invasion and Metastasis by Benzo[a]Pyrene May Be Reduced by the Consumption of Omega-3 Polyunsaturated Fatty Acids	4:03PM
22	Cain MA	Incidence of Vaginal Cuff Dehiscence and Urinary Tract Injury after Total Laparoscopic Hysterectomy	4:15PM
<b>RESEARCH DAY AWARDS PRESENTATION - Harless Auditorium</b>			<b>4:30PM</b>

## RESEARCH DAY AGENDA

PRESENTER	POSTER PRESENTATIONS SESSION I ATRIUM • PAGE 51	9:45AM - 10:30AM
1 Taha Ahmad	Genetic Polymorphisms in CYP2B6 and Sudden Death of Methadone Users in West Virginia and Kentucky	9:45AM - 10:30AM
2 Jessica Granger	Effect of hemodynamic management in the perinatal outcomes of obese pregnant patients	9:45AM - 10:30AM
3 Bi Mo	A Case of Congenital Unilateral Absence of the Vas Deferens	9:45AM - 10:30AM
4 Aviral Roy	Interstitial nephritis as a rare manifestation of Cryptococcus in an AIDS patient	9:45AM - 10:30AM
5 Senait Teklehaimanot	Urgent Capsule Endoscopy in a Hospitalized Patient with Obscure Overt GI Bleeding Changes Subsequent Management	9:45AM - 10:30AM
6 Franklin D. Shuler	Physical Education and Bone Mass Development	9:45AM - 10:30AM
7 Daniel Woods	Pigmented Villonodular Synovitis Presenting as Anterior Knee Pain with Non-classic MRI Findings	9:45AM - 10:30AM
8 George M. Yousef	Healthcare Provider Barriers to Influenza Vaccination	9:45AM - 10:30AM
9 Lacey Vence	Inhibition of Hypoxia-Inducible Factor-1 alpha Expression in Melanoma by Ascorbic Acid	9:45AM - 10:30AM
10 Vishnu Garla	A rare case of Cushing syndrome secondary to squamous cell lung cancer	9:45AM - 10:30AM
11 Franklin D. Shuler	Bisphenol A (BPA): an integral component of vitamin D deficiency?	9:45AM - 10:30AM
12 Meagan Valentine	Chmp1 negatively regulates EGF signaling in Drosophila wing vein development	9:45AM - 10:30AM
13 Yanal Masannat	A case of atypical femoral fracture associated with Alendronate therapy	9:45AM - 10:30AM
14 Kacey O'Malley	Diagnosis and treatment of anaplastic ependymoma in a child less than one year of age	9:45AM - 10:30AM
15 Omolara A Olajide	A RARE CASE OF ALTERED MENTAL STATUS	9:45AM - 10:30AM



## RESEARCH DAY AGENDA

PRESENTER	POSTER PRESENTATIONS SESSION I ATRIUM • PAGE 51	9:45AM - 10:30AM
16 Neha Goyal, M.D	A case of Posteromedial papillary muscle rupture	9:45AM - 10:30AM
17 Nitisha Mulpuri	Management of a pregnant patient with a history of Hansen's disease and co-infection with neurosyphilis	9:45AM - 10:30AM
18 Jillian Douglas	Elevated PTH: True or False Positive?	9:45AM - 10:30AM
19 Jesse Cottrell	Large Asymptomatic Adrenocortical Carcinoma in a Primagravida: Case Report	9:45AM - 10:30AM
20 Laurie B. Matt	Metastatic Lung Cancer to the Liver and Pancreas	9:45AM - 10:30AM
21 Kimberly Weaver	Discovery of Duodenal Adenocarcinoma in a Patient with Celiac Disease	9:45AM - 10:30AM
22 Yanal Masannat	Continuous Glucose Monitoring System (CGMS) – useful tool to detect glycemic variability	9:45AM - 10:30AM
23 Cody A. Stover	Capsaicin: a novel dietary therapeutic agent in human small cell lung cancers	9:45AM - 10:30AM
24 Shirley Tetteh	CALCIPHYLAXIS: A MISSED DIAGNOSIS	9:45AM - 10:30AM
25 Saqib Ahmed	H. pylori and Chronic Refractory Idiopathic thrombocytopenic purpura	9:45AM - 10:30AM
26 Franklin D. Shuler	Vitamin D Community Sampling: Results of 2012 CHH Seniorfest	9:45AM - 10:30AM
27 Saqib Ahmed	Validation of a Markerless Motion Analysis System	9:45AM - 10:30AM
28 Joseph Evans	Radiographic Screening of Breech Female Hips for Detection of Developmental Hip Dysplasia: Findings at a Small Institution	9:45AM - 10:30AM
29 Yousof Elgaried	Hemobilia with massive upper GI bleed	9:45AM - 10:30AM
30 Christopher A. McNees	MG624, a synthetic small molecule alpha7 receptor antagonist, inhibits growth of human small cell lung cancer	9:45AM - 10:30AM

## RESEARCH DAY AGENDA

31	Ross DeChant	Wernicke's Encephalopathy in a Patient Following Bariatric Surgery	9:45AM - 10:30AM
32	Yusof Elgaried	Anticoagulation Management Dilemma	9:45AM - 10:30AM
33	Kristeena Ray	Epigenetic basis of pain in patients with endometriosis	9:45AM - 10:30AM
34	Jonathon Salava	Constraining function as a simple tool of reducing operating room traffic in a total joint room	9:45AM - 10:30AM
35	Chaudhry S	Detecting forces in a reference frame: responses of stick insect campaniform sensilla to muscle forces and loads	9:45AM - 10:30AM
36	Tilahun Belay	Cirrhotic Cardiomyopathy in Gastroenterology Clinic Patients with Liver Cirrhosis	9:45AM - 10:30AM
37	James Denvir	Applications of Next Generation Sequencing in Biomedical Science Research	9:45AM - 10:30AM
38	Jillian Douglas	Grave's Disease: Typical Gone Atypical	9:45AM - 10:30AM
39	Hailegiorgis Woldegiorgis	Emphysematous pyelonephritis: - a rare but serious kidney infection in a 54 year old male patient	9:45AM - 10:30AM
40	Jeffery D. Kim	Traumatic Laryngeal Fracture in a Collegiate Basketball Player	9:45AM - 10:30AM
41	Yousef Hattab	Siunitis isn't always simple	9:45AM - 10:30AM
42	SHIRLEY TETTEH	AN UNCOMMON PRESENTATION OF AUTOIMMUNE THYROID DISEASE	9:45AM - 10:30AM
42	Bing Ma	Biomimetic Nanofiber Scaffolds for Tendon-to-bone Insertion Repair	9:45AM - 10:30AM
44	Amar Panchal	Capnocytophaga infection involving mediastinal lymph nodes and lung mass in a patient with a primary lung cancer diagnosed with EBUS TBNA with associated leukemoid paraneoplastic syndrome	9:45AM - 10:30AM
45	Carly Schuetz	Incidental Discovery of Osteosarcoma of the Jaw at Annual Dentist Visit	9:45AM - 10:30AM
46	Nan Zhang, MD	Chronic Gallstone Ileus: How Long Can It Keep Silence?	9:45AM - 10:30AM

## RESEARCH DAY AGENDA

47	Miranda B. Carper	Investigation of RGS16 mediated inhibition of pancreatic cancer metastasis	9:45AM - 10:30AM
48	Morgan Eckerd	AN UNUSUAL CASE OF CONCOMITANT ACHALASIA AND GASTRIC VOLVULUS IN AN 87 YEAR OLD FEMALE	9:45AM - 10:30AM
49	Alexander Salazar	Outcomes Of Calcium Phosphate Bone Void Fillers: A Retrospective Analysis	9:45AM - 10:30AM
50	Jerry Ambrosia	Negative Pressure Wound Therapy and External Fixator Pins: A New Technique for Proper Sealing Around the Pins	9:45AM - 10:30AM

<b>PRESENTER</b>		<b>POSTER SESSION II - ATRIUM PAGE 103</b>	<b>2:30PM - 3:15PM</b>
51	Sean Loudin	The incidence of intraventricular hemorrhage (IVH) and the utility of screening cranial ultrasounds (US) in infants born between 30 0/7 - 32 6/7 weeks gestation	2:30PM - 3:15PM
52	Ameen Alshareef	Expressive aphasia as a presentation of Mycoplasma encephalitis in a young adult patient	2:30PM - 3:15PM
53	Saqib Ahmed	Hibernoma: A Rare Adipocytic Tumor	2:30PM - 3:15PM
54	Chad Lavender	Avascular Necrosis of the Femoral Head in a 27 year old male	2:30PM - 3:15PM
55	Christopher Racine	Role of Renal Cytochrome P450 Isozymes in the Bioactivation of 3,5-Dichloroaniline In Vitro	2:30PM - 3:15PM
56	Douglas von Allmen	The use of Polyflex Stents in Refractory Benign Esophageal Strictures	2:30PM - 3:15PM
57	Jared Brownfield	Ectopic Pregnancy in A Previous Cesarean Section Scar: A Case Report	2:30PM - 3:15PM
58	Obaeda Harfoush	Diffuse Alveolar Hemorrhage as the First Presentation of Wegener's Granulomatosis	2:30PM - 3:15PM
59	Alaa Gabi	Scedosporium apiospermum Invasive Cutaneous Infection in a Kidney Transplanted Patient	2:30PM - 3:15PM

## RESEARCH DAY AGENDA

60	Yanling Yan	Ouabain-Activated c-Src as a Potential Biomarker for Salt-Sensitivity	2:30PM - 3:15PM
61	Chad Lavender	Bilateral Osteochondritis Dissecans of the Lateral Trochlea in the Knee of a 16 Year Old Female	2:30PM - 3:15PM
62	Atef El Gassier	A 57 year-old male patient with a vague chest pain	2:30PM - 3:15PM
63	Tilahun Belay	Loeys-Dietz Syndrome - a rare cause of vascular aneurysm	2:30PM - 3:15PM
64	M. Adeel Mahmood	AN INTERESTING CASE OF GRAVES' DISEASE IN A PATIENT FOLLOWING MORE THAN A DECADE OF HYPOTHYROIDISM	2:30PM - 3:15PM
65	Benjamin Owen	Biphasic changes in Schaffer collateral fiber volleys during continuous high-frequency stimulation and burst stimulation: calcium-dependence of the early hyperexcitable phase	2:30PM - 3:15PM
66	Kelly Melvin	Jimson weed toxicity in a West Virginia teen: a case study	2:30PM - 3:15PM
67	Aviral Roy	Management of Esophageal perforation post dilation with self-expanding stents: A Case Report	2:30PM - 3:15PM
68	Franklin D. Shuler	Anatomical evaluation of the retrograde fibular intra-medullary start point	2:30PM - 3:15PM
69	Majd Kanbour	Extraordinarily elevated serum levels of CA 19-9 and rapid decrease after successful therapy	2:30PM - 3:15PM
70	Zachary Sanford	Positron Emission Tomography as a Means for Assessing Atypical Growth in a Case of Ewing's Sarcoma	2:30PM - 3:15PM
71	Travis Salisbury	Define new aryl hydrocarbon receptor regulatory targets in human breast cancer cells	2:30PM - 3:15PM
72	Alabd Alrazzak B	Pediatric patient compliance in screening tests for anemia	2:30PM - 3:15PM
73	Franklin D. Shuler	Vitamin D Deficiency Correction: "at risk" populations and potential drug interactions	2:30PM - 3:15PM
74	Devabhaktuni S	Does Warfarin Treatment Put Patients at Risk for Nutritional Deficiency?	2:30PM - 3:15PM

## RESEARCH DAY AGENDA

PRESENTER	POSTER SESSION II - ATRIUM PAGE 103	2:30PM - 3:15PM
75 Robert J. Lewis	Unusual presentation of an osteoporotic pelvis fracture mimicking malignancy	2:30PM - 3:15PM
76 Stanford T. Israelsen	Nonoperative Management of Isolated Posterior Wall Fractures with an Initially Unstable Hip	2:30PM - 3:15PM
77 Yousof E Elgaried	Systemic Sarcoidosis	2:30PM - 3:15PM
78 Jacquelyn Adams	IgA Nephropathy and TTP-HUS in Pregnancy	2:30PM - 3:15PM
79 Jillian Douglas	Elevated PTH: True or False Positive?	2:30PM - 3:15PM
80 Ameen Alshareef	Hepatitis B immunity and response to booster vaccination in children with inflammatory bowel disease in West Virginia	2:30PM - 3:15PM
81 Franklin D. Shuler	Vitamin D and Pediatric Diseases in WV	2:30PM - 3:15PM
82 Franklin D. Shuler	Quorum Sensing and Quenching	2:30PM - 3:15PM
83 Neha Goyal	Isolated "Downhill" Esophageal Varices In SVC Syndrome Caused by Castleman's Disease	2:30PM - 3:15PM
84 Yasser Etman	Primary Tracheal Tumor	2:30PM - 3:15PM
85 Rebecca Bell	A Case of Ramsay Hunt Syndrome in a 13-year-old Female	2:30PM - 3:15PM
86 Yanal Masannat	Paraganglioma a case report of long standing hypertension in a 37 year old female	2:30PM - 3:15PM
87 Alabd Alrazzak B	Bacillus Cereus Bacteremia in 2 month old infant	2:30PM - 3:15PM
88 Lacey Vence	Recognizing Post-Streptococcal Guttate Psoriasis	2:30PM - 3:15PM
89 David Feigal	Extraskeletal myxoid chondrosarcoma: case report and literature review	2:30PM - 3:15PM
90 Baraa Alabd ALrazzak	Cefaroline Use In Immunocompromised Pediatric Patient with MRSA Pneumonia	2:30PM - 3:15PM

## RESEARCH DAY AGENDA

91	Stephanie Van Meter	Resveratrol Protects Renal Tissue from Reactive Oxygen Species (ROS) Cytotoxicity	2:30PM - 3:15PM
92	Majd Kanbour	Stage IV melanoma with unknown primary with small bowel and lung involvement discovered through capsule enteroscopy	2:30PM - 3:15PM
93	Susan Touma	Giant Cell Foreign Body Injection Site Reaction to Interferon Beta 1b	2:30PM - 3:15PM
94	Elke Fähmann	Hypoglycemia in the Diabetes Control and Complication Trial (DCCT) and the Epidemiology of Diabetes Interventions and Complications (EDIC) Trial: What is the story with vascular disease?	2:30PM - 3:15PM
95	Ryan Stone	Retrospective analysis of Hepatitis C transmission rates between vaginal and cesarean deliveries	2:30PM - 3:15PM
96	Mohammed AL-Ourani	Liver Abscesses caused by Streptococcus Constellatus	2:30PM - 3:15PM
97	Bi Mo	A Case of Epidural Hematoma and Kaposiform Lymphangiomatosis	2:30PM - 3:15PM
98	Audra Pritt	Assessment of Nurse Satisfaction with Bedside Nurse Presence at Family Centered Rounds	2:30PM - 3:15PM

**RESEARCH DAY AWARDS PRESENTATION - Harless Auditorium**

**4:30PM**



**ORAL SESSION I • 8:30 AM – 9:30 AM**

# **25TH ANNUAL RESEARCH DAY ORAL SESSION**

## **Where can orthopaedic hardware safely be placed for syndesmosis fixation: An anatomic study**

Franklin D. Shuler, Daniel Woods,  
Zach Tankersley, Clint McDaniel, Jacob Hamm,  
Justin Jones, and James Denvir

Department of Orthopaedic Surgery, Department of Biostatistics,  
Marshall University

The syndesmosis is a complex, multi-component bone and ligamentous structure at the lateral ankle that links the fibula to the tibia. Injuries to the syndesmosis commonly occur with ankle fractures and ankle sprains. For unstable injuries, surgical fixation (screws or suture devices) link the fibula back to the tibia. Previous cadaveric studies defined borders for key anatomical structures but are not sufficiently powered to make definitive statements directing optimal placement of surgical fixation.

This study generated the highest powered data set in the literature by reviewing 3158 anatomical and cadaveric specimens measuring the tibio-fibular cartilage contact zone (TFCCZ) and the syndesmotic recess. Defining these structures is critical to maximize biomechanical stability following surgical syndesmotic fixation while decreasing the risk of iatrogenic injury.

Phase I (n=3133): The Smithsonian Robert J. Terry anatomical collection was used with right and left tibia measured for height of the TFCCZ and syndesmotic recess using calibrated calipers accurate to 0.02mm. Phase II used cadaveric dissection of 25 specimens to obtain identical measurements.

A measurable TFCCZ (> 2mm) was present in 59% of the anatomical specimens and the table summarized our findings.

TFCCZ height (mm)    Syndesmotic recess height (mm)

Anatomical specimens (n=3133)	5.7 mm ± 1.7 mm	12.8 mm ± 2.1 mm
Cadaveric specimens (n=25)	5.6 mm ± 1.6 mm	13.7 mm ± 2.7 mm

This study defines the TFCCZ and syndesmosis recess height with statistical validation of the use of anatomical specimens as a proxy for expensive cadaveric dissections. Standardization of surgical protocols can now occur directing the optimal placement of surgical fixation.



## **Cost-Savings Analysis of Telemedicine Use for Ophthalmic Screening in a Rural Appalachian Health Clinic**

Russ Richardson, Russell Fry, Michael Krasnow

University Eye Surgeons

Living in a mountainous rural area poses unique obstacles for healthcare delivery, especially in areas of specialization such as ophthalmology. Two of the most important obstacles are a lack of access to specialists and the cost of care. Theoretically, using telemedicine as a screening tool addresses both problems. Telemedicine screenings have been determined to be both sensitive and specific for diabetic eye disease (Germain et al 2011), a major problem in the area's patient population. The American Diabetes Association places a Grade E recommendation on fundus photography as a screening tool (Diabetes Care 2012).

Here, we analyze the financial impact of ophthalmic telemedicine in a mountainous, rural, health clinic in southern West Virginia over a seven year period. At-risk patients are screened with a fundus camera during routine clinic visits and the image is read by an off-site ophthalmologist. If no pathology is observed, the patients return for screening in one year. This spares patients from traveling to the nearest ophthalmologist one hour away.

When considering the number of patients seen, travel costs, work missed, and billing consideration, we estimate a savings of over \$73,139, even after subtracting the \$21,990 for the cost of the fundus camera. The savings averages \$157 per patient, with a greater savings possible if more patients at risk are screened first before being referred to an ophthalmologist.

Therefore, from a purely economic standpoint, ophthalmic telemedicine screenings are justified in this circumstance.

## **The Effect of Passive Smoking On Hemoglobin Level During The First 2 Years of Life**

Alabd Alrazzak B, Katerji B, Lochow A

Pediatric, Marshall University

The smoking ratio in adults in WV is more than 26% as reported by the CDC. This high rate puts our children at higher risk to develop many medical problems including OM, SIDS etc. The effect of passive smoking on hemoglobin in the pediatric population is not studied well. In this study we tried to detect the effect of passive smoking on Hb levels in children in our community.

Retrospective chart review for children between 9 months and 2 years of age, who were seen at Marshall University, were reviewed. As recommended by American Academy of Pediatrics, Hb level was checked in the majority of those children. Data about gender, PMH, age, Hb levels and passive smoking exposure were collected; patients were divided into two groups regarding their passive smoking exposure. T test was used to compare the mean of Hb levels in both groups.

A total of 850 charts were reviewed; only 368 met the criteria for the study. Patients were divided into two groups regarding their passive smoking exposure. 184 patients were found in each group. The mean Hb level and SD were compared in both groups and were as follows:

- Group 1 with passive smoking exposure: Hb Mean: 12.05/ SD: 1.243.
  - Group 2 with no passive smoking exposure: Hb Mean: 12.10/ SD: 1.297.
- T test was used to compare the two means and was 0.348 with DF 366. P value: 0.727 and is statistically not significant

Even passive smoking has remarkable side effects in children, particularly during the first few years of life; however it has no significant effect on the hemoglobin levels compared to children with no passive smoking exposure.

## **Eicosapentaenoic Acid and Docosahexaenoic Acid as Potential Chemo-sensitizing Agents for the Treatment of Chronic Lymphocytic Leukemia**

Johannes F. Fahrman, W. Elaine Hardman

Department of Biochemistry and Microbiology,  
Marshall University School of Medicine

Clinical treatment of B-cell Chronic Lymphocytic Leukemia (CLL) is often limited due to drug resistance and severe therapy-induced toxicities. The primary purpose of the current study is to determine if omega 3 fatty acids (n-3), eicosapentaenoic acid (EPA) and/ or docosahexaenoic acid (DHA) could sensitize malignant B-lymphocytes to vincristine or fludarabine in vitro in B-CLL-like leukemic cell lines EHEB, JVM-2 and MEC-2 and from patients who 1) have a white blood cell count =  $17 (10^3/\mu\text{L})$  and are therapy naïve, 2) progressed to symptomatic CLL and require therapy but are therapy naïve or 3) have relapsed with refractory CLL post standard clinical treatment of CLL.

IRB protocol was written and approved (ID: 346687-2). Patients are currently being recruited into the study. B-CLL-like leukemia cell lines EHEB, JVM-2 and MEC-2 were tested for their in vitro sensitivity against vincristine or fludarabine in the presence of vehicle (no fatty acid (FA)), omega 6 FA arachidonic acid (AA), EPA or DHA. Cell lines were treated for 72 hours with vehicle, AA, EPA or DHA. Following 72 hour pre-treatment, cells were treated for 24 hours with vincristine (0-250nM) or fludarabine (0-50 $\mu\text{M}$ ). Cell viability was determined using MTT assay. Apoptosis was measured using annexin-V assay.

N-3 differentially sensitized EHEB, JVM-2 and MEC-2 to vincristine and fludarabine in vitro. Treatment with DHA alone induced significant cell death in all three cell lines. DHA pre-treated cells treated with vincristine (JVM-2 and MEC-2) or fludarabine (EHEB) indicated significantly greater cell death as compared to cells pre-treated with vehicle.

Our results indicate that n-3 increases the in vitro sensitivity of B-CLL-like cell lines to vincristine and fludarabine. We want to determine if similar responses will be seen in our patient samples. N-3 provides a promising non-toxic chemo-sensitizing agent for the treatment of CLL and warrants further investigation.

## **Live lecture vs. online module for teaching musculoskeletal exam skills**

Jay Bronder, Meaghan Tranovich, Joe Russo,  
Beatrice Grasu, Felix Cheung MD

Department of Orthopaedic Surgery,  
Joan C. Edwards School of Medicine

As the accessibility and functionality of new forms of technology continue to increase, many medical schools have begun to utilize online modules to deliver educational content to students. However, it is unclear whether traditional lecture or online content is more effective in teaching first and second year medical students. Online modules are thought to be a more effective way to present information due to their interactive nature.

In order to test this hypothesis, twenty-three medical student volunteers were randomly assigned to either attend a live lecture given by a member of the orthopedics faculty or complete an online module on the musculoskeletal exam of the shoulder. The module and lecture contained identical information and utilized the same set of Powerpoint slides. Effectiveness of the two methods was tested using a 15 question pretest and a 14 question posttest. The data was analyzed using a paired student T test, and individual improvement was compared to the average group improvement.

No significant difference was seen between the pretest and posttest scores of either group, although there was a positive trend. The mean change in scores from pre- to posttest in the lecture group was 4.5% with a standard deviation of 16.89% while the mean change for the module group was 9.48% with a standard deviation of 22.28%. This gave P values of .397 and .168 for the lecture and module groups, respectively.

Using these statistical analyses, it was seen that overall improvement was similar between groups. Live lecture and online modules are equally effective in teaching musculoskeletal exam of the shoulder to medical students. Achieved power of the study was calculated to be 0.51. The 4.5% change versus 9.5% change in scores would have been statistically significant with 22 or more subjects in each group. Thus, future studies should include more participants.

## **Inhibition of cholinergic signaling causes apoptosis in human bronchioalveolar carcinoma**

Jamie K. Lau, Kathleen C. Brown, Brent A. Thornhill,  
Clayton M. Crabtree, Aaron M. Dom, Theodore R. Witte, W. Elaine

Hardman, Christopher A. McNees, Cody A. Stover,  
A. Betts Carpenter, Haitao Luo, Yi C. Chen, Brandon S. Shiflett,  
and Piyali Dasgupta

Department of Pharmacology, Physiology, and Toxicology,  
Department of Biochemistry and Microbiology, Department of  
Anatomy and Pathology, Joan C. Edwards School of Medicine,  
Marshall University, Huntington, WV, Department of Biology,  
Alderson-Broadus College, Philippi, WV

Clinical studies show that bronchioalveolar carcinomas (BACs) are correlated with smoking. Nicotine, the addictive component of cigarettes, accelerates cell proliferation through nicotinic acetylcholine receptors (nAChRs). The endogenous ligand of nAChRs is acetylcholine (ACh). Small cell lung cancers (SCLCs) and squamous cell lung cancers have been shown to synthesize, transport and degrade ACh. The existence of the ACh-signaling pathway has not been studied in human BACs. Additionally, there are no reports of how nicotine regulates the ACh-signaling axis in human BACs.

The levels of ACh in human BACs were studied by enzymatic assays. The expression of acetylcholinesterase (AChE), choline acetyltransferase (ChAT), choline transporter 1 (CHT1), vesicular acetylcholine transporter (VACHT), and nAChRs were measured by western blotting, immunohistochemistry and ELISA. The proliferative effects of ACh were measured by BrdU assays. The growth-inhibitory activity of vesamicol was measured by TUNEL and caspase-3 activity assays in BAC cell lines. The anti-tumor effect of vesamicol was measured in vivo by athymic mice models and CAM models. The signaling pathways underlying vesamicol-induced apoptosis were measured by siRNA-methodology.

Human BACs produce ACh and contain cholinergic system proteins. Nicotine increases the production of ACh, which acts as a growth factor for human BACs. Nicotine-induced ACh production is mediated by  $\alpha 7$ -,  $\alpha 3\beta 2$ -, and  $\beta 3$ -nAChRs, ChAT and VACHT pathways. We observed that nicotine upregulates VACHT. VACHT antagonists, such as vesamicol, induced apoptosis of human BACs

in cell culture and athymic mice models. We also observed that vesamicol caused cell death by inhibiting Akt phosphorylation.

Our data shows that disruption of nicotine-induced cholinergic signaling by agents such as vesamicol may have applications in BAC therapy.



**ORAL SESSION II • 10:30 AM – 11:30 AM**

# **25TH ANNUAL RESEARCH DAY ORAL SESSION**

# **Sandwich-type Nanofiber Scaffolds with Square Arrayed Wells and Structured Cues for Skin Regeneration Applications**

Bing Ma, Jingwei Xie

Marshall Institute for Interdisciplinary Research and  
Center for Diagnostic Nanosystems,  
Marshall University, Huntington, WV 25755 USA

Around 450,000 burn injuries are treated in hospital annually in the United States. Split-thickness skin graft is still the gold standard for burn wound closure. Although the expansion ratio of MEEK technique for skin graft can reach up to 9 times, the main disadvantages are that the skin pieces have to be larger than 3 mm × 3 mm and oriented with the dermal side down. Importantly, nanotopographic cues have not been used to bridge the skin islands. Nanofiber scaffolds with microwells and structural cues could provide an ideal solution as they can confine the transplanted microskins (<1 mm × 1 mm) without the necessity of considering the orientation of transplanted skin pieces and can simultaneously direct and promote cell migration.

1. Fabrication of sandwich-type scaffolds consisting of radially aligned nanofibers at the bottom, microskin tissues in the middle, and nanofiber membranes with square arrayed microwells and nanostructured cues at the top.
  2. NIH 3T3 fibroblasts and primary rat skin cells culture on sandwich-type scaffolds.
  3. Implantation of sandwich-type scaffolds to wound in a rat wound healing model.
- 
1. We demonstrated the fabrication of novel nanofiber scaffolds with controllable microwells and structural cues.
  2. The scaffolds can guide and facilitate the migration of the cultured NIH 3T3 fibroblasts and primary rat skin cells in vitro.
  3. The scaffolds with 3 mm distance between microwells enhanced transplanted microskins (1 mm diameter) 'take' rate without the necessity of considering the orientation of dermal side and accelerated re-epithelialization on wound in vivo.

By controlling the size of microskin and the distance between the microskins, various expansion ratios ranging from 9 to 324 can be achieved using the scaffolds developed in this study. Taken together, the sandwich-type nanofiber scaffolds show great potential as microskin grafts for the treatment of burn wounds.



## **Anterior Cruciate Ligament (ACL) Reconstruction Outcomes in Obese Patients**

Michael James Chambers, Tigran Garabekyan,  
Stephanie F Zimmeck, John Jasko, Charles E. Giangarra

Marshall University Orthopaedics, Marshall University

There is a paucity of data describing anterior cruciate ligament (ACL) injury and reconstruction in the obese patient population, with a bias toward non-operative treatment. Previous research indicates that obese patients may require reconstruction to prevent recurrent instability. The purpose of this study was to characterize the outcomes of ACL reconstruction in obese patients.

We conducted a retrospective cohort analysis of 131 patients with an ACL injury treated with ACL reconstruction at a single university-affiliated hospital from 2007 to 2011. Thirty-two obese patients (BMI greater than or equal to 30) were identified (Group 1) and compared with 99 non-obese control patients (Group 2). Instability after reconstruction and complications after ACL reconstruction were analyzed.

The mean BMI was 35 (range 30 – 54) in Group 1 vs 24 (range 16 – 29) in Group 2. Postoperatively, all patients had a negative Lockman and pivot shift test. Complications in the obese group included three patients with arthrofibrosis. In the non-obese group, there were two patients with arthrofibrosis, five with graft ruptures, three with hardware issues, and two with cellulitis postoperatively. There was no significant difference between the 2 groups in regards to significant complications ( $p=0.7599$ ) and in regards to graft ruptures ( $p=0.3338$ ).

Anterior cruciate ligament injury in obese patients is as successful in preventing post operative instability as in the non-obese population. There was no increase in post operative complications after ACL reconstruction in the obese population, which is in contrast to other orthopaedic surgeries where obesity is related to increased post operative complications.

## **Assessment of The Efficacy of Two Protocols used for Radio Active Iodine (RAI) Treatment of Thyroid Cancer**

Randa Aljayoussi, Ronald Stanek and Abid Yaqub

Section of Endocrinology, Department of Internal Medicine, Joan C. Edwards School of Medicine Marshall University, Huntington, WV.

Two thyroid hormone withdrawal protocols are used in our center to treat patients with thyroid cancer with Radioactive Iodine (RAI-131) with the aim of maintaining maximal RAI uptake by keeping TSH level  $> 30$  ng/dl. The old prolonged RAI protocol utilizes a longer duration of levothyroxine withdrawal time (28 days), which prolongs the patient hypothyroid state resulting in undesired effects on quality of life(QOL). The new shortened protocol has a net decrease in withdrawal time of 6 days. Aim of our study was to find out if the new shortened protocol can also result in the comparable TSH elevation necessary for successful RAI-131 ablation.

We retrospectively reviewed the charts of 20 patients in the old prolonged protocol and compared it with 17 patients in the new shortened protocol. We measured TSH, FT4, and thyroglobulin levels at day #36 of the two withdrawal protocols. Mann-Whitney Rank Sum test was used to compare Median, 25% and 75% TSH levels between the two protocols.

All patients in both groups achieved adequate TSH stimulation of  $> 30$  ng/dl. Median, 25 % and 75% levels were 79.1, 59.2 and 98 ng/dl in the old prolonged protocol and 86.1, 54.6 and 111 respectively in the new shortened protocol. There was no statistically significant difference between the 2 protocols( P value of 0.703).

Shortening the time of hypothyroid state in the withdrawal protocol for RAI-131 in thyroid cancer patients had no effect on stimulated TSH levels but may have significant impact on patients' quality of life.

## **Targeting a newly established spontaneous feline fibrosarcoma cell line by gene transfer.**

Rounak Nande(1), Jim Denvir(1), Jagan Valluri(2), Gary C. Duncan(3), and Pier Paolo Claudio (1,4).

1. Department of Biochemistry and Microbiology, Joan C. Edwards School of Medicine, McKown Translational Genomic Research Laboratory, Marshall University, 2. Department of Biological Sciences, Marshall University, Huntington, 3. Martin Veterinary Clinic, Ashland, KY, 4. Department of Surgery, Joan C. Edwards School of Medicine, Marshall University, Huntington.

Fibrosarcoma is a deadly disease in cats and is significantly more often located at classical vaccine injections sites. More rare forms of spontaneous non-vaccination site (NSV) fibrosarcomas have been described and have been found associated to genetic alterations. Purpose of this study was to compare the efficacy of adenoviral gene transfer in NVS fibrosarcoma.

We isolated and characterized a NVS fibrosarcoma cell line (Cocca-6A) from a spontaneous fibrosarcoma that occurred in a domestic calico cat. The feline cells were karyotyped and their chromosome number was counted using a Giemsa staining. Adenoviral gene transfer was verified by western blot analysis. Flow cytometry assay and Annexin-V were used to study cell-cycle changes and cell death of transduced cells. Cocca-6A fibrosarcoma cells were morphologically and cytogenetically characterized.

Giemsa block staining of metaphase spreads of the Cocca-6A cells showed deletion of one of the E1 chromosomes, where feline p53 maps. Semi-quantitative PCR demonstrated reduction of p53 genomic DNA in the Cocca-6A cells. Adenoviral gene transfer determined a remarkable effect on the viability and growth of the Cocca-6A cells following single transduction with adenoviruses carrying Mda-7/IL-24 or IFN- $\gamma$  or various combination of RB/p105, Ras-DN, IFN- $\gamma$ , and Mda-7 gene transfer.

We identified the combinational use of Ad.RasDN, Ad.RB and CTV Mda7/IL-24 as a possible future adjuvant treatment. Therapy for feline fibrosarcomas is often insufficient for long lasting tumor eradication. More gene transfer studies should be conducted in order to understand if these viral vectors could be applicable regardless the origin (spontaneous vs. vaccine induced) of feline fibrosarcomas.

## **MicroRNA Regulation of Adipose Derived Stem Cells.**

Holly L. Tamski, Jia Fei, Carla Cook and Nalini Santanam

Pharmacology, Physiology & Toxicology, Joan C Edwards School of  
Medicine, Marshall University

Adipose tissue is a key player in lipid and glucose metabolism. Dysregulation of abdominal fat secreted adipokines increases risk to metabolic syndrome. Adipose dysfunction also occurs during the aging process, probably due to alterations in the preadipocytes (aka. stromal vascular fraction cells- SVF cells or adipose derived stem cells-ASCs) composition and/or function. Since microRNAs regulate genes involved both in development and aging processes, we hypothesized that the impaired adipose function with aging is due to impaired microRNA regulation of adipogenic pathways in SVF cells.

Adipose derived stem cells were isolated from visceral fat obtained from 6 mo and 30 mo old female Fischer 344 x Brown Norway Hybrid (FBN) rats. Stem cell phenotype was confirmed using fluorescence immunostaining and flow cytometry. Stem cells were differentiated using adipogenic or osteogenic media into adipocytes or osteocytes. MiRNA-143 and miR-204 levels were determined in cells before and after differentiation using MirVana primers by quantitative PCR.

Alterations in mRNA and proteins associated with adipogenic differentiation (MAP kinase- ERK5 and peroxisome proliferator activated receptor ? -PPAR?) but not osteogenic (Runt-related transcription factor 2-RUNX2) pathways were observed in SVF cells isolated from visceral adipose tissue with aging (6 to 30mo) in female Fischer 344 x Brown Norway Hybrid (FBN) rats. The impaired differentiation capacity with aging correlated with altered levels of miRNAs involved in adipocyte differentiation (miRNA-143) and osteogenic pathways (miRNA-204).

Our studies indicate a role for miRNA mediated regulation of SVF cells with aging. This discovery is important in the light of the findings that dysfunctional adipose derived stem cells contribute to age related chronic diseases.



**ORAL SESSION III • 1:15 PM – 2:15 PM**

**25TH ANNUAL  
RESEARCH DAY  
ORAL SESSION**

## **Protein Carbonylation in Regulation of Renal Proximal Tubular Na/K-ATPase signaling and Sodium Transport**

Yanling Yan, Joseph I. Shapiro, and Jiang Liu

Department of Pharmacology, Physiology and Toxicology, Joan C. Edwards School of Medicine

We have shown that cardiotonic steroids signaling through the Na/K-ATPase inhibit sodium reabsorption in renal proximal tubules (RPTs) and impairment of the Na/K-ATPase signaling contributes to salt sensitivity and salt-sensitive hypertension. Here we report that reactive oxygen species (ROS) are critical in modulation of Na/K-ATPase signaling and RPT ion transport.

(1) In porcine RPT LLC-PK1 cells, both ouabain (100nM) and glucose oxidase (GO, 3mU/ml, as positive control) stimulate direct carbonylation of two highly conserved and exposed amino acid residues (Pro222 and Thr224, (AT1A1\_PIG)) in the actuator (A) domain of the Na/K-ATPase  $\alpha$ 1 subunit. Immunoprecipitation studies indicated that both ouabain and GO caused protein carbonylation of Na/K-ATPase  $\alpha$ 1 subunit, NHE3 and c-Src. (2) The Na/K-ATPase/c-Src signaling is redox-sensitive. Pre-treatment with NAC or disruption of the Na/K-ATPase/c-Src signaling prevented ouabain-stimulated Na/K-ATPase signaling, protein carbonylation and subsequent regulation of the Na/K-ATPase and NHE3; (3) The Na/K-ATPase/c-Src complex might function as a receptor of ROS signaling. Disruption of the Na/K-ATPase/c-Src complex significantly attenuated GO-induced redistribution of the Na/K-ATPase and NHE3 and inhibition of  $^{22}\text{Na}^+$  flux; (4) Protein carbonylation stimulated by ouabain is reversible, evaluated in the presence of protein biosynthesis inhibitor cycloheximide, proteasome inhibitor MG132, and lysosomotropic weak base agent chloroquine. This observation argues that carbonylation modification might be an unidentified regulatory mechanism of the Na/K-ATPase/c-Src signaling; (5) In RPTs freshly isolated from Dahl salt-sensitive (S) and salt-resistant (R) rats, the S rat RPTs have a much higher basal protein carbonylation level than that in the R rats. Specifically, a high salt diet or ouabain stimulated protein carbonylation in the R but not S rats.

ROS/protein carbonylation is involved in a feed-forward mechanism in regulation of RPT Na/K-ATPase/c-Src signaling and  $^{22}\text{Na}^+$  flux. The data also suggested that the Na/K-ATPase/c-Src signaling complex might be a functional receptor of ROS.

## **Benzyl isothiocyanate enhances chemotherapy and reduces migration and invasion of head and neck squamous carcinoma cells**

M. Allison Wolf and Pier Paolo Claudio

Department of Biochemistry and Microbiology, Joan C. Edwards School of Medicine, Huntington, WV

Approximately 500,000 cases of head and neck squamous cell carcinoma (HNSCC) are reported worldwide each year. Despite recent improvements in cancer treatment, the increase in overall survival of advanced HNSCC has not improved in the past 3 decades. Consequently, our objective is to find new therapeutic options to enhance survival of patients with aggressive HNSCC. Benzyl isothiocyanate (BITC), a natural compound found in cruciferous vegetables, is showing promising results in targeting chemoresistant and metastatic HNSCC cells.

Cell viability after BITC, cisplatin, and BITC followed by cisplatin treatment was determined using a standard MTT assay. Changes in HNSCC migration were investigated using a wound-healing assay. Boyden Chambers were used to study changes in HNSCC cell invasion after BITC treatment. Immunofluorescence and Western blots were used to determine changes in expression of vimentin, E-cadherin, and ALDH1.

Our current data suggests that BITC enhanced the sensitivity of HNSCC cell lines to cisplatin after 24 and 48 hours. A wound healing assay indicated that the migration of metastatic HNSCC cell lines was inhibited by BITC in a dose dependent manner. Additionally, an invasion assay showed that BITC significantly inhibited HNSCC cell invasion towards the chemoattractant EGF after 20 hrs. Immunofluorescence and Western blot analysis suggest that, in the HN12 cell line, BITC significantly inhibited the expression of the epithelial-mesenchymal transition marker, vimentin, and putative cancer stem cell marker, ALDH1, while increasing the expression of cell-cell adhesion molecule, E-cadherin.

The present results suggest that a food component such as BITC may enhance the effect of chemotherapy, while also reducing migration and invasion of aggressive HNSCC cells. This suggests that BITC could be a novel adjuvant treatment for patients with aggressive HNSCC.

## **Documentation of Endotracheal Tube Position Confirmation Among Different Emergency Department Providers**

Michael P. Phelan, Fredric Hustey, Maureen Joyce, Stefanie Schrupp, Joseph Konwinski, David Yin

Cleveland Clinic, Cleveland, OH, Cleveland Clinic Lerner Institute, Cleveland, OH, MetroHealth/Cleveland Clinic, Cleveland, OH, Metrohealth/Cleveland Clinic, Cleveland, OH

The objective of this study was to assess the prevalence of appropriate documentation of endotracheal tube (ET) position confirmation in intubated emergency department (ED) patients among ED health care providers.

Inclusions: all patients in the ED of a tertiary center undergoing ET placement in the ED or arriving with an ET placed in an outside setting. Standardized forms were used to prospectively capture all intubated patients and the medical records were reviewed using a standardized audit form. Appropriate documentation of endotracheal tube (ET) position confirmation was defined according to American College of Emergency Physician (ACEP)'s recommended methods: end-tidal CO<sub>2</sub> detection, re-evaluation with direct laryngoscopy, or an esophageal detection device (EDD).

344/346 patients in the registry undergoing intubation between March 1, 2010 and June 30th, 2011 had complete data and were included. 116 were intubated prior to ED arrival and the remaining 228 were intubated in the study site ED. 9 of 344 (2.6%; 95%CI, 1-5%) had no documentation of confirmation by any provider. Overall documentation rates for confirmation of ET tube placement were 76.7% (264/344) for physicians, 91.0% (312/344) for respiratory therapists (RT) and 53.8% (185/344) for nurses. Documentation rates were highest across provider types for patients intubated in the ED compared to those intubated in an outside setting. Physicians and nurses were less likely to document ET position confirmation in patients intubated in an OSH as opposed to those intubated by EMS (31% vs. 50%,  $p=.0567$  and 21% vs 47%,  $p=.0057$ ).

Documentation of ET position confirmation for patients intubated at outside hospitals is low across the disciplines. Providers are less likely to document ET position confirmation for patients arriving to the ED with an ET tube already in place. Opportunities exist to improve documentation of confirmation of tube position across health care providers.



## **How does the TEI indice correlate with bile acid levels in women with intrahepatic cholestasis of pregnancy?**

Kelly Cummings, Ryan Stone, David Chaffin

Department of OBGYN, Joan C. Edwards School of Medicine

Intrahepatic cholestasis of pregnancy, ICP, is a disease characterized by elevated bile acids and pruritus. Pregnancies complicated by ICP are at risk of intrauterine fetal demise. The mechanism of fetal death in ICP is unknown, but alterations in fetal cardiac conduction or cardiac contractility have been proposed to contribute to fetal demise. Currently, fetal cardiac function is not monitored as a part of the standard of care. The Tei index is an ultrasound technique that measures global cardiac function. The purpose of this study was to determine if the left ventricular Tei index changed in pregnancies affected by ICP, and if these differences correlated with the level of bile acids.

Doppler waveforms of the LV outflow tracts were obtained in 11 2nd and 3rd trimester fetuses of mothers who carried the diagnosis of ICP. The LV isovolumic contraction time (ICT), isovolumic relaxation time (IRT), and ejection time (ET) were measured and the Tei index calculated using the formula  $(ICT+IRT)/ET$ . Fasting serum bile acid levels were obtained prior to making the diagnosis of ICP, and at multiple points throughout the course of each pregnancy.

The Tei indices of patients with ICP were elevated (mean  $0.46 \pm 0.12$ ,  $p < 0.0001$ ) compared to the Tei indices of normal second and third trimester fetuses ( $0.34 \pm 0.07$ ). The Tei indices do not correlate directly with the degree of bile acid elevation.

Maternal bile acid levels do not correlate with the fetal Tei indices, so bile acid levels are not predictive of deteriorating fetal cardiac function in patients with ICP. The Tei index in patients with ICP is significantly elevated compared to the normal Tei indices established by Mori (2001). In patients with ICP the Tei index should be incorporated into the antenatal fetal surveillance.

## **Tic Disorders and Functional Constipation as Complicating Conditions in Children Presenting for Evaluation for Attention Deficit Hyperactivity Disorder (ADHD).**

Kelli Brown, James Lewis, Yoram Elitsur

Department of Pediatrics, Joan C. Edwards School of Medicine,  
Huntington, WV

**Background:** ADHD, the most pediatric common mental health problem, is often associated with other disorders of learning and behavior including dyslexia and anxiety. There is little data, however, on the coexistence of other potentially severe medical conditions such as tic disorders, Tourette syndrome and encopresis in children and adolescents with ADHD.

**Objective:** To determine the incidence and characteristics of tic disorders and functional constipation in pediatric patients with ADHD.

**Methods:** From June 2010 to May 2012 all parents of pediatric patients referred to the Marshall University Department of Pediatrics ADHD Center were asked to complete a survey on the presence of tics and symptoms of functional constipation in their child. The questions were based on the requirement of at least 2 Rome III diagnostic criteria for encopresis and the DSM IV diagnostic criteria for tic disorders.

**Results:** The survey population included 252 patients with 76 % male (M) and a mean age (MA) of 8 years. The diagnostic criteria for tic disorder were met in 103 patients (41%) with 87% M and MA of 9 years. Tourette syndrome with vocal and motor tics present for greater than one year was described in 32 patients (12%). Functional constipation was present in 56 patients (22%) with 80% M and MA of 8.5 years. The combined group with both constipation and tic disorder numbered 30 (12%) with 83% M and MA of 8 years. Age and gender differences were not statistically significant by Chi square analysis

**Conclusions:** Both functional constipation and tics disorder are common coexisting conditions in pediatric patients with ADHD and should be addressed in the evaluation and treatment protocols.



**ORAL SESSION IV • 3:15 PM - 4:30 PM**

# **25TH ANNUAL RESEARCH DAY POSTER SESSION**

## **Clinical Features of Congestive Heart Failure Related Pleural Effusions by Echocardiographic Classification of Ventricular Dysfunction**

Ghada Mesleh, Todd Gress, Shadi Obeidat, Nancy Munn,  
Abdullrahman Hammo, Paulett Wehner, Fuad Zeid

Pulmonary Medicine, M.U.S.O.M.

Congestive heart failure is the most common cause of pleural effusions. We examined clinical, laboratory and radiologic features of congestive heart failure patients with pleural effusions by echocardiographic classification of ventricular dysfunction.

Retrospectively evaluated 60 patients with pleural effusions and a diagnosis of uncomplicated Congestive heart failure. Cardiologist blinded to diagnosis classified echocardiograms as: Group 1 (G1) systolic (ejection fraction <50%); Group 2 (G2) diastolic (EF = 50% with abnormal diastolic function) or Group 3 (G3) combined systolic and diastolic (EF <50% with diastolic dysfunction). Excluded five patients with normal echocardiograms . We recorded pleural fluid chemistry, cell counts, brain natriuretic peptide (BNP), and laterality, and effusions were classified as exudative or transudative by the Light criteria. Patients followed for six months after index hospitalization to assess for readmission.

15 patients had isolated systolic dysfunction (G1), 26 patients had isolated diastolic dysfunction (G2), and 14 patients had combined systolic and diastolic dysfunction (G3). Mean age was similar for all three CHF groups (overall mean 74.7 years, sd 10.5), but more women had isolated diastolic dysfunction (18.5% G1, 70.9% G2, and 11.1% G3;  $p=0.003$ ). As expected, median BNP was significantly higher for systolic dysfunction (9188 pg/mL G1, 1214 pg/mL G2, 5962.5 pg/mL G3 ;  $p=0.01$ ). No significant difference in pleural fluid chemistry, cell counts, laterality and Light criteria classification between the three groups (86.7% G1, 80.0% G2, and 85.7% G3 were transudative;  $p=0.90$ ). Overall, 57.1 percent of patients were readmitted with higher rates of readmission in groups 2 and 3 (33.3% G1, 61.5% G2, 78.6% G3;  $p=0.05$ ).

No significant differences found in clinical features of pleural effusions by type of ventricular dysfunction . Patients with isolated diastolic or diastolic with systolic dysfunction experienced higher rates of re-admission than systolic dysfunction alone, suggesting those with diastolic dysfunction may need closer outpatient follow-up.

## **Teaching the Millennial Student: How well have the Baby Boomer /Generation X teachers adapted in an Academic Orthopaedic Department?**

Franklin D. Shuler, Ali Oliashirazi, Felix Cheung,  
Thomas Riley, Ilia Iliev, Darshana Shah

Department of Orthopaedic Surgery and JCESOM,  
Marshall University

Just like people, generations have personalities. Members of the Millennial Generation (1981-2001) fill our medical school and residency programs. This group is “optimistic, self-confident, collaborative and team-oriented, technologically savvy and interested in improving their communities.” Millennials feel distinctive and exceptional because of their use of technology and its incorporation into their daily social interactions with a smartphone considered more important than a stethoscope or medical library. The traits and values of the Millennial group are generally different from those responsible for their matriculation through the medical education process including the Baby Boomers (1946-1964) and members of Generation X (1965-1980). Understanding and optimizing medical curriculum to account for these traits and characteristics are at the forefront of current medical education reform.

Validated 10 question online surveys (PEW Research Center) were used to assess the understanding of generational differences of academic orthopaedic faculty members and see if they have effectively optimized teaching methods.

The survey group included 8% Millennial faculty; 33% Baby Boomer faculty; and 59% faculty from Generation X. Data included the following: 83% have not had training on teaching Millennial learners; 67% did not identify teamwork as an important trait and characteristic for this group; 25% integrated technology beyond powerpoint into didactic teaching; 42% felt that no benefit would come from computer-based teaching environments with 58% feeling that the current generation has less value on work ethic.

Generational differences impact the Orthopaedic Resident and medical student learning process. In meeting the challenges of teaching across generations, we need to do a better job of making the faculty understand the Millennial Generation as well as providing them guidance for using more effective tools in passing on their knowledge to this technology savvy and collaborative learning generation.

## **Resveratrol suppresses lipogenesis, growth and viability of pancreatic and breast cancer stem-like cells.**

Sarah E. Mathis, Matthew Baker, Richard Egleton, James Weinstein, Jagan V. Valluri, and Pier Paolo Claudio

McKown Translational Genomic Research Institute, Department of Biochemistry and Microbiology, Department of Physiology and Toxicology, Department of Neuroscience, Department of Biology, Department of Surgery, Marshall University, Huntington, WV 25701.

Resveratrol is a multi-functional natural polyphenolic compound which elicits cardio-protective as well as anti-neoplastic effects on various types of cancers. Its chemo-preventative as well as chemo-therapeutic effects against various types of cancers in pre-clinical testing has been well documented, although the actual efficacy in patients is yet to be determined and several clinical trials are currently underway (NCT00721877, NCT00920803, NCT00433576, and NCT00578396). Resveratrol has strong anti-oxidant activity, and is also capable of inducing apoptosis in cancer cells, and therefore, it is believed to be efficacious at multiple stages of carcinogenesis. However, the exact mechanism of its anti-tumor effect is not clearly defined.

Recently resveratrol has been shown to elicit strong hypolipidemic effect on normal adipocytes and since hyper-lipogenesis is a hallmark of cancer cell physiology, we screened the effect of resveratrol on lipid synthesis and growth of bulk of tumor and cancer stem-like cells (CSLCs) that were isolated from a panel of colon, pancreas, breast, prostate, brain, head & neck, and lung cancer cell lines.

Here we describe a unique action of resveratrol by which it modulates fatty acid synthase (FAS) expression and lipid synthesis in CSLCs, and thus resulting in the induction of apoptosis, which can be significantly blocked by specific inhibitors of the synthesis of fatty acids (TOFA and Fumonisin B1), further indicating that the pro-apoptotic effect of resveratrol in CSLCs is a direct consequence of the ability of resveratrol to down-regulate FAS. We also found that resveratrol significantly reduced the cell viability and sphere formation followed by induction of apoptosis in mammary and pancreatic CSLCs.

Taken together, our results indicate that resveratrol is capable of inducing apoptosis through suppression of lipogenesis by modulating FAS expression, which highlights a novel mechanism of anti-tumor effect of resveratrol in CSLCs isolated from breast and pancreatic cancer cell lines.

## **Aryl Hydrocarbon Signaling Inhibits Mitogenic Adipokine Signaling in Breast Cancer Cells**

Justin K. Tomblin, Gary Z. Morris, Ateeq R. Chaudhry,  
Travis B. Salisbury

Department of Pharmacology, Physiology, & Toxicology, Joan C. Edwards School of Medicine, Huntington, WV.

High rates of obesity have been shown to increase breast cancer risk, increase breast cancer recurrence and increase breast cancer mortality in humans. In breast cancer cells, adipocyte secreted adipokines have been reported to promote tumor progression through several mechanisms. The aryl hydrocarbon receptor (AHR) is a ligand-activated transcription factor and potential drug target that has historically been linked to toxicity. The objectives of this study were to investigate potential interactions between AHR signaling and mitogenic adipokine signaling in human estrogen receptor (ER) positive breast cancer cells given that patients with ER positive breast tumors have been shown to be particularly sensitive to obesity associated increased cancer risk. Herein, adipocyte conditioned medium (adipo-CM), adipokine protein arrays and an IGF2 blocking antibody showed that adipo-CM contained high levels of several adipokines, is a potent inducer of cancer cell growth and that the adipokine insulin like growth factor 2 (IGF2) plays a major role in adipo-CM stimulated cancer growth. We discovered that treating breast cancer cells with the highly specific AHR agonist 2,3,7,8 tetrachlorodibenzo-p-dioxin (TCDD) significantly inhibited adipo-CM stimulated cancer growth and that TCDD specifically blocked IGF2 stimulated cancer growth through an AHR dependent mechanism. These results are the first to provide mechanistic evidence that IGF2 is an adipokine that plays a major role in adipo-CM stimulated breast cancer cell growth, that TCDD signaling inhibits mitogenic adipokine signaling in breast cancer cells, and that TCDD specifically inhibits IGF2 stimulated breast cancer cell growth through an AHR dependent mechanism. Given our data showing that targeting the AHR pathway inhibits mitogenic adipokine signaling in breast cancer cells provides preclinical insights into potential therapy for breast cancer in obesity.

## **Promotion of Breast Cancer Invasion and Metastasis by Benzo[a]Pyrene May Be Reduced by the Consumption of Omega-3 Polyunsaturated Fatty Acids.**

Theodore R. Witte

McKown Translational Genomic Research Institute, Marshall University, Joan C. Edwards School of Medicine, Huntington, WV

One in eight women in the United States will be diagnosed with breast cancer, many with a ductal carcinoma. Morbidity is often associated with the invasion of surrounding tissues and/or metastasis by the primary tumor to other locations such as the lymph nodes and bone marrow. Invasion and metastasis are promoted by the inflammatory eicosanoid prostaglandin E2 (PGE2). PGE2 production is limited by the available enzyme (Cyclooxygenase-2 (COX-2)) and substrate (arachidonic acid, an omega-6 polyunsaturated fatty acid (n-6 PUFA)). Supplementation with omega-3 PUFA eicosapentaenoic acid, or its precursor  $\alpha$ -linolenic acid (ALA), reduces the formation of PGE2.

We consume benzo[a]pyrene (BaP), a Group I carcinogen, from various sources including fossil fuels, smoking, and cooking. BaP exposure induces the expression of COX-2 through Aryl hydrocarbon Receptor (AhR) mediated pathways in cell lines derived from human ductal carcinoma pleural effusions, MCF-7 and MDA-MB-231. The resultant increase in PGE2 causes increased growth, motility, and invasiveness. The purpose of this study is to determine if supplementation with ALA can suppress these effects of BaP exposure through inhibition of PGE2 production.

Asynchronous MCF-7 and MDA-MB-231 cells were treated with a free fatty acid (10-300  $\mu$ M), either  $\alpha$ -linolenic or linoleic (An AA precursor), BaP (10nM-10 $\mu$ M), or both for up to 72 hours. Fatty acid incorporation was confirmed with gas chromatography. Viability was assessed with the 3-(4,5-dimethylthiazol-2-yl)-2,5-diphenyl tetrazolium bromide (MTT) and trypan exclusion assays. Cell cycle distribution and apoptosis were determined by propidium iodide and annexin V staining respectively.

Currently, both cell lines conform to expectations when treated with either fatty acids, or BaP, but exhibit a highly variable toxicity when co-treated.

Pretreatment with fatty acids before BaP insult may reduce the initial cytotoxicity. Further investigations are needed to understand the effects.



## **Incidence of Vaginal Cuff Dehiscence and Urinary Tract Injury after Total Laparoscopic Hysterectomy**

Cain MA, Shah M, Hart S, Bassaly R, Sobolewski C, Solnik J, Mehta S, Hoyte L, Glazerman L

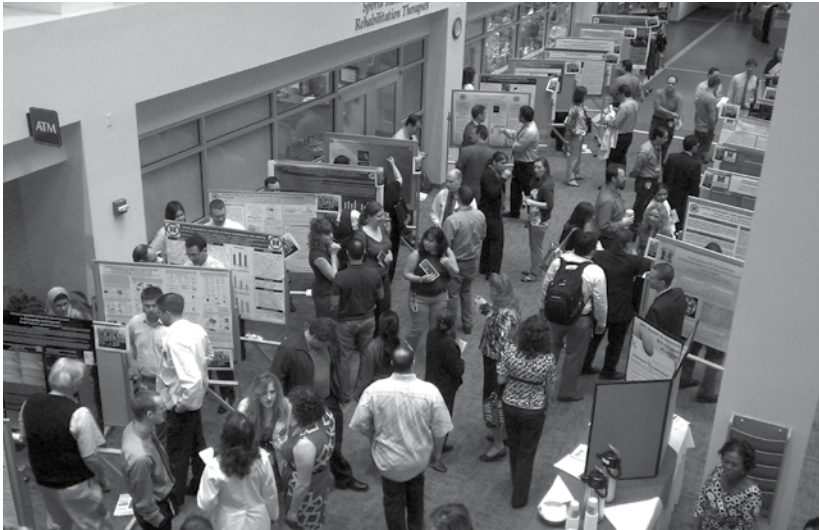
Department of Obstetrics and Gynecology, Urogynecology and Reconstructive Surgery, University of South Florida School of Medicine, Tampa, FL

The goal of this study is to evaluate total laparoscopic hysterectomy (traditional and robotic) procedures, performed in three university centers with advanced gynecologic laparoscopic programs, to describe the prevalence of post-operative vaginal cuff dehiscence and urinary tract injury. Estimated blood loss and bowel injury were assessed as secondary outcomes.

Retrospective chart review of all laparoscopic, and robot assisted, total laparoscopic hysterectomies were performed at Cedars-Sinai Medical Center, Duke University and the University of South Florida. Hysterectomy procedures performed for gynecologic malignancy, combined with sacrocolpopexy, converted to open procedures, or performed due to pelvic abscess or inflammatory disease were excluded. 402 women undergoing total laparoscopic or robotic hysterectomy performed by the study authors Drs. Larry Glazerman, Stuart Hart, Lennox Hoyte, Craig Sobolewski and Jonathon Solnik between 2007 and 2010.

Of the 402 hysterectomies, the incidence of urinary tract injury, bowel injury and vaginal cuff dehiscence were 1.0%, 0.5%, and 0.2% respectively. 99.5% of cases were utilized electro-surgery to perform the colpotomy. Suture material used included 67.7% PDS, 23% vicryl 6.2% maxon, 0.7% prolene, and 0.7% v-lock. Mean estimated blood loss was 115 ml with a range of 0-550ml.

The incidence of vaginal cuff dehiscence after total laparoscopic or robotic hysterectomy, regardless of the use of electro-surgical energy to perform the colpotomy, was lower than previously reported. Incidence of urinary tract and bowel injury were low and consistent with prior reports.





**POSTER PRESENTATIONS • SESSION I • 9:45 AM – 10:30 AM**

**25TH ANNUAL  
RESEARCH DAY  
POSTER SESSION**

## **Genetic Polymorphisms in CYP2B6 and Sudden Death of Methadone Users in West Virginia and Kentucky**

Taha Ahmad, Samie Sabet, Lauren L. Richards-Waugh  
and Gary O. Rankin

Department of Pharmacology, Physiology and Toxicology and  
Department of Forensic Science, Marshall University

Methadone is used therapeutically as a painkiller and for the prevention of opiate withdrawal symptoms. Elevated blood concentrations of this drug in the body can lead to respiratory depression and death. Cytochrome P450 2B6 (CYP2B6) contributes to the metabolism of methadone in the body. The purpose of this study was to determine if a single nucleotide polymorphism (SNP), a genetic variation in the gene for CYP2B6, can lead to slow metabolism of methadone causing respiratory depression and death.

Genomic DNA was isolated from blood stain cards prepared during autopsies at the West Virginia and Kentucky Offices of the Chief Medical Examiner. DNA samples underwent real time polymerase chain reaction (RT-PCR) utilizing TaqMan Allelic Discrimination Analysis to determine the genotypic frequencies of SNP rs8192709 (C/T) in the CYP2B6 gene of methadone fatality (134) and control (268) cases.

The methadone fatality and control groups were both within Hardy Weinberg Equilibrium with p values of 0.88 and 0.95, respectively. Methadone fatality and control group minor allele frequencies (MAFs) were 4.1% ( $p= 0.41$ ) and 5.2% ( $p= 0.72$ ), respectively, compared to a 6% MAF in the general Caucasian population. The minor allele frequency for SNP rs8192709 observed in methadone fatalities is not significantly different from that observed in the general population.

Based on these results, this SNP is likely not linked to methadone fatality. The laboratory will further study roles of two other common SNPs of CYP2B6 gene in the fatalities stated above. Supported by NIH Grant 5P20RR016477 and 8P20GM103434 to the West Virginia IDeA Network for Biomedical Research Excellence.

## **Effect of hemodynamic management in the perinatal outcomes of obese pregnant patients**

Jessica Granger, David Chaffin

Department of Obstetrics & Gynecology,  
Marshall University School of Medicine

To determine whether maternal and fetal outcomes were improved when pregnant patients weighing over 300 pounds (77 kilograms) were managed according to hemodynamic parameters of cardiac output and mean arterial pressure versus those patient's with similar weights managed without knowing these parameters.

A retrospective chart review was performed at Cabell Huntington Hospital in Huntington West Virginia for all deliveries occurring between January 1, 2009 to June 30, 2012. Any patient delivering during that time that was over 300 pounds (77 kilograms) had their chart reviewed. These patients were then divided into two groups, the first being those patients that had been evaluated through our facility's Maternal Hypertension Clinic (MHC) and treated based on hemodynamic profiles measuring cardiac output and mean arterial pressure. The second group, the control group, were those patients that were managed outside of the MHC by their primary physician. Primary outcomes included rate of hypertension disorders and preeclampsia, secondary outcomes that were also evaluated were gestational age at delivery, need for additional anti-hypertensive medications during and after delivery, admission of the infant to the neonatal intensive care unit (NICU), and need for inpatient admission during the pregnancy related to a hypertensive disorder. The two groups were then compared based on the primary and secondary outcomes listed above.

(Not available)

(Will be available by research day)

## **A Case of Congenital Unilateral Absence of the Vas Deferens.**

Bi Mo, Vishnu Garla, Lawrence Wyner

Department of Surgery,  
Joan C. Edwards School of Medicine, Huntington, WV.,

Department of Internal Medicine,  
Joan C. Edwards School of Medicine, Huntington, WV.

Congenital unilateral absence of the vas deferens occurs in 0.5-1 percent of males. It has been associated with various genitourinary abnormalities including renal agenesis. We report a case of congenital unilateral absence of the vas deferens found incidentally during vasectomy in a patient with known unilateral renal agenesis

A 24-year-old male presented to our urology clinic requesting vasectomy. His past medical history was significant for left renal agenesis. Following successful right vasectomy, several attempts to locate the left vas deferens were unsuccessful. We diagnosed congenital unilateral absence of the vas deferens (CUAVD). Follow-up semen analysis showed azoospermia.

As vasectomies are increasingly performed in outpatient settings, it is imperative that physicians be aware of this condition, which can be recognized by a simple physical exam. Recognition could prevent unnecessary surgery and prompt providers to investigate for associated abnormalities.

## **Interstitial nephritis as a rare manifestation of Cryptococcus in an AIDS patient**

Aviral Roy, Thomas C Rushton, Jose-Mario Fontanilla

Department of Internal Medicine, Section of Infectious Disease,  
Joan C Edwards School of Medicine, Marshall University

Cryptococcal infections in AIDS patients typically affect the meninges, lungs and skin. We present a case of massive cryptococcal invasion of the renal interstitium in a patient with meningitis and fungemia.

This is a 46 year old male who has sex with men (MSM) admitted with fever, weakness and intractable nausea. His HIV test was positive and CD4 count was 7. Blood cultures from admission grew yeast after 2 days, and this was later identified as *Cryptococcus neoformans*. His mental status deteriorated and lumbar puncture was performed with an opening pressure of 25 mm H<sub>2</sub>O. India ink stain revealed multiple encapsulated organisms with growth of *Cryptococcus*. Prior to initiation of liposomal amphotericin and flucytosine, his creatinine increased from 0.9 to 3 mg/dL. Renal biopsy showed massive interstitial infiltration with minimal inflammatory change. Blood cultures cleared after 13 days of therapy, opening pressure decreased to 12 cm H<sub>2</sub>O after serial lumbar punctures, but CSF cultures remained persistently positive. Antiretrovirals were started on hospital day 32. His clinical condition continued to decline and a decision was made to withdraw care after 40 days in the hospital.

Cryptococcal involvement of the genitourinary system is quite rare with most of the cases being prostatitis rather than kidney involvement. Renal failure in a patient with advanced AIDS and cryptococcosis are typically due to HIV nephropathy and/or drug toxicity with Amphotericin B. However, in our patient, renal failure was attributed to massive infiltration of cryptococcus without signs of significant inflammation, glomerular sclerosis or tubular abnormalities. This phenomenon should be considered in the differential diagnosis of acute renal failure in disseminated Cryptococcal infections in an AIDS patient.

# **Urgent Capsule Endoscopy in a Hospitalized Patient with Obscure Overt GI Bleeding Changes Subsequent Management**

Senait Teklehaimanot, Rezwan Ahmed, Yaser Rayyan

Internal Medicine, Marshall University

## **Introduction**

Small bowel tumors account for approximately 1.1-2.4% of all neoplasms of the Gastrointestinal (GI) tract. The small bowel has traditionally been a difficult area to visualize due to its unique anatomy, location, and tortuous nature. In recent years, however, the use of capsule endoscopy has allowed for the evaluation of diseases in this area of the GI tract. We describe a case of a patient with obscure overt GI bleeding who underwent a capsule endoscopy (CE) procedure and was found to have a small bowel lymphoma.

## **Case Report**

This is a 76 year old patient who presented to the emergency department (ED) with a one week history of dark bloody stool. The patient had a past medical history significant for anemia of chronic disease, chronic pancreatitis, atrial fibrillation, and alcohol abuse. He presented to the ED with a hemoglobin level of 5.3 g/dL. The patient was admitted to the intensive care unit and started on an Esomeprazole drip. During his hospitalization, the patient had a colonoscopy, esophogastroduodenography, two bleeding scans, and a CT angiograph that were not able to pinpoint the exact source of bleeding. The patient was given 8 units of packed red blood cells, but continued to bleed. Assuming that diverticulosis was the culprit, the plan was to proceed with subtotal colectomy. A CE was performed and showed a polypoid mass with bleeding stigmata in mid-jejunum with stricture and ulceration highly suspicious of small bowel neoplasm. The patient underwent an exploratory laparotomy, with partial resection of the small bowel.

## **Discussion**

The use of CE has allowed for earlier detection of small bowel pathology, which has ultimately lead to proper management and treatment for GI abnormalities. Our case demonstrates that CE is a valuable, non-invasive, well tolerated and cost effective tool in hospitalized patients with overt obscure GI bleeding.



## **Physical Education and Bone Mass Development**

Franklin D. Shuler, Thomas Gill,  
and Dana Lycans

Department of Orthopaedic Surgery and JCESOM

Peak bone mass is generated shortly after 20 years of age, followed by a lifelong decline in bone strength. Daily physical activity programs in schools have been shown produce a measurable increase in bone density in prepubertal children when compared to control groups. However, there is no federal law requiring physical education (PE) in American schools. Individual states decide whether physical education is a requirement. The landscape is very concerning with only 1 in 6 schools requiring PE 3 days per week and 4% of elementary schools, 8% of middle schools and 2% of high schools providing daily PE. Since WV has the second oldest population in the country with a significantly higher risk of osteoporosis and fracture, we want to promote the importance of PE and bone health with this study.

West Virginia state law, other state mandates for PE, and current literature about the effects of PE on bone health were reviewed.

In West Virginia, physical education is mandatory in grades 1-8, and only one physical education class is required in four years of high school. This data is concerning because bone mass development occurs most rapidly through puberty and slows considerably thereafter. Short term studies have shown that load-bearing exercise programs in prepubertal and early adolescent children produce a significant increase in bone mineral density.

This information has provided the foundation for clinical studies to assess the impact of PE in high school students using body mass composition analysis techniques available at the JCESOM.

# **Pigmented Villonodular Synovitis Presenting as Anterior Knee Pain with Non-classic MRI Findings**

Daniel Woods, Felix Cheung

Department of Orthopaedic Surgery, JCESOM

Pigmented villonodular synovitis (PVNS) is a rare intra-articular proliferative disorder which is marked by inflammation and hemosiderin deposits in the synovium. Classic MRI findings are often diagnostic, demonstrating a nodular, enhancing lesion with a hemosiderin signal. Treatment of this disorder has largely consisted of arthroscopic versus open intra-articular, intra-lesional excision. However, the misdiagnosis of PVNS instead of sarcoma can lead to significantly more radical surgery (including amputation) and mortality.

We present a case in a 31 year old female athlete with anterior knee pain for 3 years who was unsuccessfully treated with physical therapy. Physical exam revealed a moderate effusion painful palpable mass anteriorly just proximal to the patella. An MRI revealed a diffusely enhancing, nodular lesion in the suprapatellar pouch measuring 3.5 x 2.8 x 1.1 cm. A lack of hemosiderin was noted on the images, calling into the question of the expected diagnosis of PVNS. Synovial sarcoma was entertained as a possible diagnosis. A biopsy was ruled out due to the risk of contamination of the joint, and a radical resection was planned. This was done intra-articularly, using the synovium as a margin. Final pathological diagnosis yielded classic findings of PVNS, with negative margins. The patient is now 1 year post-operative and has returned to sports. She reports no effusions and only mild pain with extensive running.

While an intralesional excision may have yielded equivalent recurrence rates and less initial knee stiffness and pain, the risk of risk of malignant spread into the joint was too great a risk given the inconclusive diagnostic tests. We recommend a thorough pre-operative evaluation with contrast MRI to help diagnose PVNS, with consideration of open wide resection using the synovium as a margin, or extra-articular needle biopsy if possible.

## **Healthcare Provider Barriers to Influenza Vaccination**

George M. Yousef, Lynne J. Goebel, Shirley M. Neitch,  
and Maurice A. Mufson

Department of Internal Medicine, Joan C. Edwards School of  
Medicine, Huntington, WV.

The healthy people 2020 target for influenza vaccination among people over age 65 is 90 percent. During the 2010-2011 influenza season only 67% of the elderly were vaccinated.

We conducted a survey of healthcare provider barriers at our university practice. Data was analyzed from 66/188(35%)physicians and physician assistants(PA) and 128/797(16%)nurses.

Only 24%(15)of physicians /PA's and 10%(12)of nurses used standing orders. Additionally 43%(27)of physicians/PA's and 56% (65)of nurses considered August or September as too early to administer the vaccine. Thirteen percent(8)of physicians/PA's and 9%(11)of nurses did not get the vaccine, 7%(4)of physicians/PA's and 13%(16)of nurses were concerned with vaccine safety, 8%(5) of physicians/PA's and 9%(10)of nurses believed that you could get the flu from the vaccine and 2%(1)of physicians/PA's and 9%(11)of nurses believed cost was a barrier. Thirty percent (20/66) of physicians did not speak English as their first language and significantly more of them thought that influenza vaccine can cause the flu ( $p=0.001$ ) and were concerned about its safety ( $p=0.001$ ).

Most physicians and nurses surveyed are not using standing orders, an intervention shown to increase influenza vaccination rates. Avoiding vaccination in August and September is contrary to CDC recommendations and represents missed opportunities for those patients whose next appointment may be after the flu season. Surprisingly, some physicians and nurses are still concerned about vaccine safety and efficacy and avoid getting the vaccine themselves. Some providers were unaware that the vaccine is free. More education of healthcare providers is necessary promote greater use of influenza vaccine in the elderly.

## **Inhibition of Hypoxia-Inducible Factor-1 alpha Expression in Melanoma by Ascorbic Acid**

Lacey Vence, Richard Niles, Sarah Miles

Marshall University Joan C. Edwards School of Medicine,  
Department of Biochemistry and Microbiology, Department of  
Biochemistry and Microbiology

Melanoma is the deadliest form of skin cancer and its incidence has been increasing dramatically. Hypoxia inducible factor 1-alpha(HIF1a) is a transcription factor that becomes activated when cells experience hypoxic conditions. Once activated, it turns on genes that aid in the survival of the cells. Human melanoma cells have an increased amount of HIF1a under normoxic conditions. It has been shown that dietary constituents, such as ascorbic acid decrease the protein level of HIF1a. However, concentration, time, and combinatorial effects of these dietary agents on HIF1a need to be established.

We treated human melanoma cells(WM9) with ascorbic acid and analyzed HIF1a levels by western blot, and activity using a luciferase reporter gene containing a hypoxia response element (HRE). We then tried to decrease HIF1a levels in the presence of cobalt chloride(CoCl<sub>2</sub>), a hypoxia mimetic.

We were unable to reproduce previous results of ascorbic acid decreasing HIF1a protein levels; however, in the presence of CoCl<sub>2</sub>, reporter gene activity demonstrates that cotreatment with ascorbic acid significantly decreases HRE reporter gene activity. To determine whether ascorbic acid is acting via the prolyl hydroxylase-2(PHD2) enzyme, cells were cotransfected with PHD2 siRNA and the HRE reporter with the thought if ascorbic acid is functioning via PHD2, then by knocking it down, we should see a decrease in the ability of ascorbic acid to decrease the reporter gene.

Initial results suggest that ascorbic acid is still able to decrease the reporter gene activity in the absence of PHD2. However, PHD2 protein levels may still be elevated possibly due to a long half-life. Currently we are working on knocking down the PHD2 for at least 48 hours before adding the ascorbic acid.

## **A rare case of Cushing syndrome secondary to squamous cell lung cancer**

Vishnu Garla, Randa-Al Jayoussi, Christine Oakley

Internal Medicine-Pediatrics, Marshall University School of Medicine

Cushing syndrome comprises of a constellation of signs and symptoms due to chronic glucocorticoid excess. Cushing syndrome secondary to ACTH secretion other than the pituitary is called ectopic ACTH syndrome. Cushing syndrome secondary to ectopic ACTH secretion may be difficult to diagnose as they may not present with signs and symptoms of classical Cushing syndrome. Since there may be an increased incidence of complication, the early diagnosis and treatment of this condition is of essential importance

A 57 year old male patient with Stage IV squamous cell cancer of the lung diagnosed 2 years ago treated with a combination of chemotherapy and radiotherapy. About 6 months ago he had new mediastinal lymphadenopathy and was started on carboplatin and gemcitabine. Patient also had worsening hyperglycemia and hypokalemia. He was started on insulin, aldactone and potassium supplementation. On the day of admission patient was found to be hypertensive (170/95) in the oncology clinic and sent to the hospital. Physical exam was within normal limits. Patient was given labetalol for hypertension. In light of the above symptoms, Cushing syndrome was suspected. Hormonal testing showed a very high serum cortisol, ACTH and 24hr urinary free cortisol levels. MRI of the brain was normal. There was no suppression of the serum cortisol levels with the high dose dexamethasone test. A diagnosis of ectopic ACTH syndrome was confirmed. The patient was started on ketoconazole (200 mg every 8 hours) and his cortisol levels decreased from 69.2 to 41.8. The patient was discharged but lost to follow up.

To our knowledge this is only the third case of squamous cell cancer of the lung causing Cushing syndrome. A heightened awareness is needed for the diagnosis of this condition as it has significant differences as compared to classical Cushing syndrome.

## **Bisphenol A (BPA): an integral component of vitamin D deficiency?**

Franklin D. Shuler, Sinan Ozgur, Sammy Hodroge, Cody Stauffer  
MacDowell, Jonathan Lewis, Eric Tee

Department of Orthopaedic Surgery, Marshall University

Bisphenol A (BPA), a chemical used in the production of polycarbonate plastics, is one of the most produced industrial chemicals in the world today with over 8 billion pounds used in manufacturing yearly. It's diverse spectrum of application – from plastic bottles to the linings of canned food – make human exposure virtually guaranteed but very difficult to quantify. 93% of American urine samples test positive for BPA metabolites and a recent JAMA article showed that urine BPA levels rise 1,221% after 5 days of eating canned soup. Recent controversy surrounding BPA stems from its status as an endocrine disrupting chemical which makes accurately determining adverse effects and the lowest level at which these effects occur technically difficult. The health effects of exposure are currently being established but include cancer, diabetes, cardiovascular disease and obesity. These health effects are identical to those reported for vitamin D deficiency. This article explores the correlation between health effects associated with BPA and those associated with vitamin D deficiency with studies in progress to see if a direct causal relationship is present.

### Literature review

BPA activates a catabolism mechanism for vitamin D. This mechanism is fostered by BPA-mediated CYP3A4 induction which changes the hydroxylation of vitamin D from the active 25-hydroxyvitamin D storage form to the inactive 24-hydroxyvitamin D metabolite. Additionally BPA activation of the PXR receptor pathway also inhibits the targeted activation of vitamin D receptor gene activation. Current studies are being done in to further study this effect.

This is the first report to link the vitamin D pathway health effects with the exposure to BPA.

## **Chmp1 negatively regulates EGF signaling in Drosophila wing vein development**

Meagan Valentine, Simon Collier

Biomedical Sciences, Marshall University

Chmp1 is a component of the Endosomal Sorting Complex Required for Transport-III (ESCRT-III), a very conserved protein complex involved in degradation of activated transmembrane receptor proteins. Chmp1 is a novel tumor suppressor, and it has recently been linked to pancreatic and renal cancers in humans. However, most studies on Chmp1 have been completed in yeast, and are inconsistent in regard to the importance of Chmp1 to cellular function. Drosophila has a Chmp1 protein that is homologous to Chmp1 in humans. We are using Drosophila to study Chmp1, as it provides a system that is easily manipulated and offers an excellent model for studying the importance and function of Chmp1 during the development of a multicellular organism.

We began by using Chmp1 knockdown to evaluate the importance of Chmp1 during development. Ubiquitous Chmp1 knockdown is lethal during fly development, so we limited Chmp1 knockdown to the wing, a non-essential tissue. We have shown that Chmp1 interacts genetically with both positive and negative regulators of Epidermal Growth Factor Receptor (EGFR) signaling in a way that suggests that Chmp1 negatively regulates EGFR signaling. We are validating this finding by investigating components downstream of the EGFR. We are using immunohistochemistry to evaluate the effect of Chmp1 knockdown on Blistered (Bs), a protein that is negatively regulated by EGFR signaling. Additionally, we are using western blot to study the effect of Chmp1 knockdown of di-phospho-ERK (dpERK), which increases in response to EGFR signaling.

So far, our results support a role for Chmp1 in negatively regulating EGFR signaling. This finding is consistent with the literature, which has shown that EGFR signaling is regulated by ESCRT machinery. Additionally, this is consistent with a role for Chmp1 in regulation of growth.

# **A case of atypical femoral fracture associated with Alendronate therapy**

Yanal Masannat, Christine Oakley

## **Endocrinology**

Osteoporotic hip fractures have devastating effects on quality of life and are associated with increased morbidity and mortality. Bisphosphonates have been used to suppress bone turnover, and remain the first-line therapy for osteoporosis. However, these medications should not be used indiscriminately or indefinitely given the potential for adverse effects, including the most recently described possible association with atypical femoral fractures. We report a case of a 78 year old female who presented with hip pain secondary to atypical femoral fracture while on Alendronate therapy for osteopenia.

78 years old female with history significant for osteopenia. She was initiated on Alendronate 70mg weekly three years ago for fracture prevention due to high risk status. She presented with acute onset left hip pain without preceding trauma, but admitted to experiencing milder hip discomfort for the preceding month. Her x-ray demonstrated a complete subtrochanteric fracture of the left femur that was transverse in orientation laterally and oblique configuration medially. Her clinical course and radiographic features were consistent with an atypical femur fracture. She had a successful open reduction and internal fixation of the fracture. Her oral bisphosphonate was discontinued.

Bisphosphonates remain the first-line treatment for osteoporosis and are efficacious at reducing fracture risk. Although the risk of atypical femur fractures is much less than the risk of untreated osteoporotic fractures, physicians should appropriately choose bisphosphonate therapy for patients, and be aware of prevention strategies to minimize the risk of developing atypical fractures. These strategies include identifying high-risk patients for fractures using WHO FRAX calculator, employing drug holidays for those on prolonged bisphosphonate therapy with stable disease and educating patients to report new-onset thigh and groin pain and consider early investigations in these situations such as bone scans and/or MRI to identify these fractures at an early stage.



## **Diagnosis and treatment of anaplastic ependymoma in a child less than one year of age**

Kacey O'Malley, Marie D. Frazier, and Mark Mogul

Department of Pediatrics, Marshall University,  
Joan C. Edwards School of Medicine, Huntington, WV

Ependymomas are the third most common brain tumor in children. The two main prognostic factors for survival are age of onset and residual disease following surgical resection. Considering these factors, an infant less than 1 year of age has a five year survival rate of 25%, as compared to 70% for patients ages 5 to 19. Prognostic data and information regarding long term effects of treatment modalities are extremely limited by the lack of research assessing this younger age group and because radiation therapy is generally not used in this population. This study follows the unique case of a 6 month old presenting with a grade III anaplastic ependymoma that has been found to be incurable by surgical resection and chemotherapy alone.

The patient was admitted to the pediatric intensive care unit with a history of irritability and poor feeding and underwent septic workup with a normal lumbar puncture. Computed tomography of the head showed a large mass in the right cerebral hemisphere with transtentorial herniation. Magnetic resonance imaging provided further detail of a 9cm x 6cm x 9cm multi-cystic mass in the right hemisphere with resulting subfalcine herniation and moderate hydrocephalus. Surgical resection to debulk a large amount of the tumor was performed with resulting pathologic diagnosis of grade III anaplastic ependymoma. She received 6 cycles of chemotherapy based on high risk protocol per Children's Oncology Group. A second resection was completed resulting in minimal residual tumor remaining. Throughout this course she showed minimal neurologic deficits. She is currently undergoing proton beam radiation as an experimental last resort.

This case outlines a rarely studied approach to diagnosis and treatment in an infant with an ependymoma who has failed traditional treatment options, adding invaluable data to the field of pediatric oncology and the future treatment of such controversial patients.

## **A RARE CASE OF ALTERED MENTAL STATUS**

Omolara A Olajide, Osiyemi Osinowo, Muhammed Waqas

Department of Internal Medicine, Marshall University  
Joan C. Edwards School of Medicine, Huntington, WV

Left ventricular thrombus (LVT) formation is a frequent complication in patients with acute anterior myocardial infarction. It is associated with increased risk of embolism. Higher mortality rates have been reported in patients with LVT after acute anterior MI, especially when these develop within the first 48 hours after infarction. Thrombi can also be found in some small apical infarcts with good global left ventricular systolic function and rarely in some inferior infarcts. These facts indicate the complex nature of LVT formation. Factors other than infarct size and site may play role in development of LVT.

A case report of a 73 year old male with a history of Coronary Artery Disease , Hypertension, COPD, Atrial fibrillation, Squamous Cell Carcinoma of the lung status post left lobectomy presented with chest pain, shortness of breath, fevers and cough productive of blood tinged sputum. Chest X ray was suggestive of pneumonia with severe emphysema. He was treated for CAP and COPD exacerbation with antibiotics, steroids and nebulization. On day 3 of admission, patient developed altered mental status with alternating deep sedation. Examination showed small reactive pupils with no meningismus. CT Head without contrast showed a ring enhancing lesions in the left subcortical frontal lobe. MRI brain showed multiple ischemic foci. Steroids were discontinued and a lumbar puncture yielded normal CSF findings. An ECHO was done which revealed a left ventricular mural thrombus; global hypokinesis with an EF of 25-30%. Patient was started on anticoagulation heparin and warfarin. Mental status gradually improved after anticoagulation.

Echocardiography is the most valuable noninvasive method for demonstrating wall motion abnormalities of the infarcted area, ventricular function, and mural thrombi after acute myocardial infarction. Anticoagulation for 3-6 months with warfarin is advocated for patients with demonstrable mural thrombi.

## **A case of Posteromedial papillary muscle rupture**

Neha Goyal

Internal Medicine, MUSOM

This case highlights the importance of recognizing complications of myocardial infarction especially acute mitral regurgitation caused by papillary muscle rupture.

66 yo man with h/o dyslipidemia presented to ER with abnormal EKG done at PCP office, his wife told his PCP about intermittent, dull, exertional chest pain from right side of chest to left that he had experienced, onset 8 days prior to office visit, accompanied by dyspnea. He received aspirin and was asked to go to ER. In the ER, he denied chest pain and dyspnea and was completely symptom free for past 48 hours. EKG on presentation showed Q waves in inferior leads and evolving ST-T wave changes. Vitals were normal. On examination, he was alert, oriented, in no acute distress. Lungs were clear to auscultation, JVD not elevated, no peripheral edema. S1, S2 normal, abdomen was soft, non-tender, normal bowel sounds. CBC, chemistry were normal. Troponin was 7.36, repeat one 5.9. Chest radiograph was within normal limits. Cardiology evaluated him and ordered heparin and plavix, cardiac enzymes, stat echocardiogram and he was scheduled for left heart catheterization (LHC).

While being worked up, he experienced excruciating, substernal chest pain, became hypotensive, tachycardic, hypoxic and diaphoretic. BP was 70s/50s, saturations: low 80s. Repeat EKG showed worsening ST elevation in inferior leads. He was immediately taken to catheterization laboratory and LHC revealed proximal right coronary artery occlusion, had percutaneous coronary intervention. He remained hypotensive, hypoxic, was on intravenous fluids and pressors, had to be intubated. Intra-aortic balloon pump was placed to maintain hemodynamic stability, eventually had to be maintained on cardiopulmonary support. Chest radiograph revealed acute pulmonary edema. Transthoracic echocardiogram was done followed by transesophageal echocardiogram: revealed posteromedial mitral papillary muscle rupture, also flail anterior leaflet. He was emergently transferred to higher center, received mitral valve replacement, subsequently extubated.

## **Management of a pregnant patient with a history of Hansen's disease and co-infection with neurosyphilis**

Nitisha Mulpuri

Department of Obstetrics and Gynecology,  
Joac C. Edwards School of Medicine

According to the CDC database in 2009, a total of 213 new cases of Hansen's disease were reported in the United States. A total of 12,685 cases of Hansen's Disease have been reported in the United States since 1894. In 2010, the incidence of primary and secondary syphilis was 1.1 cases per 100,000 women. Furthermore, a literature review reveals no previous cases of pregnant women co-infected with Hansen's disease and neurosyphilis.

A 20 y.o. G1P0 who moved to the United States from Micronesia with known history of leprosy present to the OB clinic at approximately 9 weeks gestation. Patient was diagnosed with leprosy based on skin lesions and treated with dapsons before moving to the States. At her first prenatal visit, patient denied history of any STDs. Physical exam was remarkable for four skin lesions consistent with tubercular leprosy and a gravid uterus consistent with dates. Prenatal panel showed reactive RPR with titers 1:64 and FTA positive on initial and repeat testing. Patient was admitted with a diagnosis of leprosy and syphilis. Infectious disease was consulted at that time and treatment was initiated. Cerebrospinal fluid analysis was consistent with neurosyphilis. Biopsy of skin lesions was consistent with diagnosis of tubercular leprosy with reversal reaction was made and required no treatment at that time. Patient continued treatment for neurosyphilis with regular follow up appointments throughout the pregnancy.

This case illustrates a unique situation requiring multi-disciplinary management which allows for a retrospective look at the current management protocol and availability of resources for such cases. This case also stimulates the need for further follow-up and analysis of similar cases in the United States and need for follow up of infants and sexual partners exposed. Examination of these factors will allow for better management and prevention of such cases in the future.

## **Elevated PTH: True or False Positive?**

Jillian Douglas, Thomas Dougherty, Omolola Olajide

Department of Endocrinology, Marshall University

Intact parathyroid hormone (PTH) assay with Siemens kit on Centaur using EDTA plasma is a “sandwich” technique targeting 2 distant sites on the ligand. A capture antibody and signal antibody target different epitopes. PTH is quantified by measuring the signal antibody generated reaction.

A 55 year old female presented for evaluation of hyperparathyroidism. She had hypercalcemia one year prior. A parathyroid scan showed increased activity at the right lower thyroid pole consistent with adenoma. She subsequently had a parathyroidectomy. A post-operative serum PTH was 20.4 pg/mL and calcium was 9.3 mg/dL. Five months later she had an elevated plasma PTH of 223 pg/mL with a repeat of 553 pg/mL. She remained normocalcemic and asymptomatic. A repeat parathyroid scan did not show a recurrent or residual parathyroid adenoma. We requested patient have a repeat PTH performed at another laboratory. Serum based PTH using Siemens kit on Centaur was 75 pg/mL and repeat was 73 pg/mL. It was concluded that the initial PTH results were falsely positive secondary to assay interference by a patient EDTA-affected antibody.

The possibility of antibody interference should be considered when the test result does not correlate with the clinical picture and negative imaging results. The prevalence of interfering antibodies in blood samples varies among reported studies. The possibility of an anti-animal antibody interference should prompt testing with murine antibody-based sandwich assay, incubation with heterophile antibody blocking tubes, and/or a goat antibody-based PTH testing system.

This case highlights the importance of careful interpretation of laboratory results in conjunction with the clinical picture and using confirmatory testing with discordant results.

# **Large Asymptomatic Adrenocortical Carcinoma in a Primigravida: Case Report**

Jesse Cottrell

Obstetrics and Gynecology, Marshall University

Adrenocortical carcinoma is a rare aggressive cancer with an incidence of 1-2 per million annually; A review of the literature describes 26 cases of adrenocortical carcinoma concurrent with pregnancy. We report a unique case in which a large tumor was visualized during obstetric ultrasound in an asymptomatic white female.

A 33 year old G1 presented with vaginal bleeding during the second trimester and on ultrasound was found to have a large left upper quadrant mass. Subsequent imaging revealed a large heterogenous retroperitoneal mass with small echogenic foci. A left adrenalectomy using a retroperitoneal approach was performed and pathology revealed an adrenal cortical neoplasm of uncertain malignant potential weighing 1510 grams and measuring 26.3 x 20.7 x 9.1 cm. The patient went on to have an uncomplicated vaginal delivery at term.

Previous studies have demonstrated poor fetal outcome and prognosis when adrenocortical carcinoma is diagnosed during pregnancy. In this case urgent surgery during the second trimester led to successful tumor resection and vaginal delivery of a term infant.

## **Metastatic Lung Cancer to the Liver and Pancreas**

Laurie B. Matt, Rajesh Sehgal

Medical Oncology, Joan C. Edwards School of Medicine

Metastasis to the pancreas is uncommon and only represents 2% of all pancreatic neoplasms.<sup>1</sup> Based on our literature search to date, there have only been a few case reports of pancreatic metastasis clinically apparent at time of diagnosis from a primary lung cancer.<sup>1,2</sup>

A 58 year old female presented in April 2012, the patient started to have progressive symptoms of dyspnea on exertion and shortness of breath, cough, and wheezing. PET scan performed on 8/6/12 demonstrated a right perihilar mass with cavitory features measuring 3.8x4.8cm; too numerous to count hypermetabolic liver masses; a mass in the tail of the pancreas 3.8x6.1cm; and a retrocaval retroperitoneal LN enlarged. Biopsy from the liver and pancreatic mass in August 2012 showed metastatic squamous cell carcinoma with lung as the primary tumor.

Although metastatic disease to the pancreas is a common finding at autopsy, the incidence of radiographically evident metastatic disease to the pancreas is relatively low. Multiple studies have demonstrated a poor prognosis with lung cancer metastatic to the pancreas when compared to other tumors, especially renal cell carcinoma.<sup>12</sup> Therefore, even though metastatic lung cancer to the pancreas is uncommon, it should be considered when performing a metastatic work up.

## **Discovery of Duodenal Adenocarcinoma in a Patient with Celiac Disease**

Kimberly Weaver, Rezwan Ahmed, Alla Grigorian.

Department of Gastroenterology, Joan C. Edwards School of Medicine, Huntington, WV.

Approximately 8,700 new cases of small bowel malignancies will be diagnosed this year in the United States. Accounting for less than 2% of all gastrointestinal neoplasms, lesions of the small intestine present vaguely with abdominal pain, nausea, vomiting, diarrhea, or weight loss. Those with a history of Celiac Disease are predisposed to develop enteropathy-associated T-cell lymphoma and small bowel adenocarcinoma largely based upon the extent and duration of small bowel involvement.

A 32 year-old Caucasian female presented to the emergency department with crampy abdominal pain, bloating, nausea, and vomiting. Serologic testing revealed anti-tissue transglutaminase level greater than 100, and biopsies of the second portion of the duodenum confirmed the diagnosis of Celiac Disease. A strict gluten-free diet was initiated; however, the patient experienced additional weight loss and vomiting over the next three months.

Capsule endoscopy was attempted but required retrieval by endoscopy due to presence of duodenal stricture. Esophagogastroduodenoscopy revealed a 5-6 mm stricture with irregular, edematous mucosa that was biopsied. Pathology demonstrated a poorly differentiated adenocarcinoma.

The distal duodenum and proximal jejunum were resected. The tumor was classified as T4aN1M0, Stage IIIa small bowel adenocarcinoma. The patient is currently undergoing chemotherapy with FOLFOX regimen.

Patients with Celiac Disease are at increased risk for developing malignancy of the small bowel. Although these individuals are more likely to develop enteropathy-associated T-cell lymphoma, providers must maintain a high level of clinical suspicion for small bowel adenocarcinoma. Due to its non-specific presentation, small bowel adenocarcinoma is easily confused with refractory Celiac Disease. Symptoms such as continued weight loss, nausea, vomiting, or diarrhea may be explained by a dietary indiscretion; however, an appropriate work-up to rule out malignancy is warranted if symptoms persist despite compliance with a gluten-free diet.



## **Continuous Glucose Monitoring System (CGMS) – useful tool to detect glycemic variability**

Yanal Masannat, Henry Driscoll

Endocrinology, Marshall University

Self monitoring of blood glucose (SMBG) is an integral part of diabetes management. However, SMBG only gives blood sugars at different points in time when the patient chooses to test the blood sugar. Continuous glucose monitoring system (CGMS) is one of the devices which help detecting glucose variability not detected by finger-stick recordings which are normally performed prior to meals and at bedtime. We report a case of 39-years-old diabetic woman who had postprandial hyperglycemia detected on CGMS and missed on finger-stick recordings.

A 39-years-old woman with type 1 diabetes mellitus of 14 years duration. Her diabetes was poorly controlled with A1c of 7.9% in May 2012; however her diabetes was not complicated. The patient uses insulin pump and checks her blood sugar four times a day - prior to meals and at bedtime. She reported low pre-prandial and bedtime glucose on finger sticks. Due to discrepancy between the A1c value and finger stick checks, CGMS was deemed to be appropriate to determine if there is any particular glycemic pattern that may explain this discrepancy.

CGMS showed significant postprandial hyperglycemia. The elevated postprandial blood sugar tends to return to target range by the time the next finger stick is due to be checked. There was also overnight hypoglycemia with blood sugars dropping at 3 am, but coming up by the time the fasting finger stick is due to be checked. These patterns suggest that both the basal rates and correction doses were high, while the meal insulin doses were too low. Based upon that the basal rates were all reduced, the sensitivity factor was reduced and insulin to carb ratio was increased to provide more meal time insulin coverage for these post prandial hyperglycemic peaks.

## **Capsaicin: a novel dietary therapeutic agent in human small cell lung cancers**

Cody A. Stover, Clayton M. Crabtree, Aaron M. Dom, Jamie K. Lau, Kathleen C. Brown, Brandon S. Shiflett, Ted R. Witte, W.E. Hardman and Piyali Dasgupta

Department of Pharmacology, Physiology, and Toxicology,  
Joan C. Edwards School of Medicine

Capsaicin, spicy ingredient of chili peppers, is used to topically treat pain and inflammation associated with a variety of diseases. However, emerging evidence shows that it can induce apoptosis in different transformed cell types in vitro and in animal models. The present study examines the apoptotic activity of capsaicin in human small cell lung cancer (SCLC).

Here we show that capsaicin induced apoptosis in a panel of human SCLC in a concentration-dependent and time-dependent manner. Most importantly, capsaicin caused robust apoptosis in a panel of human SCLC cell lines, but did not affect normal human lung epithelial cells. The dietary administration of capsaicin decreased the growth H69 and DMS53 human SCLC tumors xenotransplanted in nude mice. The apoptotic activity of capsaicin was reversed with the generalized TRPV antagonist ruthenium red, indicating that TRPV receptors are involved in capsaicin induced apoptosis. However, antagonists to TRPV1, namely capsazepine and SB-366791, did not affect the apoptotic activity of capsaicin, suggesting the involvement of TRPV1-independent mechanism.

Our findings suggest that capsaicin may have potential applications as a novel agent for management and therapy of human SCLCs.

## **CALCIPHYLAXIS: A MISSED DIAGNOSIS**

Shirley Tetteh, Tilahun Belay, Wesam Bolkhir

Department of Internal Medicine, Marshall University  
Joan C. Edwards School of Medicine, Huntington, WV

Calciophylaxis is characterized by small-vessel calcification and cutaneous necrosis. The disorder comprises two processes: calcific arteriopathy and acute infarction of subcutaneous fat, a process apparently leading to reduced perfusion or vascular thrombosis. Calciophylaxis is rare, although the prevalence in one study was 4.1% in patients receiving long-term hemodialysis.

We present a case report of a 74 year old female with a history of Atrial Fibrillation, Diabetes Mellitus 2, and End Stage Renal Disease on Peritoneal Dialysis who was transferred from an outlying facility due to lack of Peritoneal Dialysis support and for management of bilateral lower extremity ulcers. Patient was initially diagnosed with cellulitis and treated without improvement. Patient stated that the ulcers had begun about 3 weeks ago and was about the size of a quarter but had progressively increased in size to involve both lower extremities; necrotic areas were approximately 15cmx8cm, surrounded by purple discolored patches. She has been bed bound due to her ulcers and had progressive shortness of breath. She had seen her family doctor earlier that week and had been started on doxycycline for management of cellulitis. Patient had peritoneal dialysis three times weekly; blood cultures were obtained which were negative. A diagnosis of calciophylaxis was made. Patient had daily wound dressing.

Biopsy is helpful for definitive diagnosis of calciophylaxis but can be associated with development of a non-healing ulcer. Treatment involves discontinuing sensitizing agents such as warfarin, correcting calcium and phosphorous levels, frequent hemodialysis with low calcium dialysate and parathyroidectomy if severe secondary hyperparathyroidism develops. Frequent wound debridement, hyperbaric oxygen therapy and antibiotics for infected lesions may be needed.

## **H. pylori and Chronic Refractory Idiopathic thrombocytopenic purpura**

Saqib Ahmed, Sydnee McElroy

Department of Family Medicine

Idiopathic thrombocytopenic purpura (ITP) is an acquired blood disorder where there is an isolated decrease in platelets. Antibodies are made against the platelets and the spleen removes them. Platelets are a key component of the clotting cascade, and low levels can cause bleeding. ITP can occur in both children and adults. Treatment typically involves steroids, IVIG, and splenectomy. Most children respond to steroids/IVIG and go into remission by six months. In adults, cases tend to be chronic, but 80% do respond to therapy. H. pylori, can play a role in the pathogenesis of ulcers and various cancers. There are studies that suggest H. pylori may play a role in some chronic ITP patients. Treatment of H. pylori infections in patients with chronic ITP has shown significant increases in their platelet counts. 10 percent of individuals in the USA between the ages of 18-30 have serological evidence of H. pylori. The prevalence rises with age.

A 19 year-old Caucasian female with no significant past medical history presents with a chief complaint of petechia on her extremities. With a day's duration, she woke up with epistaxis. Platelet count at the time was 2000. She was admitted. The patient received IVIG, decadron, a prednisone taper, rituximab, and rhogam. There were slight improvements in platelets, but the thrombocytopenia remained refractory. After 16 days, it was decided that the patient should undergo splenectomy. Despite the splenectomy, the platelets stayed low. She was given IVIG and treated for H. pylori. A week later her platelet count rose to 178,000 – her highest level.

This response was non-sustained. Her platelet count has been fluctuating since, but she hasn't had any reported bleeding episodes. She has been receiving IVIG, prednisone, and started taking Eltrombopag, a thrombopoietin receptor agonist. Her last platelet count was 160,000.

## **Vitamin D Community Sampling: Results of 2012 CHH Seniorfest**

Franklin D. Shuler, Becky Edwards, Joy Pelfrey, Teresa Sexton

Department of Orthopaedics Marshall University and Senior Services  
Cabell Huntington Hospital

Sufficient levels of vitamin D are important for maintenance of both skeletal and extra-skeletal health with vitamin D deficiency defined as a blood level 25-hydroxyvitamin D<sub>3</sub> of <30 ng/ml. As part of our community outreach with the Senior Services Division and the Senior Fracture Program at Cabell Huntington Hospital, we provided free vitamin D testing and FRAX fracture screening to participants of the September 2012 Seniorfest program.

25-hydroxyvitamin D – 25(OH)D -- levels were obtained for 129 seniors. Demographic information was obtained with PCP and patient mailed results with contact from the Senior Fracture Program Coordinator.

The average 25(OH)D level was  $30.1 \pm 2.8$  ng/ml (SEM). The lowest level was 7.0 ng/ml and the highest was 81.0 ng/ml in a supplemented patient. Eighty-two patients (64%) were diagnosed with vitamin D deficiency (<30ng/ml; with 43 patients < 20ng/ml) and 47 (37%) were sufficient. A total of 102 patients were able to be contacted post testing: 67 vitamin D deficiency patients and 35 sufficient patients.

- Vitamin D deficiency = 82 total patients: 67 patients were available for follow-up and 20/67(30%) were on a daily MVI or vitamin D preparation that averaged 650 IU vitamin D/day. For patients <20ng/ml only 5/35 (14%) were taking a supplement.
- Vitamin D sufficiency = 47 total patients: 35 patients were available for follow-up and 34/35 (97%) were on vitamin D supplementation protocols that averaged 1677 IU vitamin D/day.

Vitamin D levels following summertime maximal sun exposure were not able to make the majority of participants at 2012 Seniorfest vitamin D sufficient. Of those that were sufficient, they had higher vitamin D supplementation protocols that average over 1000 IU/d more than patients with deficiency states. The sufficient group on average had supplementation consistent with recommendations from the National Academy of Sciences.

## **Validation of a Markerless Motion Analysis System**

Saqib Ahmed, Felix Cheung

Department of Orthopaedic Surgery

Gait is the study of human locomotion. Medical applications such as tracking the walking pattern of stroke and post-surgical patients can be monitored. There have been different methods of studying gait throughout the years; one of the most recent is a marker-less motion capture system, allowing the advantages of ease of use and setup, and lower cost. The MotionMonitor is a software program that uses cameras to track motion while in a Biostage. To do so, an individual must be calibrated to the system. Light and clothing are two variables that may affect the calibration of this system. Our hypothesis was that there would be no statistically significant difference in variance among the light settings or in the clothing options.

To measure the light setting with the lowest variability, a cast was made to fix the right knee at 30 degrees. The MotionMonitor then measured this angle in three different light settings: dark, medium brightness, and full brightness. 600 data points were accumulated and the variance was determined for each light setting. For clothing, baggy pants, shorts, scrubs, white tights, and black tights were used. The same subject walked across the Biostage and the peak knee flexion angle was recorded. 45 data points were obtained per clothing option. The variance for each trial was calculated.

Using the Brown-Forsythe test for homogeneity of variance, it was determined that the data with the lowest variability came from the brightest light setting. For clothing, there was no significant difference in variability between shorts, black tights, and scrubs. However, white tights had the highest variability and this value is statistically significant from the other clothing options.

This suggests that to have the highest levels of internal validity while recording data in the Biostage, dark clothing with the highest level of light should be used.

## **Radiographic Screening of Breech Female Hips for Detection of Developmental Hip Dysplasia: Findings at a Small Institution**

Joseph Evans, Peter Chirico, Jill Hopkins, Krista Allen

Department of Pediatrics, Marshall University School of Medicine

In 2000 the American Academy of Pediatrics (AAP) released a guideline pertaining to screening for Developmental Dysplasia of the Hip (DDH). DDH is potentially a very debilitating condition if not detected early. One of the greatest risk factors of DDH is being a breech female. It was therefore recommended that screening radiographic hip ultrasounds of all breech female be done at 6 weeks and/or a radiograph of hips and pelvis at 4 months of age. Screening radiographic ultrasounds of all breech females, regardless of physical exam findings, for detection of DDH are unnecessary and costly. The incidence of DDH in breech females at our institution is assumed to be lower than that recorded by the AAP in their 2001 guidelines.

Reviewing of all radiographic data performed in our institution from 2006-2011 for all breech female newborns. We will compare the incidence of abnormal hip ultrasounds rate in breech females at our institution with the AAP guidelines.

Screening ultrasound of all breech female hips did not have a higher detection rate than newborn physical and routine exams. Our results of newborns with detected abnormalities are significantly different than the AAP guidelines.

Screening all breech females with ultrasounds is not beneficial. At our institution all of our abnormal radiographic exams were supported with physical exam findings in the NBN. A more proper recommendation would be to only radiograph those breech female infants with abnormal newborn exam.

## **Hemobilia with massive upper GI bleed**

Yusof Elgaried, Yaser Rayyan.

IM. Marshall University.

A 60-year-old male with h/o NHL on chemotherapy was admitted with hematochezia, hypotension and hemoglobin of 7 gm/dL. There was no coagulopathy or thrombocytopenia. The patient was stabilized. he underwent an urgent Colonoscopy which was remarkable for mild sigmoid diverticulosis without active bleeding. The patient was stable over 2 days and was discharged. He was readmitted 48 hours later with recurrent hematochezia and a HGB of 6 g/dl. EGD showed mild antral erosions, no active bleeding. The patient was stabilized and discharged. The patient bled for the 3rd time 1 week later. he was transfused and stabilized. 36 hours later, he developed severe RUQ pain and jaundice associated with fever, hypotension, tachycardia and tachypnea requiring respiratory support and pressors. labs remarkable leukocytosis, AST 200, ALT 150, ALKP 300, total bilirubin of 12 mg/dL, LFTs were normal on admission. CT scan showed thickening of the gallbladder with small calcified gallstones with intra-and extra hepatic duct dilation. Haziness in the perocholecystic area with GB wall thickening suspicious for cholecystitis. He was planned for urgent ERCP for a presumed cholangitis. The patient was in septic shock, he was intubated, resuscitated and was rushed to the endoscopy unit for ERCP. There was blood clots exiting the orifice of the bulging biliary papilla. Deep cannulation of the common bile duct with contrast injection revealed a large tubular clot material in a dilated biliary tree, there was no obvious stones. Papillotomy done facilitate the extraction of the blood clots. Immediate gush of pus and blood clots was noticed. no active bleeding. duct clearance confirmed and plastic biliary stent placed. The patient did well and he made an uneventful recovery without further bleeding. A follow up ERCP 8 weeks later for stent extraction showed multiple small stone fragment that were removed via the extracting biliary balloon.



## **MG624, a synthetic small molecule alpha7 receptor antagonist, inhibits growth of human small cell lung cancer**

Christopher A. McNees, Kathleen C. Brown, Jamie K. Lau, Aaron M. Dom, Brandon S. Shiflett, Theodore R. Witte, W. E. Hardman, Haitao Luo, Yi C. Chen, A. Betts Carpenter and Piyali Dasgupta

Department of Pharmacology, Physiology, and Toxicology, Joan C. Edwards School of Medicine, Marshall University

Small cell lung cancer (SCLC) is characterized by early dissemination, aggressive clinical course and low survival rates. Smoking is correlated to 90% of all reported SCLC cases, suggesting that tobacco components like nicotine contribute to the pathophysiology of this disease. Nicotine promotes the proliferation of human lung cancer cells via the alpha7-nicotinic acetylcholine receptors (alpha7-nAChRs). Therefore, we hypothesized that alpha7-nAChR antagonists should be useful in attenuating the growth of human SCLCs.

We observed that the small molecule alpha7-nAChR antagonist MG624 induced robust apoptosis in human SCLC cells as measured by TUNEL and caspase-3 cleavage assay. Furthermore, the administration of MG624 suppressed nicotine-induced growth of H69 human SCLC xenografts in athymic mice models. Immunohistochemical staining of the H69 tumor sections isolated from MG624-treated from athymic mice show the presence of apoptotic bodies.

Our data suggest that MG624 may have potential applications for the treatment of human SCLCs.

# **Wernicke's Encephalopathy in a Patient Following Bariatric Surgery**

Ross DeChant, Lynne Goebel

Department of Internal Medicine,  
Joan C. Edwards School of Medicine, Huntington, WV

Wernicke's Encephalopathy is a rare neurological condition caused by thiamine deficiency. It is characterized by ataxia, ophthalmoplegia, confusion, and short-term memory impairment. Although more common in alcoholics, Wernicke's Encephalopathy may present in individuals who have undergone restrictive weight-loss surgery.

A morbidly obese 63 year-old Caucasian male presented to the emergency department with double vision, generalized weakness, ataxia, memory loss, fullness, nausea, and vomiting. Past surgical history was significant for gastric sleeve resection and laparoscopic Roux-en-Y gastric bypass. After surgery, patient was instructed to take a daily multivitamin; however, he discontinued its use due to diarrhea.

Neurological examination revealed spontaneous upbeat nystagmus as well as difficulty with peripheral vision. Due to suspicion of Wernicke's Encephalopathy, the patient was immediately started on 100 mg intravenous thiamine. Laboratory tests were performed, which revealed a thiamine level of 1.1 ug/L (normal 4.0 - 20.0 ug/L). Intravenous thiamine treatment was continued and his nystagmus resolved. However, he still has residual subjective memory impairment.

A review of the literature reveals Wernicke's Encephalopathy to be a rare neurologic condition that develops in only 0.4% of individuals who have undergone restrictive bariatric surgery. There is no diagnostic test for Wernicke's Encephalopathy, thus a clinical diagnosis is essential. As the population becomes more obese and the number of bariatric procedures performed each year continues to rise, physicians must maintain a high level of suspicion for this disorder. If left unrecognized and untreated, Wernicke's Encephalopathy can be fatal.

## **Anticoagulation Management Dilemma.**

Yusof Elgaried, Ahmad Nusair

IM. Marshall University.

Our patient is a 57-year-old male with no significant past medical history. He presented with worsening dyspnea. Upon arrival to the emergency room he was hypoxic, tachycardic and confused. He had a CT scan of the chest which showed a left pleural effusion, pericardial effusion, pulmonary emboli and an aortic arch thrombus. Additionally the CT scan of the head revealed acute thromboembolic stroke. He was admitted to the ICU for administration of IV heparin. Our evaluation in the ICU revealed concerning clinical findings: superior vena cava syndrome, tachycardia with low blood pressure and pulsus paradoxus. Emergent transthoracic echocardiogram confirmed tamponade. Anticoagulation was held until after pericardiocentesis was performed and thrombocentesis was done shortly after. The bloody fluid that was retrieved revealed malignant cells, which were subsequently confirmed to be non-small cell lung cancer. Greenfield filter was not placed as Doppler studies of the lower extremities did not show deep venous thrombosis. Thoracic surgery attempted to perform a pericardial window but the fusion of pericardium and epicardium precluded success.

This patient was diagnosed with stage IV adenocarcinoma of the lung. CT imaging of the abdomen showed thromboembolic events involving both kidneys and spleen likely originated from the intaortic clot.

He received chemotherapy prior to his discharge, but unfortunately, shortly after that he was readmitted with worsening confusion, shortness of breath and pericardial and pleural effusions. At that point the patient's family elected to pursue comfort care measures and was discharged with hospice care.

This case highlights the value of clinical exam in the critically ill patient. The presence of pulsus paradoxus on exam changed the course of action from anticoagulation to pericardiocentesis and protected the patient from further bleeding into the pericardium, which could have had grievous consequences.

## **Epigenetic basis of pain in patients with endometriosis**

Kristeena Ray(1), Mardochee Isme(3), Melissa Massie(1), Carla Cook(1), Brenda Dawley(2), Nalini Santanam(1)

(1)Department of Pharmacology, Physiology, and Toxicology, Joan C. Edwards School of Medicine, Marshall University (2) Department of Obstetrics and Gynecology, Joan C. Edwards School of Medicine, Marshall University (3) Bluefield State College

Endometriosis is a clinical condition affecting women in their reproductive years. Cells from the endometrium appear and flourish outside the uterus, often causing severe pain, amongst other symptoms. Typically viewed as a hormonal disorder, new studies suggest that endometriosis may be an epigenetic disease. The major objective of this study was to investigate if epigenetic-mediated changes play a role in endometriosis-associated pain.

Peritoneal fluid from women with and without endometriosis (n=6) were used to treat endometrial cells (EM-42 and Ishikawa cell lines) for 48 hours. Global histone modification changes were detected using Western blots. The mRNA expression of nociceptors such as cyclooxygenase-2 (COX-2) and the capsaicin-sensitive pain receptor TRPV1 was detected using quantitative real-time polymerase chain reaction (qPCR).

Our results indicated changes in Histone 3 and Histone 4 modifications depending on the presence or absence of endometriosis-associated pain, with the most noticeable differences occurring at H4PanAc (K9 and K14), H3K27Me3, H3K9Me2 and H3K4Me2. PCR results also showed a >25-fold induction in the pain-associated genes in endometriotic tissue. A human miRNome array showed significant differences in over 30 miRNAs in endometrial tissue from endometriosis patients compared to controls.

Our findings provide evidence for epigenetic changes in patients with endometriosis-associated pain and may help identify epigenetic-based strategies for pain therapy in this and other indications.

## **Constraining function as a simple tool of reducing operating room traffic in a total joint room.**

Jonathon Salava, Ali Oliashirazi, Felix Cheung, and Kristie Winters.

Department of Orthopaedic Surgery, Joan C. Edwards School of Medicine, Huntington, WV.

Numerous operating room (OR) environment factors have been analyzed in the past in hopes of identifying areas of improvement for reducing rates of periprosthetic joint infections (PJIs) and surgical site infections. It is well established that increased operating room traffic is correlated with such infections. Our objective was to demonstrate that the use of a sign-in sheet for all traffic entering and exiting a joint replacement OR acts as an effective constraining function to limit traffic.

Operating room traffic, as measured by door openings during a total joint arthroplasty, was monitored in joint arthroplasty rooms over a three and a half month period for two surgeons. The control OR had doors marked with a "No Traffic" sign, and the constraining function OR was marked similarly, with the addition of sign-in sheets. From the time of incision to the time of wound closure, each door opening was recorded. For the constraining room, those entering or exiting were asked to sign in when opening the OR doors. OR personnel were unaware of the observer in the control room. Data was entered into a database and analyzed for significant differences in the mean and median number of door openings by using the Student's t-test and Mann-Whitney test.

A total of 129 primary total joint arthroplasties were performed (101 in the constraining OR and 28 in the control OR). There significantly ( $p < .00001$ ) fewer door openings per case in the constraining OR (mean 1.6, median 1) than in the control OR (mean 16, median 9.5).

By requiring personnel to sign in prior to opening the OR door, a constraining function has been effectively implemented resulting in significantly less OR traffic. Further study is needed to assess the clinical implications of introducing a constraining function to reduce PJIs.

## **Detecting forces in a reference frame: responses of stick insect campaniform sensilla to muscle forces and loads**

Chaudhry S, Bueschges A, Schmitz J, Zill SN

Dept. Anat. & Pathol., J.C. Edwards Sch. Med., HUNTINGTON, WV; Dept. of Animal Physiology, Zoological Inst., Univ. of Cologne, Cologne; Dept. of Biol. Cybernetics, Univ. of Bielefeld, Bielefeld

In control systems and models of the neural regulation of posture and locomotion, forces are often defined as vectors acting upon the center of mass within a body reference frame. However, forces are monitored predominantly by sense organs that detect loads at individual muscles or joints. We have studied how muscle forces and loads are detected by campaniform sensilla, receptors that detect forces as strains in the exoskeleton, in the legs of stick insects (*Carausius morosus*).

Forces are applied to the exoskeleton or to muscle insertions or tendons and sensory activity is recorded extracellularly from identified groups of receptors. Sensory activities are also monitored during spontaneous or evoked muscle contractions.

The trochanteral campaniform sensilla (Groups 3, 4) show vigorous discharges to resisted contractions of leg muscles and specific receptors discharge during force increases or decreases. Sensory discharges encode the amplitude and rate of forces generated by the trochanteral depressor muscle. However, discharges of the sensilla are elicited only when movement is blocked and do not occur when resistance is removed and the leg is allowed to move freely. Tests in which loads were applied simultaneously with muscle force showed higher frequency sensory firing that reflected the increase in resistance to muscle contractions. Mechanical stimulation of the receptors produced reflex effects in the slow depressor motoneuron that could reverse in sign.

These response sensitivities and reflex actions are, therefore, remarkably similar to those found in Golgi tendon organs of vertebrates. We have incorporated these findings into a new model of the information provided by campaniform sensilla: discharges to muscle forces and loads occur within the frame of reference of the leg plane, which reflects the vector plane of action of intrinsic leg muscles. This frame of reference could simplify the neural control and adaptation of posture and walking.

## **Cirrhotic Cardiomyopathy in Gastroenterology Clinic Patients with Liver Cirrhosis, MUSOM**

Tilahun Belay, Todd Gress, Rameez Sayyed

Internal Medicine, MUSOM

Cirrhotic cardiomyopathy is a clinical syndrome in patients with liver cirrhosis characterized by an abnormal and blunted response to physiologic, pathologic, or pharmacologic stress but normal to increased cardiac output and contractility at rest. Information on the epidemiology and natural history among cirrhotic patients is limited.

All patients with a diagnosis of cirrhosis (N=451) from our gastroenterology clinic during a 2 year period were evaluated for our study. Electrocardiography and echocardiograph reports were reviewed. Patients with features of diastolic dysfunction, with resting left ventricular ejection fraction >50% and with no structural cardiac disease were considered to have cirrhotic cardiomyopathy. 220 patients were excluded from our study due to structural or ischemic heart disease, hypertrophic cardiomyopathy, or with incomplete information leaving 231 patients.

Among 231 patients with cirrhosis, 118 (51.1%) had cirrhotic cardiomyopathy. Those with cirrhotic cardiomyopathy were older (62.7 vs. 57.8 years;  $p<0.001$ ) and have female sex (55.8 vs. 40.2%;  $p=0.02$ ) compared to those without cirrhotic cardiomyopathy. The likelihood of cirrhotic cardiomyopathy increased with each quartile of age (OR 1.6; 95% CI 1.2-2.0). The single most common cause of cirrhosis was attributed to unknown causes (39.4%), followed by alcohol abuse (27.3%) and viral hepatitis (15.5%). Patients with alcoholic cirrhosis are more likely to have cirrhotic cardiomyopathy than patients with unknown causes of cirrhosis, ( $p=0.00$ ). Cirrhotic cardiomyopathy was more commonly associated with alcohol abuse in men (73.0 vs. 41.8% female;  $p<0.001$ ) when compared to unknown cause.

Cirrhotic cardiomyopathy is a common, but often under diagnosed, problem among cirrhotic patients. Advancing age and female gender are associated with a higher prevalence of cirrhotic cardiomyopathy. A large number of patients have not had screening for cirrhotic cardiomyopathy. Awareness should be increased among providers to increase recognition and target therapy.

## **Applications of Next Generation Sequencing in Biomedical Science Research**

James Denvir, D. A. Primerano, G. Boskovic, J. Fan, T. Salisbury,  
J. Fletcher, C. Cuff and A. Cockburn

Biochemistry and Microbiology, Physiology, Pharmacology and  
Toxicology, JCESOM; Microbiology, Immunology & Cell Biology,  
SOM WVU

The Marshall University Genomics and Bioinformatics Core (GABC) provides (1) high throughput next generation sequencing (NGS) to support whole genome, RNA-Seq and ChIP-Seq studies, (2) microarray-based technologies including expression profiling, (3) biostatistical and bioinformatic support for NGS and microarray projects, (4) automated DNA sequencing, genotyping and RNA/DNA quality assessment and (5) access to RT thermal cyclers for quantitative PCR.

Our strategic plan includes a “full-service” model for the provision of NGS, microarray and bioinformatic services. Investigators meet with GABC staff to formulate experimental design at the start of a project. The GABC staff then performs wet lab, biostatistical and bioinformatic analysis. After completion of data analysis, we meet with the investigator to review the data and address any concerns about the analyses.

Since the acquisition of the Illumina HiSeq1000 next generation sequencer, the GABC has initiated RNA-Seq, ChIP-Seq, microbiome, whole genome and whole exome studies. In collaboration with one MU and one WVU lab, three NGS projects are highlighted in this presentation:(1) mRNA expression profiling of MCF-7 cells with and without the Aryl Hydrocarbon Receptor (RNA-Seq analysis),(2) Defining Aryl Hydrocarbon Receptor DNA binding sites in human MCF-7 breast cancer cells (ChIP-Seq analysis) and (3) Use of NGS to detect differences in the subgingival plaque microbiome in elderly subjects with and without dementia.

In the RNA-Seq and ChIP-Seq analyses, we were able to discover novel expression patterns and transcription factor binding sites under the regulation of the Aryl Hydrocarbon receptor. In the microbiome study, we were able to identify changes in oral microbial populations that correlate with dementia.



## **Grave's Disease: Typical Gone Atypical**

Jillian Douglas, Omolola Olajide

Department of Endocrinology, Marshall University

Graves' disease usually presents with common symptoms and signs that are distinctive. Atypical manifestations of hyperthyroidism are increasingly being recognized. The lack of knowledge of the association between these findings may lead to a delay or misdiagnosis, or result in unnecessary investigations.

We present a 50 year old female admitted for angina, dyspnea, orthopnea, nausea, vomiting, and palpitations. She had a previous diagnosis of atrial fibrillation which became uncontrolled with a rapid ventricular rate. During her hospitalization she developed abdominal pain. A CT abdomen showed bilateral pleural effusions, fatty infiltration of liver, ascites, and anasarca. She was noted to have an elevated alkaline phosphatase, total bilirubin, and AST. She developed hypoglycemia with worsening of her liver function tests and was transferred to a liver transplant center for impending liver failure. On the day of transfer, her TSH was notably undetectable with elevated free T3 and T4 levels. Thyroid antibodies were positive. Radioiodine scan of the thyroid showed diffuse uptake. Acute hepatitis panel and autoimmune work-up were negative. She was diagnosed with congestive hepatopathy and right sided heart failure attributed to Graves' disease.

The atypical manifestations of Graves' disease presents a broad spectrum of clinical and biochemical findings. Hepatic injury is thought to result from the hypermetabolic state which causes hypoxia in the perivenular regions increasing oxygen demand without an increase in blood flow. Thyroid hormones may also have a direct toxic effect on hepatic tissue. Graves' disease may present with atypical and under-recognized symptoms. Awareness about this is prudent to avoid misdiagnosis and unnecessary investigations.

**Emphysematous pyelonephritis: - a rare but serious kidney infection in a 54 year old male patient.**

Hailegiorgis Woldegiorgis, Peter Ottaviano

Department of Medicine, Joan C. Edwards School of Medicine at Marshall University, Huntington, WV

Introduction: - Emphysematous pyelonephritis (EPN) is a severe, life threatening necrotizing renal parenchymal infection that is characterized by the production of intraparenchymal gas. It predominantly affects females and diabetic patients. Patients with EPN are typically very ill with features of severe sepsis.

Case:- Here we report a case of EPN in 54 year old male diabetic patient who was referred to CHH ICU being sedated and intubated after he was found with altered mental status lying on the floor at his home. He had fever and right flank pain. He stopped taking his antidiabetic medicine for a year before his presentation. On examination he was febrile, tachycardic and hypotensive. He had tenderness on the right flank and RUQ regions. The CT scan of the abdomen showed gas within the upper cortex of the right kidney. Urine culture grew E. coli. Patient was treated first with antibiotic and since response was poor percutaneous drainage was performed following which the patient condition improved and he was discharged from the ICU.

Conclusion:- EPN is a rare, life threatening condition that needs a high index of suspicion to consider it in the differential diagnosis of a diabetic patient with urosepsis. Percutaneous drainage should be considered as early as possible in a patient not responding well for the medical management.

## **Traumatic Laryngeal Fracture in a Collegiate Basketball Player**

Jeffery D. Kim, Franklin D. Shuler, Bi Mo, Scott R. Gibbs,  
Tom Belmaggio, Charles E. Giangarra

Department of Orthopaedic Surgery, Marshall University

Laryngotracheal trauma is a rare condition that accounts for less than 1% of blunt trauma. Laryngotracheal fractures are uncommon in sports, even in settings where athletes are more vulnerable including football, basketball and hockey.

A 21-year-old male collegiate basketball player jumped for a rebound and while descending was struck in the larynx by a teammate's head causing a brief episode of shortness of breath. Following the initial impact, he was evaluated by the athletic trainer and became dysphonic (hoarse) and developed hemoptysis (coughing up blood). Solu-medrol was given with breathing improved by continued hoarseness, blood-streaked sputum, difficulty swallowing, and over the next few hours, experienced shortness of breath with mild stridor. He was sent to the emergency department with evaluation showing tenderness along the thyroid lamina and anterior cricoid ring with subcutaneous emphysema. He was admitted with CT scan demonstrating minimally displaced fracture of the left thyroid lamina, fracture of the anterior thyroid cartilage with subcutaneous air. Fiber optic evaluation demonstrated a normal superior glottis larynx without mucosal laceration. He was admitted to the ICU but did not require surgical airway management and was discharged in 5 days.

If a laryngeal injury is suspected, immediate evaluation is required to avoid a delay in the diagnosis of a potentially life-threatening injury. A collegiate basketball player sustained an unusual fracture involving both the cricoid and thyroid cartilage during practice. This case illustrates the importance of rapid identification and early management of patients with blunt laryngotracheal trauma in sports.

## Siunstitis isn't always simple

Yousef Hattab , Mohammad Al-Ourani , Yousef Shweihat

Internal Medicine

Bronchiectasis with recurrent Pneumonias and Sinusitis has limited differential diagnosis in the adult. We present a case of severe CVID that presented with these symptoms and was successfully treated with intravenous Immunoglobulins with marked improvement in symptoms. Although Commonly seen during childhood, doctors for adults need to be aware of this entity since it not uncommonly present in early adult life.

We describe a 39 y/o male pt with more than 3 years history of recurrent chest infections and sinusitis. He repeatedly presented 2 to 3 times a year complaining of either a green nasal discharge or a cough productive of yellow/green sputum. CT of the chest showed Bronchiectasis and Splenomegaly, which resulted in investigations to rule out secondary causes. He was diagnosed with severe CVID based on undetectable levels of all immunoglobulins IgG, IgM and IgA. He was started on immunoglobulin therapy (IVIG) and marked improvement was noticed with no more exacerbations .

Common Variable Immunodeficiency (CVID) is the most common form of severe antibody deficiency. It is characterized by reduced levels of IgG (<400 mg/dL) and low IgA and/or IgM levels, recurrent bacterial infections, impaired antibody responses despite the presence of B Cells and normal or near normal T cell immunity in 60% of patients. CVID can be associated with autoimmune, granulomatous and gastrointestinal diseases and patients have a predisposition to malignancies (especially non-Hodgkin lymphoma). There is a high mortality from infections without treatment. The main stay treatment is immunoglobulin replacement. Despite being a relatively rare condition, CVID can be easily treated with improved patients' prognosis. Doctors for adults should be aware of the condition as a differential diagnosis for individuals presenting with recurrent sinopulmonary infections.

# **AN UNCOMMON PRESENTATION OF AUTOIMMUNE THYROID DISEASE**

SHIRLEY TETTEH, OMOLOLA OLAJIDE

Department of Medicine, Marshall University Joan C. Edwards  
School of Medicine, Huntington, WV

Autoimmune thyroid disease (AITD) is a common specific autoimmune disorder seen mostly in women between 30-50 years of age. Thyroid autoimmunity can range from Hypothyroidism (Hashimoto's thyroiditis) to Hyperthyroidism (Graves' disease). Graves' disease is characterized by thyroid hyper secretion and cellular hyperplasia caused by thyroid-stimulating antibodies. Chronic autoimmune thyroiditis is often characterized by thyroid-cell destruction. The presentation of AITD might be determined by how various circulating and local thyroid antibodies interact with each other and which antibody predominates.

We report a case of a 36 year old female with a history of hyperthyroidism which resolved after a few months. She had elevated levels of Thyroid peroxidase, Thyroglobulin and Thyroid stimulating antibodies. She remained euthyroid but less than a year later, she became pregnant and her TSH level became minimally elevated. She was then started on thyroid hormone therapy (thyroxine) for Hashimoto's Thyroiditis and the dose was increased once during her pregnancy. About three months post-partum, her TSH became persistently suppressed despite reduction and discontinuation of the thyroxine. Her free T3 was also elevated. Her Thyroid scan showed an elevated uptake and she was subsequently started on Methimazole for Graves' disease. She then became Hypothyroid on treatment after a few months and then the Methimazole was discontinued. She has since returned to a euthyroid state.

The clinical spectrum of autoimmune thyroid disease is broad. Affected persons may have hyperthyroidism, hypothyroidism or may be euthyroid. The key issues in a patient with autoimmune thyroid disease are the level of thyroid hormone secretion and the balance between the Thyroid antibodies that are present. This is because therapy is currently directed at reducing or replacing thyroid hormone secretion rather than treating the cause of the abnormal secretion.

# **Biomimetic Nanofiber Scaffolds for Tendon-to-bone Insertion Repair**

Bing Ma<sup>1</sup>, Franklin D. Shuler<sup>2</sup>, Jingwei Xie<sup>1</sup>

1. Marshall Institute for Interdisciplinary Research and Center for Diagnostic Nanosystems, Marshall University, Huntington, WV 25755 USA. 2. Department of Orthopaedic Surgery, Joan C. Edwards School of Medicine, Marshall University, Huntington, WV 25701 USA

The attachment of tendon to bone takes place across the insertion site, a complex, millimeter-sized transitional tissue with gradations in structure, composition, and mechanical behavior. Around 300,000 rotator cuff tendon repairs are performed annually in the United States with failure rates ranging from around 20% to 90%. Development of scaffolds which mimic the structure and/or composition of tendon-to-bone insertions could benefit the repair of rotator cuff injury.

1. Fabrication of nanofiber scaffolds with dual gradients in mineral content and fiber orientation which were capable of mimicking both the composition and structural organization at tendon-to-bone insertion site using electrospinning and mineral deposition.
2. Adipose-derived stem cells (ADSCs) culture on scaffolds.
3. Implantation of scaffolds in a rat rotator cuff injury model.

1. We demonstrated the fabrication of nanofibers scaffolds with dual gradients in mineral content and fiber orientation.
2. Preliminary ADSCs culture study indicates that more cells attached on the site with high mineral content and fewer cells attached on the pristine poly(e-caprolactone)(PCL) fibers. In addition, cells on the pristine nanofibers displayed poor cell spreading. In contrast, cells spread well on high mineral coating site, presenting evident filopodia structures.
3. The scaffolds were implanted to the tendon-to-bone insertion site in a rat model. The end with high mineral content was inserted into the bone tunnel. The end without mineral content was sutured to the supraspinatus tendon.

We have demonstrated the fabrication of nanofiber scaffolds with gradations in both mineral content and fiber organization. More ADSCs attached and repopulated at the end with high mineral content, while fewer cells attached and repopulated at the end without minerals. The scaffold was suitable for the implantation to tendon-to-bone insertion site in a rat rotator cuff injury model.

## **Capnocytophaga infection involving mediastinal lymph nodes and lung mass in a patient with a primary lung cancer diagnosed with EBUS TBNA with associated leukemoid paraneoplastic syndrome**

Amar Panchal, Yousef Shweihat, Ahmad Nusair

Pulmonary Department, VA Medical Center, Huntington, WV  
and Marshall University

A 62 year old white male with 47 PPY smoking history, h/o bladder cancer s/p chemoradiation presented with complaints of cough, shortness of breath, mild intermittent hemoptysis and generalized fatigue since 2 months. He had experienced 7 lbs weight loss and night sweats. CT Chest showed a left lower lobe 6x7 cm lung mass with bilateral hilar and mediastinal lymphadenopathy. Suspecting possible infection, the patient was started on intravenous ampicillin-sulbactam. Endobronchial ultrasound guided real time sampling (EBUS-TBNA) of the lymph node stations R11, L11 and 4 and 7 as well as lung mass was performed. Biopsies were sent for cultures. He declined chemotherapy and was ultimately referred to hospice. **RESULTS:** WBC 34K, rest of blood counts and chemistry parameters were unremarkable. Sputum and blood cultures remained negative. Cultures from lymph node and lung mass grew copious amount of capnocytophaga species in aerobic media. Cell block examination of biopsy from all lymph node stations and lung mass revealed poorly differentiated lung cancer. Platelet count increased from 330 to 637 over 4 months. WBC remained high in spite of antibiotic treatment although he never developed progressive signs of infection.

To our knowledge, this is the first case of capnocytophaga infection involving mediastinal lymph nodes and lung mass. Capnocytophaga is a gram negative rod which usually presents as sepsis and bacteremia in immunocompromised hosts, usually transmitted from dogs and cats. The leukocytosis was due to paraneoplastic syndrome. This case also highlights the potential role of EBUS in diagnosing lung and mediastinal infections, particularly when other routine methods are unrevealing.

**Conclusion:** This case is unique as its first reported case of capnocytophaga infection in lung mass and mediastinal lymph nodes, associated with leukemoid paraneoplastic syndrome and highlights potential role of EBUS in diagnosing infections of lung and mediastinum.

## **Incidental Discovery of Osteosarcoma of the Jaw at Annual Dentist Visit**

Carly Schuetz, Kimberly Weaver, Eva Patton-Tackett.

Department of Internal Medicine, Joan C. Edwards School of Medicine, Huntington, WV.

Osteosarcoma is a malignant bone-forming tumor with approximately 750 cases diagnosed annually in the United States. Osteosarcoma of the jaw is a rare subtype of this malignancy, accounting for less than 6.5% of osteosarcomas. Although they share a common name, osteosarcoma of the jaw behaves more aggressively than its long bone relative. It typically presents during the fourth decade with facial swelling, localized pain, and paresthesias. Benign bone tumors have a similar radiologic appearance, making diagnosis challenging. The mainstay of treatment for osteosarcoma of the jaw is surgery with wide resection margins and subsequent chemotherapy. With such management, five year survival rate is 70%.

A 25-year-old Caucasian female presented to the dentist for annual check-up where panoramic x-ray revealed mass of the right mandible. The lower right second molar was extracted, and biopsies of the mandibular mass revealed atypical cells likely representing benign fibrous dysplasia. Cone Beam CT showed significant tooth resorption and inferior alveolar nerve canal destruction.

Partial mandibulectomy was performed. A second procedure was required to achieve wider resection margins. Pathology revealed high-grade osteosarcoma with perineural invasion. Resected lymph nodes showed no evidence of malignancy. Final tumor stage was T1N0MX Grade 3, Stage IIA. Patient underwent 30 weeks of chemotherapy with cisplatin, adriamycin, and high-dose methotrexate. The latest PET scan showed no evidence of disease.

Our case is particularly interesting as this asymptomatic patient was diagnosed from routine dental screening. She was younger than the average individual presenting with osteosarcoma of the jaw. Due to early misdiagnosis, an additional procedure was required to achieve proper tumor margins. Biopsy must be completed at time of initial surgery to ensure clear margins and avoid tumor seeding. Physicians must maintain a high level of suspicion for osteosarcoma so that early diagnosis can be made and aggressive treatment initiated.



## **Chronic Gallstone Ileus: How Long Can It Keep Silence?**

Nan Zhang, Walker Johnson, Sarah Burke,  
Rebecca Wolfer

### **Surgery**

Gallstone ileus is an important, though infrequent cause of acute or subacute mechanical bowel obstruction. We report one case with long term presence of a large gallstone in gastrointestinal tract for over 6 year before presenting for surgical evaluation.

The patient is a 56 years old white female with a history of a hysterectomy 12 years ago, presented small bowel obstruction symptoms for 3 days. A CT scan revealed small bowel obstruction with a transition point in pelvis and a calcified "foreign body". The "foreign body" in per pelvis was verified on a KUB film 6 years. She underwent exploratory laparotomy. Dense pelvic adhesions and enterovaginal fistula were identified between the vaginal cuff and the small bowel. A large calcified foreign body (3 x 2 cm) was present intraluminal proximal to the fistula, which was resected. Chemical component analysis confirmed the foreign body is gallstone.

Fifty to 70 percent of gallstones impact in the ileocecal valve, which is the narrowest segment of the intestine. The jejunum and stomach are the next most frequently affected sites. There is no previous report of long term gallstone in the gastrointestinal tract resulting in a gallstone ileus

This patient was discovered to have gallstone located proximal to an adhesive small bowel stricture secondary to her previous hysterectomy. Transient gallstone impaction produced obstructive symptoms, which subside as the gallstone becomes disimpacted from the dilated bowel. The recent vaginal enteric fistula brought her to medical attention and the diagnosis was made. Thus, gallstone ileus should always be in the differential diagnosis when assessing a person with intestinal obstruction. CT and careful physical examination are helpful in the diagnosis of gallstone ileus with atypical presentation.

## **Investigation of RGS16 mediated inhibition of pancreatic cancer metastasis**

Miranda B. Carper<sup>1, 2</sup>, Goran Boskovic<sup>1, 2</sup>, James Denvir<sup>1, 2</sup>, Donald Primerano<sup>1, 2</sup>, and Pier Paolo Claudio<sup>1,2,3</sup>

1 Department of Biochemistry and Microbiology, Marshall University, Huntington, WV., 2 McKown Translational Genomic Research Institute, Marshall University, Huntington, WV., 3 Department of Surgery, Joan C. Edwards School of Medicine, Marshall University, Huntington, WV.

Pancreatic cancer is ranked as the fourth cause of cancer-related deaths in the United States with a five-year survival rate <5%. This is due, in part, to early systemic dissemination. Due to the aggressive nature of this disease, new therapies are needed to inhibit and treat metastatic pancreatic cancer. We have previously performed a microarray analysis to determine proteins regulated by the tumor suppressors p53 and pRb to identify proteins involved in the p53 and pRb cross-talk pathway. We have found that the expression of the Regulator of G-protein signaling (RGS16) is stimulated by both p53 and pRb in WI38 normal lung fibroblast cells. RGS16 turns off signaling of several oncogene pathways that are involved in proliferation, chemoresistance, migration, and invasion. Recently, it has been found that RGS16 is downregulated in metastasized pancreatic cancer suggesting that RGS16 could be involved in inhibiting proteins responsible for promoting metastasis of pancreatic cancer.

In order to investigate the role of RGS16 in inhibiting pancreatic cancer migration and invasion, RGS16 was over-expressed in ASPC-1, BxPC-3, and PANC-1 pancreatic cancer cell lines. Impact of RGS16 over-expression on migration and invasion, were investigated using wound-healing assays and Boyden chambers, respectively.

Our data indicates that RGS16 is regulated by both p53 and pRb and that overexpression of RGS16 inhibited pancreatic cellular migration and invasion, which are hallmarks of the metastatic process.

We are in the process of elucidating the mechanisms by which RGS16 can inhibit pancreatic cell migration and invasion, which could lead in the future to novel anticancer modalities for this lethal disease.

## **AN UNUSUAL CASE OF CONCOMITANT ACHALASIA AND GASTRIC VOLVULUS IN AN 87 YEAR OLD FEMALE.**

Morgan Eckerd, Eva Patton-Tackett

Internal Medicine

Achalasia is a disease of unknown cause in which there is a loss of peristalsis in the distal esophagus and a failure of lower esophageal sphincter (LES) relaxation with swallowing. Gastric volvulus can occur in two axes - organoaxial (longitudinal) and mesentericoaxial (lateral). In addition, there are two types of occurrence. Type 1 most usually involves laxity of gastrosplenic, gastroduodenal, gastrophrenic, and gastrohepatic ligaments. Type 2 gastric volvulus usually associated with congenital or acquired abnormalities that result in abnormal mobility of the stomach.

This patient presented with a two day history of nausea and vomiting of undigested food. Initial radiologic evaluation consisted of barium swallow and CT chest. These studies were only indicative of obstruction at the level of the LES and para esophageal hernia. Initial endoscopy revealed a dilated lower esophagus with much undigested food matter and inability to pass the endoscope. Repeat EGD and evaluation were suggestive of the concomitant occurrence of achalasia and gastric volvulus. Exploratory laparotomy was performed and revealed organoaxial gastric volvulus and para esophageal hernia of the stomach. A PEG tube was placed for fixation of the stomach to the abdominal wall. EGD with injection of botulinum toxin was then performed for alleviation of significant LES achalasia. Five days post toxin injection, EGD showed mild stricture that was treated with balloon dilation. The patient has had a prolonged recovery and still requires PEG tube for nutritional purposes.

Acute gastric volvulus in the presence of achalasia is not common. In a preliminary literature review, the occurrence of these together appears to be very rare. Initial radiologic evaluation is important and can hasten definitive diagnosis.

## **Outcomes Of Calcium Phosphate Bone Void Fillers: A Retrospective Analysis**

Alexander Salazar, Felix H. Cheung

Orthopaedic Surgery Marshall University Joan C. Edwards School of Medicine

The purpose of this project is to review the outcomes of bone tumor patients treated with calcium phosphate bone void fillers (BVF). Often, large cavities are left behind after a curettage of bone tumors, and BVFs are thought to provide temporary strength and a scaffold for new native bone to regrow.

In this retrospective analysis, three years worth of patients with bone void fillers were examined for fracture, recurrence, infection, other complications, and remodeling potential. Patients' charts from 2008-Present were reviewed and the operative notes, surgical pathology reports, and follow up notes were used to gather information used as outcome assessment criteria. X-Rays were reviewed and trends of remodeling were noted. A total of 24 patients (8 male:16 female) met inclusion criteria using a specific kind of BVF called BSM. The patients in the study had a mean age of 29.42 years, range of 7 to 73 years, the mean volume of BVF used was 20.07 ml, and 18/24 patients were repaired with the aid of hardware. 5 out of 24 were low grade malignant tumors.

We had a mean follow-up time of 3 months (range 2 weeks to 9 months). There were no instances of local recurrence. There were no instances of fracture or hardware failure. There were no infections. There was one instance of surgical revision due to scar tissue build up and one instance of limited recovery that caused patient problems.

All cases followed an acceptable rate of reabsorption. We were able to conclude that BVF is a safe with and effective means of repairing bone voids, with no instances of recurrence or fracture.

## **Negative Pressure Wound Therapy and External Fixator Pins: A New Technique for Proper Sealing Around the Pins**

Jerry Ambrosia, Pooya Hosseinzadeh, James Day

Department of Orthopaedic Surgery, Joan C. Edwards School of Medicine, Huntington, WV.

The application of negative pressure wound therapy (NPWT) as delivered by V.A.C. (KCI, San Antonio, TX) has expanded tremendously in the past decade and is currently used for treatment of soft tissue injuries associated with open fractures. These high energy fractures usually cannot be treated definitively in the early stages due to poor soft tissue coverage and are temporized with external fixation. Obtaining the seal needed for NPWT can be challenging and even difficult around the external fixator pins. Introduction of this technique has been tremendously helpful in facilitating the seal needed for the NPWT around the pins.

Obtaining a seal around the external fixator pins can be challenging. The following technique has been helpful in our practice and has made sealing around the pins much easier after application of external fixation. The V.A.C. sponge (KCI, San Antonio, TX) is fashioned based on wound depth and shape and applied to the wound. The transparent drape in the V.A.C dressing kit (KCI, San Antonio, TX) is used to secure the sponge and obtaining seal on the skin edges. DuoDERM CGF dressing (Convatec, Skillman, NJ) is fashioned and molded around the pin sites as shown in the image. DuoDERM (Convatec, Skillman, NJ) is easily molded and will firmly adhere to the pins making the seal around the pins secure. SensaTRAC pad in V.A.C dressing kit (KCI, San Antonio, TX) is then applied over a hole in the sponge and connected to the V.A.C. suction canister.

The above mentioned technique can be helpful in selected cases when V.A.C dressing (KCI, San Antonio, TX) is applied around the external fixator pins and has dramatically simplified the process of obtaining a durable seal around these problematic areas.

Negative Pressure Wound Therapy (NPWT) can be more easily applied around the pin sites with this technique.





**POSTER PRESENTATIONS • SESSION II • 2:30 PM – 3:15 PM**

# **25TH ANNUAL RESEARCH DAY POSTER SESSION**

## **The incidence of intraventricular hemorrhage (IVH) and the utility of screening cranial ultrasounds (US) in infants born between 30 0/7 - 32 6/7 weeks gestation.**

Sean Loudin, Ashley R. Jessie, Joseph V. Russo

Department of Pediatrics, Joan C. Edwards School of Medicine,  
Huntington, WV

Intraventricular hemorrhage (IVH) continues to be a serious morbidity for many premature infants. There is a growing body of evidence that any form of IVH can impact neurodevelopmental outcomes. In 2002 a practice parameter for screening premature infants for IVH recommended that infants born < 30 weeks gestation receive a cranial ultrasound between 7 -14 days of life, and optimally repeated between 36 and 40 weeks' postmenstrual age. Our institution has a more conservative screening approach, with screening ultrasounds performed at 1, 2, 4, and 8 weeks of life in infants < 32 weeks gestation.

A retrospective chart review was conducted. Dates ranged from 2008-2012. Patients were stratified into 2 groups: those infants < 30 weeks and those infants 30 0/7 to 32 6/7 weeks gestation. We also aimed to predict the cost savings of restricting our own institution's policies to coincide with the practice parameter.

There were 271 infants included in the < 30 weeks group and 155 infants included in the 30-32 week group. The incidence of IVH in the < 30 week infants was 14.4%, while the incidence of IVH in the 30 - 32 week group was 2.6%. The projected cost savings for conforming to the practice parameter is approximately \$118,000 per year at our institution.

The incidence of IVH in our patient population is lower than that which is commonly reported throughout the literature. This quality improvement project demonstrates that conforming to the suggested practice parameter will save our NICU a significant cost burden. It also demonstrates that we are not likely to miss a significant number of hemorrhages by restricting our current conservative management practice.



## **Expressive aphasia as a presentation of Mycoplasma encephalitis in a young adult patient**

Ameen Alshareef, Laura Wilson, Maria G. Lopez Marti

Pediatrics

Encephalitis is the most common extra- pulmonary manifestation of Mycoplasma pneumoniae infection. Recent studies have suggested that Mycoplasma is implicated in approximately 5-10% of cases of pediatric encephalitis (Domenech C, 2009). One of the reasons it can be relatively difficult to diagnose is that it has the ability to present with a wide range of signs and symptoms. Expressive aphasia is an uncommon symptom of Mycoplasma encephalitis and has rarely been reported (Lin, 2002).

In this case study, we describe a previously healthy 16 year- old girl that presented with a history of headache, nausea, vomiting and acute expressive aphasia. This presentation resulted in an extensive work- up to determine the underlying etiology, that yielded the final diagnosis of Mycoplasma encephalitis by serologic studies. The patient responded quickly to treatment with levofloxacin and prednisone.

This case study helps to show the potential range of neurologic complications that can be seen with Mycoplasma infections in the pediatric and young adult population. Furthermore, it demonstrates the importance of including Mycoplasma infection in the differential diagnosis for unusual and otherwise unexplainable neurologic presentations. Further studies are needed in order to understand the pathophysiology of Mycoplasma encephalitis, its epidemiology, long-term outcome and ultimately define the best treatment course.

## **Hibernoma: A Rare Adipocytic Tumor**

Saqib Ahmed, Felix Cheung

Department of Orthopaedic Surgery

Hibernomas are benign tumors composed of brown adipose tissue, as opposed to lipomas which are composed of white adipose tissue. Brown fat is the principal source of thermogenesis in hibernating animals and serves as a source of heat in newborn infants.

Adipocytic tumors like lipomas are common, affecting about 1% of the population, whereas hibernomas are much more rare, accounting for just 1% of all adipocytic tumors. Hibernomas are non-functional, and they generally occur in locations where brown adipose once existed such as the back, thighs, and arms but can occur anywhere. Diagnosis is based on biopsy and definitive treatment is marginal excision.

A 54 year old man with a past medical history significant for obesity, smoking, and basal cell carcinoma presented to his primary care physician with a chief complaint of a nontender, growing, doughy mass in his right humerus for the past year. An MRI with contrast was ordered, showing a 14x7 cm mass with fatty characteristics located medial to the biceps along the humeral diaphysis. Because of abnormalities in the fat signal in the tumor, diagnoses other than lipoma were entertained, including hibernoma and liposarcoma. A core needle biopsy revealed the diagnosis of hibernoma based on the findings of brown fat. No evidence of malignancy was found. Excisional surgery took place without complications. At his 6-week follow up he was doing well. MRI will be performed at 12 weeks post-op for baseline measurements.

In summary, hibernomas are a rare but known fatty tumor. While the vast majority of adipocytic tumors are lipomas, tumors that exhibit growth to a size greater than 5cm, abnormal MRI fat signal, or tenderness should be evaluated by a trained musculoskeletal oncologist for possible biopsy and removal.

## **Avascular Necrosis of the Femoral Head in a 27 year old male**

Chad Lavender, Felix Cheung

Department of Orthopaedic Surgery, JCESOM

Avascular Necrosis of the hip in a young patient is frequently misdiagnosed or undiagnosed, leading to devastating consequences such as femoral head collapse. This might have been avoided with proper management, such as core decompression or bisphosphonates. The purpose of this case report is to highlight the topic of AVN and review the literature and our protocol for evaluation and treatment.

A 27 year-old male presented to our clinic for a 2nd opinion on his sharp right groin pain for 2 months, worse with weightbearing and activities. He was seen at another facility previously, and was given the diagnosis of hip strain and treated conservatively. The patient's history included excessive alcohol use several years ago, but not recently, and no history of steroids or hypercoagulable disorders. Examination showed only 10 degrees of internal rotation with a painful end point. Radiographs from the outlying facility showed a cystic lesion in the right femoral head, with a visible fracture line with no femoral head flattening or degenerative changes. An MRI of both hips was now ordered, showing signal abnormality within the right femoral head, consistent with cystic AVN, Ficat stage II. He was treated with a core decompression with calcium phosphate injection. The patient is now 6 months post-operative and show no signs of radiographic collapse. His is currently weightbearing as tolerated with mild groin pain.

This case highlights the need to have a high index of suspicion for AVN in a younger patient with hip pain, as well as the importance of obtaining a full history prior to prolonged conservative management. We recommend routine radiographic imaging if there is hip pain. If those are negative, we recommend an MRI if there is continued pain for more than 2-3 months.

## **Role of Renal Cytochrome P450 Isozymes in the Bioactivation of 3,5-Dichloroaniline In Vitro**

Christopher Racine, Travis Ferguson, Sukanya Baksi,  
Dianne Anestis and Gary O. Rankin

Department of Pharmacology, Physiology and Toxicology,  
Marshall University

Chlorinated anilines are common intermediates in the production of agricultural chemicals, dyes, industrial compounds, and pharmaceuticals. Some chloroanilines can induce nephrotoxicity in vivo and in vitro. Previous studies have shown 3,5-dichloroaniline (3,5-DCA, 1.0 mM) induced nephrotoxicity in isolated renal cortical cells (IRCC) following 90 min exposure. Studies from our lab have also shown IRCC pretreated with non-selective cytochrome P450 (CYP) inhibitors [piperonyl butoxide (1.0 mM) and metyrapone (1.0 mM)] partially attenuated 3,5-DCA toxicity, suggesting that CYPs may play a role in 3,5-DCA bioactivation. The purpose of the present study was to further explore the role of CYP mediated 3,5-DCA bioactivation using an in vitro rat model.

IRCC were obtained from male Fischer 344 rats. IRCC ( $4 \times 10^6$  cells/ml; 3mL) were incubated with shaking for 90 min with either dimethyl sulfoxide (DMSO) or 3,5-DCA (1.0mM). IRCC were pretreated with various CYP inhibitors [isoniazid (1.0 mM), ketoconazole (0.1 mM), omeprazole (0.01 mM), diethyldithiocarbamate (DEDTCA; 0.1 mM), oleandomycin triacetate (0.5 mM), or sulfaphenazole (0.1 mM)] and cytotoxicity was determined by measuring lactate dehydrogenase (LDH) release.

Pretreatment with DEDTCA, omeprazole, and sulfaphenazole partially attenuated 3,5-DCA induced nephrotoxicity, while ketoconazole, isoniazid, oleandomycin triacetate did not alter 3,5-DCA induced nephrotoxicity.

Studies in rats, have shown that DEDTCA, omeprazole, and sulfaphenazole are effective inhibitors of the CYP2C family isozymes. These results suggest that 3,5-DCA is bioactivated via multiple pathways, one of which involves the CYP2C family. (Supported by NIH Grant 8P20GM103434 to the West Virginia IDeA Network for Biomedical Research Excellence)

## **The use of Polyflex Stents in Refractory Benign Esophageal Strictures**

Douglas von Allmen, Rezwan Ahmed, Yaser Rayyan

Bachelors of Science in Biology Ursinus College, Marshall University  
Joan C. Edwards School of Medicine

Common causes of benign esophageal strictures include gastroesophageal reflux disease (GERD), radiation, sclerotherapy, caustic ingestion, and surgical anastomosis. Strictures refractory to standard dilation require additional therapies for symptom relief. We describe the use of a retrievable polyflex stent in a patient with esophageal strictures unresponsive to multiple balloon dilations.

A 58-year-old male with a history of coronary artery disease, duodenal ulcers, and GERD presented with dysphagia, vomiting, and choking. Esophagogastroduodenoscopy (EGD) revealed multiple ulcers in the esophagus and duodenum and proton pump inhibitor (PPI) therapy with Esomeprazole was initiated. Six months later he presented with solid dysphagia and bolus food impaction. EGD revealed multiple new benign strictures in the proximal, middle and distal esophagus, likely secondary to GERD. Monthly balloon dilations over 6 months failed to resolve the strictures. Due to the refractory nature of the esophageal strictures, a 15cm x 16mm polyflex stent was placed across the strictured areas for one month then removed. The patient has been asymptomatic and did not require follow up for additional stricture dilation for 15 weeks.

Covered stents are indicated in malignant esophageal strictures, esophageal leaks, and fistulas. Initial therapy for benign strictures is balloon dilation. In refractory strictures, stent placement can provide an effective alternative to repeated dilation. A meta-analysis revealed improved dysphagia in 55.3% of patients over an average of 74 weeks after Polyflex stent placement. Stent migration occurred in 26.4% of patients.

The predictors for early stricture recurrence include non-peptic strictures, neoplastic and smaller stricture diameter. Early recurrence of peptic strictures correlates with persistent GERD despite use of PPIs. Complications of stent placement include migration, chest pain, bleeding, perforation, tracheal compression, ulceration, food bolus obstruction and patient intolerance. Dilatation therapy remains the initial therapy for benign esophageal strictures, but retrievable stents may have a role in refractory cases.

## **Ectopic Pregnancy in A Previous Cesarean Section Scar: A Case Report**

Jared Brownfield

Department of Obstetrics and Gynecology,  
Joan C. Edwards School of Medicine

Implantation of materials of conception in the scar of a previous cesarean delivery is the least common form of ectopic pregnancy. This occurs when an embryo is found embedded in the myometrium where there is a previously existing cesarean scar from hysterotomy. Such a finding carries serious potential risks such as uterine rupture, scar dehiscence, hemorrhage, disseminated intravascular coagulation, and maternal death. While the true incidence of this condition remains yet unknown it is being reported more often as cesarean delivery rates increase. Published literature on the diagnosis and management strategy of ectopic pregnancy in a cesarean scar varies.

We present a 33 year old G3P2002 with vaginal bleeding and an inappropriately low B-hCG serum level for expected gestational age. Ultrasonography revealed a gestational sac in a cesarean section scar with no evidence of fetal pole. The patient underwent successful treatment with systemic methotrexate. Serial B-hCG quantity levels decreased as expected and the patient's course remained uncomplicated.

Considering the serious nature of this complication of pregnancy, the aim of this study is to review the potential presentations, diagnostic modalities, and management strategies. This will be done by presenting a recent case that was successfully diagnosed and treated with ultrasonography and chemotherapy.

## **Diffuse Alveolar Hemorrhage as the First Presentation of Wegener's Granulomatosis.**

Obaeda Harfoush, L. Eric Carter, Fuad Zeid, Nancy Munn

Huntington VAMC, Joan C .Edwards School Of Medicine at Marshall University, Huntington, WV

Bleeding into the alveolar space characterizes the syndrome of Diffuse Alveolar Hemorrhage (DAH) and is due to disruption of the alveolar-capillary basement membrane. hemoptysis is the usual presenting symptom , however it is not always present, even when hemorrhage is sever.

An 80-yo white male was admitted with 2 weeks of increasing hemoptysis and dyspnea on exertion for 4 months. Other symptoms included mild fatigue, dark urine and a weight loss of 10 lb over few weeks. His symptoms were refractory to outpatient antibiotic therapy. Physical exam was unremarkable except for bilateral bronchial sounds with crackles, and mild erythema of both ankles. Lab evaluation showed mild anemia, elevated BUN and Creatinine with initial urinalysis showing mild proteinuria, microscopic hematuria and hyaline casts. CXR and CT chest showed bilateral alveolar infiltrates consistent with diffuse alveolar hemorrhage pattern. subsequent bronchoscopy with sequential BAL and cytology supported the diagnosis of DAH. ANA, Anti-GBM and Anti-DNA were negative. C-ANCA was positive, Antiproteinase 3 antibodies were 13.8units/ml(0.0-3.5) consistent with the diagnosis. Unfortunately, the patient had a very complicated course including several episodes requiring intubation and mechanical ventilation. Despite treatment with high dose steroids and plasmapheresis, the patient expired.

DAH due to pulmonary capillaritis in Wegener's Granulomatosis (WG) not frequently occurs during the course of the disease but can be the initial manifestation in up to 10% of patients. DAH can be life-threatening process and can rapidly progress to respiratory failure.

Evaluation for the etiology of the process should be promptly undertaken and therapy may sometimes need to be initiated empirically based on disease severity. steroids, Cyclophosphamide and /or plasmapheresis are the mainstay of therapy. Unfortunately, the prognosis for WG with DAH is worse than for WG alone.

## **Scedosporium apiospermum Invasive Cutaneous Infection in a Kidney Transplanted Patient.**

Alaa Gabi, Justin Tolbert, Elias Shattahi

Internal Medicine Residency Program,  
Marshall University School of Medicine

*Scedosporium apiospermum* is the anamorph, or asexual state, of the cosmopolitan fungus *Pseudallescheria boydii*. *S. apiospermum* is an emerging opportunistic pathogen, especially in organ transplant recipients.

A 44 year old patient with a previous history of PCKD and kidney transplant two years ago complicated by acute rejection, is maintained on mycophenolate and prednisolone. 2 weeks ago he noticed redness in the tip of his left foot. The said he usually wears his shoes for a long time. On admission the patient had no fever, examination of the left foot showed tender black headed papules on the distal part of the dorsum of the left foot extending into the interdigital space between the 4th and 5th toes with patches of redness and hotness in the left leg and thigh. This was associated with swelling. Lab studies were normal except for the elevated creatinine which is expected for this patient. A Punch Skin biopsy of the lesion was taken. Histopathologic examination showed a psoriasiform hyperplasia with compact hyperkeratosis and focal inflamed crust formation and abundant fungal organisms showing acute-angle branching, septate filamentous and budding forms. Concurrent culture grew *Scedosporium apiospermum*. Further evaluation of the didn't show disseminated disease.

*Scedosporium* is an emerging opportunistic pathogen, with a rising incidence due to the increased and prolonged use of immunosuppressives. In histopathology specimens, *Scedosporium* species can be indistinguishable from other hyalohyphomycetes including *Aspergillus* and *Fusarium* species. *Scedosporium* is resistant to traditional antifungal therapies including amphotericin B; however, some of the newer, broadspectrum medications such as voriconazole appear to be at least somewhat effective but in some cases debulking surgery could be the last resort.



## Ouabain-Activated c-Src as a Potential Biomarker for Salt-Sensitivity

Yanling Yan, Larry Dial, Joseph I. Shapiro, Jiang Liu

Departments of Pharmacology, Physiology and Toxicology and Internal Medicine, Joan C. Edwards School of Medicine

The relationship between dietary sodium, salt sensitivity and blood pressure (BP) is well established. Excessive dietary sodium intake significantly contributes to the development of resistant hypertension and tends to be more pronounced in typical salt-sensitive subgroup. The current methods for assessment of salt sensitivity are largely depended on patients' compliance. A simple rapid in vitro test without salt intervention would be desired. Circulating cardiotoxic steroids (such as ouabain) are significantly elevated under conditions such as high salt diet and renal insufficiency, as well as in a large portion (about 70-80%) of essential hypertensive patients.

Through ligand-modulated Na/K-ATPase/c-Src signaling, we recently demonstrated that impaired renal proximal tubular ouabain-Na/K-ATPase/c-Src signaling contributes to salt-sensitivity and salt-sensitive hypertension. Furthermore, ouabain-activated Na/K-ATPase signaling is not tissue-specific. We found that ouabain can activate c-Src in renal proximal tubules, cardiac and skin fibroblasts, and mononuclear white blood cells (mWBCs, lymphocytes and monocytes) in Dahl salt-resistant, but not in salt-sensitive rats (n=3-8 depends on type of tissues,  $p < 0.05$  or  $p < 0.01$ ). In isolated mWBCs from Dahl rats fed with low salt diet, ouabain (0.1, 1, and 10  $\mu\text{M}$ , for 15min) stimulated c-Src activation in the salt-resistant rats, which was not seen or in a much less degree in the salt-sensitive rats (n=8 per group per strain,  $p < 0.01$ ). In healthy normotensive volunteers, ouabain significantly activated c-Src in a dose-dependent manner (ouabain=0.1, 1 and 10nM, for 15min, n=12,  $p < 0.01$ ). The ouabain concentrations used in rat and human mWBCs were chosen because of the rat Na/K-ATPase  $\alpha_1$  subunit is significantly ouabain-resistant compared to ouabain-sensitive human  $\alpha_1$  subunit.

Since c-Src activation is the proximal step in ouabain-induced Na/K-ATPase signaling and inhibition of sodium flux, we suggest that ouabain-stimulated c-Src activation might have the potential to serve as a biomarker for salt sensitivity.

## **Bilateral Osteochondritis Dissecans of the Lateral Trochlea in the Knee of a 16 Year Old Female**

Chad Lavender, Charles Giangarra

Department of Orthopaedic Surgery Marshall University

Osteochondritis dissecans (OCD) of the trochlea of the knee is a rare condition. OCD is thought to be caused by a traumatic injury and most often affects the lateral aspect of the medial femoral condyle. This case report may strengthen the theory that osteochondritis dissecans of the knee may have some genetic or systemic etiology.

A 16 year-old otherwise healthy female visited our clinic after sustaining an injury to her left knee. She reported no locking, but felt frequent clicking. There was no previous injury or prior history of knee pathology. She had no complaints referable to her right knee on presentation. Her initial physical exam revealed a range of motion of 5° hyperextension to 130° of flexion at her knee without patellofemoral crepitation. She had tenderness to palpation along the medial joint line, as well as anterior aspect of the medial femoral condyle, but no tenderness over medial retinaculum or medial patellofemoral ligament. An MRI supplied by the patient revealed an osteochondral defect in the anterolateral aspect of the trochlea. Arthroscopic surgery was performed on the left knee and a 10 by 15 mm loose body with bony fragments was visualized and removed. A chondral defect in the lateral aspect of the trochlea was identified. The lesion was addressed by standard microfracture technique. At 3 months post-operative she was at home and noticed pain in her contralateral (right) knee. There was no history of a traumatic incident which lead to the new onset of knee pain. The patient was found to have a similar lateral trochlea chondral defect similar to the contralateral knee for which a microfracture was performed.

This report presents an unusual case of bilateral osteochondritis dissecans of the femoral trochlea in a female. Only four cases of bilateral OCD of the trochlea have been reported.

## **A 57 year-old male patient with a vague chest pain**

Atef El Gassier, Yousef Darrat, Supria Batra, Ellen Thompson,  
Mehiar El-Hamdani

### **INTERNAL MEDICINE/ MARSHALL UNIVERSITY**

The left coronary artery originates from the left coronary sinus of the aorta, and, after a single initial trunk (left main coronary artery), it gives rise to the left anterior descending and left circumflex coronary artery branches. The congenital anomalies of left main coronary artery in adults are not common and are usually casual findings of diagnostic angiographic studies, and its incidence has been reported to be 0.67 %.

We present a case report of 57 year old man who presented with complaints of sudden onset of intermittent episodes of moderate anterior mid-chest chest pain, described as pressure-like, radiating to the back, made worse by walking. Risk Factors; hypertension, obesity and sedentary life style, patient has normal physical exam, EKG showed normal sinus rhythm, slight intraventricular conduction delay, minor inferior repolarization disturbance, flat T wave in AVF and negative T wave in III, due to the persistent nature of this pain he underwent a stress test which demonstrated a moderate intensity small size anterior apical defect, consequently, left heart catheterization and CT Angiography were done and demonstrated a congenital abnormality where all the coronary arteries arise off a common origin arising off the right coronary cusp, which within a few mm, divides into a right coronary artery and an aberrant lad, which appears to pass between the aorta and the right ventricle before passing on top of the left ventricle, where it splits into star-like branching pattern into an lad equivalent, circumflex equivalent and several marginal branches.

Adult congenital anomalies of the coronary arteries are usually discovered as accidental findings of diagnostic angiographic studies. In addition congenital anomalies of coronary arteries can be associated with angina as well as risk of myocardial infarction, syncope and sudden cardiac death in certain cases. Therefore, recognition and appropriate management of coronary anomalies is of extreme importance.

## **Loeys-Dietz Syndrome - a rare cause of vascular aneurysm**

Tilahun Belay, Larry Dial, Paulette Wehner

Department of Internal Medicine, JCESOM, Marshall University,  
Huntington, WV

Loeys-Dietz Syndrome (LDS) is a rare, autosomal dominant connective tissue disorder characterized by craniofacial, cutaneous, skeletal and cardiovascular abnormalities. Before the description of the syndrome, many patients were classified as Marfan's syndrome due to similar phenotypical manifestations. LDS is characterized by multiple and aggressive arterial aneurysms.

A 61 year old white male patient presented with left chest pain of three weeks duration which is stabbing, radiating to the back, occurring with position changes and lasting about a minute. At age 43, he was diagnosed with Marfan's Syndrome and at age 55 he was reclassified under the newly described LDS due to multiple arterial tortuosities and aneurysms. On examination, he had pectus excavatum, multiple surgical scars on the chest, faint ejection systolic murmur at left upper sternal boarder, ventral abdominal hernia, a 4 cm pulsatile cystic mass in the right popliteal area and a large cyst on the right ankle. Based on the unusual presentation of symptoms and a high clinical suspicion, coronary computerized tomographic angiography was undertaken and a large aneurysm of the ascending aorta with thrombus was identified. He underwent aortic root replacement and right coronary artery bypass of the dehiscent right coronary artery. Currently he is well with regular follow up.

The patient presented with chest pain of three weeks duration worsened by positional changes. Complicated thoracic aortic aneurysm should be considered in the differential diagnosis chest pain, especially in patients with underlying connective tissue diseases.

## **AN INTERESTING CASE OF GRAVES' DISEASE IN A PATIENT FOLLOWING MORE THAN A DECADE OF HYPOTHYROIDISM**

M. Adeel Mahmood, Henry Driscoll

Dept of Internal Medicine, Section of Endocrinology, Joan C. Edwards School of Medicine, Marshall University, Huntington, WV.

We describe a patient with hypothyroidism who developed Graves' disease with hyperthyroidism.

A 55-year-old man was evaluated by endocrinology for undetectable TSH of  $<0.02$  microIU/ml (reference range, RR: 0.35–5.5) and elevated free thyroid hormone levels, free T4: 2.4ng/dl (RR: 0.9–1.7); free T3: 9.6pg/ml (RR: 2.3–4.2). Record review showed he was diagnosed with hypothyroidism on routine pre-operative screening for right hemicolectomy thirteen years earlier. He took oral levothyroxine replacement of 100 micrograms daily. TSH ranged 0.5–4.2 on same dose until fifteen months prior when TSH became suppressed. Subsequently TSH was persistently undetectable, and free thyroid hormone levels were high. Levothyroxine dose was gradually lowered and then discontinued 4 months earlier by the primary care physician.

On evaluation, he was having palpitations, heat intolerance, unintentional loss of over 30 lbs and constant fatigue. He was tachycardiac with warm sweaty hands. There was no lid lag or retraction. Skin showed vitiligo. Off levothyroxine, TSH was still undetectable, FT4=1.88ng/dl; FT3=8.3pg/ml. 24-hour radioactive iodine uptake-scan showed homogeneously-increased uptake of 44% (Normal uptake: 10–30%). Thyroid ultrasound showed heterogeneous thyroid with increased blood flow. Thyroid peroxidase antibody was 92IU/ml (RR: 0–34). Trab (Thyroid-receptor antibody) was 11.86 IU/l (RR: 0 – 1.75). Thyroglobulin antibody was absent. Methimazole 20mg daily was started, and patient was scheduled to return in 8 weeks.

Switches between hyperthyroidism and hypothyroidism have been described owing to autoimmune destruction of thyroid gland, shift from T<sub>sab</sub> (thyroid-stimulating antibody) to T<sub>bab</sub> (thyroid-blocking antibody) in hyperthyroidism to hypothyroidism, and very rarely shift of T<sub>bab</sub> to T<sub>sab</sub> in hypothyroidism to hyperthyroidism. Both T<sub>sab</sub> and T<sub>bab</sub> are Trab. In our patient we do not have baseline autoantibody titers. However, it is likely that the hyperthyroid state results from stimulating Trab. This case of transformation after twelve years of suppression illustrates the need for regular follow up of hypothyroid patients to prevent life threatening complications of hyperthyroidism.

## **Biphasic changes in Schaffer collateral fiber volleys during continuous high-frequency stimulation and burst stimulation: calcium-dependence of the early hyperexcitable phase**

Benjamin Owen, Lawrence M. Grover

Department of Pharmacology/Physiology/Toxicology,  
Marshall University

Activity-dependent changes in presynaptic axon function could be critical determinants of activity-dependent synaptic activity, including long-term potentiation, a widely-used model for studying synaptic changes that underlie memory formation. Previously, we showed that during 50 and 100Hz high-frequency stimulation (HFS), orthodromic fiber volley amplitudes transiently increased, peaking after ~10-20 stimuli, then sharply decreased with amplitudes depressed for the remainder of the stimulus train.

In this study, we measured activity-dependent changes in fiber volleys recorded through an extracellular electrode placed into stratum radiatum of hippocampal area CA1. Fiber volleys were isolated by applying 30 $\mu$ M 6,7-dinitroquinoxaline-2,3-dione (DNQX) to block  $\alpha$ -amino-3-hydroxy-5-methyl-4-isoxazolepropionic acid (AMPA)/kainate (KA) receptors. A stimulating electrode placed in stratum radiatum delivered HFS (160 stimuli delivered at 100Hz) or burst stimulation (160 stimuli delivered in short bursts of 4 stimuli at 100Hz, with bursts separated by 100-1000ms) to evoke fiber volleys. To assess the Ca<sup>2+</sup>-dependence of fiber volley changes during HFS, we recorded in normal artificial cerebrospinal fluid (ACSF, containing 2.0mM Ca<sup>2+</sup> and 2.0mM Mg<sup>2+</sup>), and in high (3.8mM) and low (0.2mM) Ca<sup>2+</sup> ACSF (Mg<sup>2+</sup> concentrations adjusted to keep total divalent cation concentration equal).

At short burst intervals (100 or 200ms, ie, theta burst stimulation), fiber volleys showed the same pattern of change seen with continuous HFS: early amplitude increase followed by later decrease. At longer burst intervals (500 or 1000ms), these changes were blunted or absent. Also, the early increase in fiber volley amplitude was Ca<sup>2+</sup>-sensitive, with a larger increase observed in high Ca<sup>2+</sup>-ACSF, and little or no increase observed in low Ca<sup>2+</sup>-ACSF. Changing extracellular Ca<sup>2+</sup> concentration did not affect the late depression in fiber volley amplitude.

These data indicate similar changes in fiber volley during continuous HFS and more physiological patterned stimulation. Our data also suggest involvement of a Ca<sup>2+</sup> or Ca<sup>2+</sup>-regulated conductance in the early increase in fiber volley amplitude.

## **Jimson weed toxicity in a West Virginia teen: a case study**

Kelly Melvin, David Hourani

Department of Psychiatry, Joan C. Edwards School of Medicine,  
Huntington, WV.

Jimson weed (*Datura stramonium*) has a number of toxic anticholinergic effects, the vast majority of which are accompanied by delirium with visual and auditory hallucinations. Coma, seizures and respiratory distress are not uncommon in cases of ingestion. These effects are mediated by tropane alkaloids located in all parts of the plant. Jimson weed is commonly found throughout West Virginia in gardens, fields, pastures and wooded areas. Due to its easy availability, many people use jimson weed as a drug, either by brewing the plant as a tea or by chewing parts of the plant.

The subject of this case study is a 15 year-old male with acute jimson weed poisoning, misdiagnosed with bath salt intoxication. He received treatment at two emergency departments, a pediatric ICU and was ultimately transferred to an inpatient psychiatric facility.

Recent years have seen the introduction of numerous synthetic drugs of abuse that can cause similar symptoms of altered consciousness and agitation and that do not show up on standard drug screens. Acute intoxication with jimson weed in a noncooperative or noncommunicative patient can be easily confused with more commonly seen drugs of abuse and lead to delays in diagnosis and possibly treatment. Jimson weed overdose has been successfully treated with activated charcoal and gastric lavage, with more serious cases requiring physostigmine. This case illustrates the necessity of including jimson weed overdose in the differential diagnosis of unexplained delirium in adolescents and highlights the importance of educating youth on the dangers of abusing wild plants.

## **Management of Esophageal perforation post dilation with self-expanding stents: A Case Report**

Aviral Roy, Hani Alkhankan, Rezwana Ahmed, Yaser Rayyan

Department of Internal Medicine, Section of Gastroenterology,  
Joan C Edwards School of Medicine, Marshall University

Esophageal perforation is a life-threatening condition that is often treated surgically. Placement of a fully covered esophageal stent has emerged as a minimally invasive option and an effective alternative. We present a case report on the successful management of an esophageal perforation after dilation for multiple esophageal rings and the importance of timely detection and appropriate management.

This is a 77 year old Caucasian female who came with solid phase dysphagia. Endoscopy showed multiple esophageal rings suspicious for Eosinophilic esophagitis; however multiple tissue biopsies were negative for tissue eosinophilia. Endoscopic dilation was carried out to expand the esophagus to 14-15 mm. Six months later patient had recurrent symptoms and repeat dilation was carried by an EGD guided balloon dilator. Post procedure a mid esophageal mucosal defect was detected endoscopically that was suspicious for perforation. This was confirmed by diluted barium swallow. Patient was immediately taken back to the endoscopy suite for stenting under fluoroscopic guidance. She had some mild chest pain and leucocytosis but no mediastinitis/effusion on day #4 as confirmed by CT. She was Discharged home but returned 4 days later with food impaction which was removed by upper endoscopy. Temporary gastrostomy tube was placed for nutritional support . The stent was removed after 4 weeks under endoscopic guidance with success.

Esophageal perforation is an unfortunate complication of any esophageal procedure. Stents can be used for diverse conditions such as malignant strictures, esophageal perforations/esophageal anastomotic leaks and tracheo-esophageal fistula's. Success rates for sealing the leak can be up to 80% for both iatrogenic perforations and post-surgical anastomotic leaks. Patient mortality is high due to the poor medical condition of these patients, with age not being a major predictor of mortality. Covered stents placed for a period of 4-6 weeks may be an alternative for treating benign esophageal perforations.



## **Anatomical evaluation of the retrograde fibular intra-medullary start point**

Franklin D. Shuler, Maria Serrat, Jason Dickerber,  
Thomas Fortney and Alex Caughran

Department of Orthopaedics and Anatomy, JCESOM and  
Marshall University

Fibular fractures that require surgery are commonly associated with swelling and additional fractures of the distal tibia. Surgical stabilization of these injuries is generally done with surgical incisions exposing the fracture site with hardware fixation of plate and screws. Recent advances have popularized the use of intra-medullary fixation of the fibula as a way to decrease the morbidity associated with the surgical approach while minimizing the risk to the fracture site blood supply important for healing. This study uses a cadaveric model system to anatomically describe the appropriate start point for intra-medullary fixation while providing radiographic landmarks to assist with intra-operative placement of hardware.

Cadaveric dissections were performed to identify the anatomical structures at risk, the “sweet spot” for fixation that produces a trajectory in line with the medullary canal, and radiographic landmarks for appropriate entry points.

13 pairs of matched cadaveric ankles were obtained from the Human Gift Registry at Marshall University. Figure 1 cannot be uploaded with this abstract but demonstrates the structures at the lateral ankle that surround the fibular start point for intra-medullary fixation.

Completion of cadaveric dissections are in progress at the writing of this abstract. Preliminary data indicate that the peroneal tendons are the anatomical structure at greatest risk for this surgical technique. Anatomical specimens have identified the sweet spot as the posterior tip of the lateral malleolus with current radiographic studies in progress.

## **Extraordinarily elevated serum levels of CA 19-9 and rapid decrease after successful therapy:**

Majd Kanbour, Yaser Rayyan

Department of Medicine, Gastroenterology

Carbohydrate antigen 19-9(CA19-9) is most valuable as a serum marker for pancreatic and biliary cancer, but increased concentrations occurs in several other gastrointestinal malignancies. However, high levels in benign conditions such as acute cholangitis, cholelithiasis or pancreatitis have also been reported. We present a patient with choledocholithiasis with jaundice who had high serum level of CA 19-9. The rapid decrease and normalization of CA 19-9 after successful biliary drainage was as interesting.

58 –year-old female was admitted to our hospital for epigastric pain, Jaundice, and dark urine of 2 weeks duration. Blood work on admission showed alkaline phosphatase of 1131. AST of 644, ALT of 721. Total bilirubin 25.3, direct bilirubin of 21.4. CT of the abdomen and pelvis showed moderate intra and extra-hepatic duct dilatation. No mass or stone. CA-19-9 level was 2648 IU/ml .ERCP showed distal common bile duct (CBD) stricture with impacted 12 mm stone, with dilated CBD to 15 mm. A Sphincterotomy was performed, the stricture was dilated to 10 mm but the stone could not be extracted. One stent was placed in the common bile duct, with adequate drainage. CA19-9 on Day 28 post ERCP was 7(normal < 35).Patient remained asymptomatic with normal LFT for 18 months of follow up.

The rapid decrease in CA 19-9 and normalization after successful drainage within 30 days is associated with benign disease as in our case. In conclusion elevated CA 19-9 is associated with benign and malignant disease. Therefore, it is important that elevated levels of CA 19-9 are interpreted in the light of the clinical presentation and to be aware of the benign conditions that can be associated with increased levels of this marker.

## **Positron Emission Tomography as a Means for Assessing Atypical Growth in a Case of Ewing's Sarcoma**

Zachary Sanford, Felix Cheung, Stanford Israelsen

Division of Orthopaedic Oncology, Edwards Comprehensive Cancer Center & Department of Orthopaedic Surgery, Joan C Edwards School of Medicine Marshall University

Ewing's sarcoma is a rare primary bone malignancy of small round blue cells. Treatment consists of neoadjuvant chemotherapy, surgical resection, and adjuvant chemotherapy. The disease response to chemotherapy is followed with PET scans, measuring the metabolic activity of the tumor, and MRIs, measuring the size of the tumor. We present a unique case in which the tumor grew in size, but decreased in metabolic activity, making it difficult to judge efficacy of the chemotherapy.

A 35 year old female presented with knee pain and stiffness. Imaging revealed a proximal tibial mass in the right knee measuring 8.2 cm proximal to distal by 9.8 cm AP by 8.9 cm ML. Needle biopsy confirmed the diagnosis of Ewing's Sarcoma. The patient was started on neoadjuvant chemotherapy consisting of Vincristine, Doxorubicin, Cyclophosphamide and Actinomycin D supplemented with Ifosfamide and Etoposide. After three months, the lesion had grown 3.0 cm distally through cortex. In spite of continued growth, metabolic activity decreased from a SUV of 16 to 5. Chemotherapy was continued for an additional two months in the hopes of getting a better size response. Ultimately an above-the-knee amputation was performed due to the size of the tumor. Final tumor size at time of amputation measured 13.0 cm proximal to distal by 8.3 cm AP by 10.0 cm ML; however it consisted primarily of fibrotic scar tissue (90%) and necrotic tissue (5%) but not metabolically active neoplasm.

The unusual response to chemotherapy lends support to the diagnostic value of PET scan in monitoring Ewing's sarcoma and related malignancies. The fibrosis seen in this mass as a result of chemotherapy explains the growth measured during treatment and should be considered as an explanation should similar situations arise in other Ewing's sarcoma patients.

## **Define new aryl hydrocarbon receptor regulatory targets in human breast cancer cells**

Travis Salisbury, Donald Primerano, Goran Boskovic,  
Jun Fan and Jim Denvir

Department of Pharmacology, Physiology and Toxicology, Joan C. Edwards School of Medicine, Huntington, WV. Department of Biochemistry and Microbiology, Joan C. Edwards School of Medicine, Huntington, WV.

Obesity is a risk factor for breast cancer, increases the risk for breast cancer recurrence and breast cancer associated mortality in humans. Adipocytes secrete factors known as adipokines that act on breast cancer cells to stimulate cancer cell growth and thus play a major role in cancer risk and recurrence. We have discovered that pharmacological activation of the aryl hydrocarbon receptor (AHR) in human breast cancer cells inhibits their growth responsiveness to adipokines.

We hypothesized that ligand-activated AHR regulates the expression of genes that are important for breast cancer cell growth and conducted genome wide RNA-seq experiments to identify novel AHR regulatory targets in cancer cells. All genes showing statistically significant changes in expression were loaded into Ingenuity Pathway Analysis and a Core Analysis was performed using default settings.

Of the 634 RNA products uploaded, 496 were mapped to known entities by IPA. The top 15 biological functions by statistical significance were determined and the most statistically significant disease was Cancer (180 associated molecules: p-value  $3.45 \times 10^{-11}$ ) and the most statistically significant molecular/cellular function was Cell Cycle (84 associated molecules: p-value  $2.76 \times 10^{-5}$ ). Genes associated with these functions were extracted to create new IPA pathways, and known experimentally observed connections were added using IPA's "Connect" tool. For each of these pathways, the largest connected component was selected and overlaid with expression fold change from the RNA-seq experiment, which identified potential mechanisms by which knocking down AHR might affect cancer and cell cycle.

The genes in the pathways having altered expression in our experiment, and (essentially through IPA's automated literature search) are involved with cancer/cell cycle and are known to interact with each other and provide the impetus for further study into their functional significance.

## **Pediatric patient compliance in screening tests for anemia**

Alabd Alrazzak B, Katerji B, Lochow A

Department of Pediatrics, Marshall University  
Joan C Edward School of Medicine.

American Academy of Pediatrics has concluded that universal screening for anemia should be performed with determination of Hb concentration at approximately 1 year of age. This screening test could be done either by capillary micro hemoglobin which can be done in the office or by venous blood sample which is usually performed in the lab.

Retrospective chart review for all pediatric patients who were seen in 2010 at Marshall University and had Hb level checked as a screening for anemia. Data about gender, age, and the method in which Hb was checked were collected. The compliance of the patients in following up the lab was also obtained.

Total of 850 charts were reviewed, only 429 met the criteria for the study. Of those Hb was checked in the office by capillary microhemoglobin in 233 patients and 196 patients were given orders to follow up Hb level in the lab which was located in the same building. Of those 196 patients only 139 (72%) followed up with the lab and got the Hb checked and 57 (28%) patients did not follow up and the Hb level was not checked.

The patient's compliance in following up venous Hb concentration as a screening test for anemia is only 72%, this screen could be improved if the screen is performed in the office via capillary hemoglobin.

## **Vitamin D Deficiency Correction: “at risk” populations and potential drug interactions**

Franklin D. Shuler, Dana Lycans, Elias Salloum,  
Matthew Wingate, and Edgar Gonzalez

Department of Orthopaedics, JCESOM and CHH,  
Marshall University

Vitamin D is best known for its skeletal benefits, including minimizing the risk of falls. An epidemic of vitamin D deficiency (<30 ng/ml) is being observed throughout much of the world. Adequate vitamin D levels have been associated with potential extraskeletal benefits, such as decreased risk of cancer, cardiovascular disease, and hypertension, placing increased attention on vitamin D supplementation. Supplementation is typically very safe with no observed toxicity below 30,000 IU vitamin D by mouth daily.

Over-supplementation (25-hydroxyvitamin D3 levels >200 ng/ml) carries the potential for hypercalcemia, leading to neural and organ dysfunction. Caution, therefore, must be taken when prescribing vitamin D to patients predisposed to hypercalcemia. Additionally, vitamin D has many potential drug interactions through the pregnane X receptor, the P450 system, altered gut absorption, and accumulation of toxic substances.

We have reviewed the literature and discuss mechanisms of altered vitamin D metabolism in certain disease states and with certain medication classes.

While vitamin D has potential benefits for diseases such as hypertension, cardiovascular disease, and several types of cancers, diseases that predispose to hypercalcemia may lead to adverse effects if too much vitamin D is present. These include cancers, chronic kidney disease, hyperparathyroidism, sarcoidosis, and other hypercalcemic states. Numerous medications may alter vitamin D levels by several mechanisms. Some classes including antihypertensives, antiepileptics, antibiotics, bile acid sequestrants, and anticoagulants decrease vitamin D. Other medications, such as lithium and antacids containing aluminum or calcium, may cause toxic accumulation of calcium if combined with over-supplementation of vitamin D. Finally, doxorubicin and digoxin are enhanced by higher vitamin D levels which could be beneficial or harmful.

Vitamin D status can be affected by numerous disease states and medication interactions. While achieving an adequate level is important, patient co-morbidities must be considered when prescribing a supplementation regimen.

## **Does Warfarin Treatment Put Patients at Risk for Nutritional Deficiency?**

Devabhaktuni S, Yousef G, Hawthorne T, Tettah S, and Goebel L.

Department of Internal Medicine, Marshall University School of Medicine

Warfarin therapy requires vigilance on the part of the patient to maintain a consistent intake of vitamin K for optimum control of anticoagulation. Some patients may omit foods containing vitamin K completely from their diet in an attempt to be compliant with this diet. We investigated the diets of patients on warfarin treatment and hypothesized that patients on a vitamin K restricted diet may inadvertently restrict their intake of other nutrients.

We collected prospective diet information on 12 patients taking warfarin for a minimum of 9 months and having a target INR (International Normalized Ratio) of 2.0-3.0. Patients were instructed on how to fill out a food diary and completed a diary for three typical days out of the following month. This information was entered into FoodWorks Software, a program designed to translate food input into quantities of nutrients. All patients received feedback on their diet.

We found that all 12 patients had vitamin D deficiency. More than half of the patients were deficient in pantothenic acid (58%) and half were deficient in vitamin A (50%). The next most common deficiencies included dietary fiber (42%), magnesium (42%), manganese (33%), vitamin K (33%), calcium (25%), and vitamin C (25%).

Patients on warfarin treatment were found to have multiple nutrient deficiencies, a finding that has not been previously reported in the literature. This is of concern as many nutrient deficiencies can have adverse effects on the patient's health leading to conditions such as osteomalacia, osteoporosis, night blindness, and scurvy. Warfarin patients may benefit from improved dietary education to prevent these health complications.

## **Unusual presentation of an osteoporotic pelvis fracture mimicking malignancy**

Robert J. Lewis, Jonathon K. Salava, and Felix H. Cheung

Department of Orthopaedic Surgery, Joan C. Edwards School of Medicine, Huntington, WV

Pelvic ring injuries in the elderly population are not uncommon, and they are frequently associated with underlying osteopenia or osteoporosis. In some instances, such fragility fractures can present with abnormal bone healing. If prominent, these abnormal bone breakdown and formation processes can mimic malignancy.

We report the case of an 86 year old female who presented to our institution with severe pelvic pain and the inability to walk. She had presented 10 months earlier to an outside institution with hip pain after falling. Her functional status progressively declined to the point of being unable to ambulate. Imaging revealed what appeared to be a lytic lesion at the pubic symphysis. An extensive work up for an unknown primary malignancy was unremarkable, except for Vitamin D and protein deficiencies. Her metabolic bone disease was addressed medically, and seven months after her presentation to us she was ambulating pain free.

It is important that physicians treating fragility fractures of the pelvis are aware of this entity so that an invasive workup can be avoided as resolution readily occurs with conservative management.



## **Nonoperative Management of Isolated Posterior Wall Fractures with an Initially Unstable Hip**

Stanford T. Israelsen and James B. Day

Department of Orthopedic Surgery, Joan C. Edwards School of Medicine, Huntington WV

Posterior wall fractures are the most common of the elementary acetabular fracture type and are often associated with a dislocated or unstable hip on presentation. The gold standard for evaluation of hip stability is fluoroscopic examination under anesthesia, with instability used the indication for operative intervention. Nonoperative management following a stable exam under anesthesia is a well established treatment yielding good to excellent clinical outcomes. However, timing for a valid exam under anesthesia following injury, and interventions that may acutely affect hip stability are not well established.

Case 1: Posterior hip dislocation with a displaced posterior wall and a transverse acetabular fracture. Reduced in ED and unstable. Returned to OR HD #5 and stable with general anesthesia.

Case 2: Posterior wall acetabular fracture/dislocation and femoral head fracture. Reduced in ED and unstable. Return to OR HD #7 and found to have a stable hip upon general anesthesia evaluation.

Case 3: Posterior wall fracture dislocation with transverse acetabular fracture, and a contralateral pelvic ring/ acetabular fracture with significant displacement. Reduced in ED, patient right side was unstable in OR HD #3. Return to OR HD #8 for right side and found to be stable.

On reexamination using the gold standard assessment for hip stability appeared to qualify for nonoperative management after 5-7 days of skeletal traction, and accordingly surgery was cancelled and conservative management pursued with excellent outcomes to date. However, to the best of our knowledge there are no reported series of the effects of short-term skeletal traction on initially unstable posterior wall fractures, and long-term data regarding the outcome of such management is also lacking. If short-term skeletal traction can be effectively used to convert an initially unstable hip to a stable one that can be managed non-operatively it would prevent a large number of unnecessary surgeries each year.

## **Systemic Sarcoidosis.**

Yousof E Elgaried, Fadi Alkhankan, Rebecca S Wolfer

Internal Medicine, General Surgery.

Sarcoidosis is an uncommon systemic inflammatory disorder characterized by noncaseating granulomatous inflammation that most commonly affects the lungs, intrathoracic lymph nodes, eyes and skin. One-third or more of patients with sarcoidosis have chronic, unremitting inflammation with progressive organ impairment. The defining histopathology, which is not specific for sarcoidosis, is the presence of compact, epithelioid granulomas associated with mononuclear cell infiltration in affected tissues. Clinical manifestations are protean, depending on the location and extent of inflammation, and range from no symptoms to devastating consequences including respiratory insufficiency, blindness, severe neurologic disease and cardiac death

Our patient is 49 yo male who has had some cough for about 2 months. He has recieved augmentin, Levaquin, steroids. He didnt feel well after treatment. He continued to have generalized body aches, fever and vomiting. His cough was getting worse, productive for yellowish sputum.

CXR showed lung nodule. VATs with multiple biopsies shows noncaseating granulomas involving multiple lung specimens and Lymph nodes. Bone marrow biopsy proved involvement too.

Systemic involvement is not uncommon. Full evaluation and proper work up is needed to make definite diagnosis and further help proper treatment.

## **IgA Nephropathy and TTP-HUS in Pregnancy**

Jacquelyn Adams. Joaquin Llado. Ryan Stone.

Obstetrics and Gynecology, Marshall University Joan C. Edwards  
School of Medicine, Huntington, WV

Renal disease in pregnancy must be approached with caution due to the threat to mother and infant. It can lead to preeclampsia, eclampsia, or placental abruption in the mother and decreased birth weight, prematurity, or fetal demise in the fetus. Dialysis decreases fertility and increases the risk of fetal death. Here, we will discuss a case involving two disease states: thrombotic thrombocytopenic purpura-hemolytic uremic syndrome and IgA nephropathy. TTP-HUS is a syndrome characterized by thrombocytopenia, microangiopathic hemolytic anemia, fever, renal failure, and neurologic abnormalities such as cognitive disturbances or stroke. IgA nephropathy is one of the most common etiologies of glomerulonephritis, usually found in older children or young adults. It usually presents as recurrent hematuria following an infection, but may progress to end stage renal disease. It is uncommon to find both of these conditions in the same setting.

This is a 28 year old G4 P2012 patient diagnosed with TTP-HUS and new onset IgA nephropathy. She presented with headache, unexplained hematoma formation on the abdomen and extremities, and later pulmonary edema and fluid retention. She required increasing amounts of dialysis up to 6 days a week. She was followed by obstetrics and gynecology and nephrology from June of 2011 to January of 2012. She delivered a viable male neonate at 31 weeks gestation.

TTP-HUS can be a difficult diagnosis to make in pregnancy because its signs may mimic preeclampsia. It can cause easy bleeding and bruising as well as severe renal failure. IgA Nephropathy can range from a silent disease to worsening renal failure necessitating dialysis. Normal treatment of IgA Nephropathy usually includes immunosuppression with steroids as well as angiotensin converting enzyme inhibitors to minimize proteinuria. This complicates treatment because angiotensin converting enzyme inhibitors and immunosuppressants carry risk in pregnancy.

## **Elevated PTH: True or False Positive?**

Jillian Douglas, Thomas Dougherty, Omolola Olajide

Department of Endocrinology, Marshall University

Intact parathyroid hormone (PTH) assay with Siemens kit on Centaur using EDTA plasma is a “sandwich” technique targeting 2 distant sites on the ligand. A capture antibody and signal antibody target different epitopes. PTH is quantified by measuring the signal antibody generated reaction.

A 55 year old female presented for evaluation of hyperparathyroidism. She had hypercalcemia one year prior. A parathyroid scan showed increased activity at the right lower thyroid pole consistent with adenoma. She subsequently had a parathyroidectomy. A post-operative serum PTH was 20.4 pg/mL and calcium was 9.3 mg/dL. Five months later she had an elevated plasma PTH of 223 pg/mL with a repeat of 553 pg/mL. She remained normocalcemic and asymptomatic. A repeat parathyroid scan did not show a recurrent or residual parathyroid adenoma. We requested patient have a repeat PTH performed at another laboratory. Serum based PTH using Siemens kit on Centaur was 75 pg/mL and repeat was 73 pg/mL. It was concluded that the initial PTH results were falsely positive secondary to assay interference by a patient EDTA-affected antibody.

The possibility of antibody interference should be considered when the test result does not correlate with the clinical picture and negative imaging results. The prevalence of interfering antibodies in blood samples varies among reported studies. The possibility of an anti-animal antibody interference should prompt testing with murine antibody-based sandwich assay, incubation with heterophile antibody blocking tubes, and/or a goat antibody-based PTH testing system.

This case highlights the importance of careful interpretation of laboratory results in conjunction with the clinical picture and using confirmatory testing with discordant results.

## **Hepatitis B immunity and response to booster vaccination in children with inflammatory bowel disease in West Virginia**

Ameen Alshareef, Yoram Elitsur, Maria G. Lopez-Marti.

Dept. of Pediatrics, Joan C. Edwards School of Medicine, Marshall University, Huntington, WV

Even with universal vaccination against hepatitis B virus (HBV), up to 10% of recipients fail to mount an adequate immune response (Cardell K 2008). Immuno-compromised children, such as children with inflammatory bowel disease (IBD) are at risk of HBV reactivation. We are not aware of any data documenting the vaccination rate of HBV in IBD children living in rural communities of WV.

A retrospective chart review of pediatric patients treated for IBD was performed. Hepatitis B surface antigen (HBsAg) and antibody (HBsIg) were checked. Patients found to be non-immune for HBV, received a booster vaccination series and the immune status was rechecked.

Twenty-six patients with IBD were analyzed. The mean age was 13.8 years; 12 (46%) were female. Only one patient was African-American. Twenty patients were diagnosed with Crohn's disease and 6 (23%) had ulcerative colitis. Most of the children were treated with biologics: infliximab (n=12) and adalimumab (n=4). Other immunosuppressive medications used included: mercaptopurine (n= 4), methotrexate (n=4), azathioprine (n=6), and prednisone (n=14). HBV vaccination history was largely unknown (96% had no documented vaccination). No patients had history of active hepatitis B. Chronic HBV carriers were not detected in the 15 patients tested for HBsAg. All 26 patients had baseline testing for HBsIg done: 15/26 (58%) were negative, indicating risk of HBV infection. All 15 children are currently receiving booster vaccination; 8 of 15 (53%) have completed the vaccination series. So far, in 5 patients the post-booster antibody testing showed a positive HBsIg (100% of patients tested)

Over half of our IBD children lack the protective antibodies against HBV and are at risk of HBV infection. Unlike previous data, revaccination with HBV was successful in our IBD patients showing a good antibody response in spite of immunosuppression. Careful assessment of the vaccination and HBV immunity status of children with IBD is recommended.

## **Vitamin D and Pediatric Diseases in WV**

Franklin D. Shuler and David Hourani

Department of Orthopaedic Surgery and JCESOM,  
Marshall University

Vitamin D has well-established roles in calcium and phosphate homeostasis important for bone health. Extra-skeletal effects are also regulated by this secosteroid hormone with emerging research indicating that these effects are concentration dependent. Asthma, obesity, diabetes and metabolic syndrome are diseases that have been associated with vitamin D deficiency. These diseases are very prevalent in West Virginia and have a significant impact on the health of the pediatric population of the state.

### Literature review

- Asthma – 14.7% prevalence in WV children < 18 – vitamin D deficiency associated with asthma exacerbations in RCT
- Diabetes and Metabolic syndrome – 12.4% prevalence (highest in nation) with 32.5% obesity rate (second in nation) – vitamin D deficiency associated with increased risk of these conditions

Evidence supports the role of vitamin D in many physiologic processes. Low serum levels of 25(OH)D have been associated with asthma, diabetes and metabolic syndrome. West Virginia's pediatric population is at a high risk for vitamin D deficiency and the diseases associated with it. Because of this, it is imperative that patients and their families be educated about this modifiable risk factor and the methods available for diagnosing deficiency and appropriate protocols for correcting deficiency.

## Quorum Sensing and Quenching

Franklin D. Shuler, Thomas Emmer and Thomas Schlierf

Department of Orthopaedic Surgery, JCESOM and  
Marshall University

Bacteria have evolved complex methods of chemical communication involving small signaling molecules used to both speak and listen to the individuals within a community. These molecules (autoinducers) are at the heart of many bacterial behaviors including pathogenic mechanisms like antibiotic resistance, biofilm formation and secretion of virulence factors. Quorum sensing (QS) and regulation is essential to bacterial survival but also important to human health. For example, formation of biofilm is a process controlled by QS and occurs in 80% of human bacterial infections. This article introduces the topic and mechanisms of quorum sensing and quorum quenching (QQ).

Literature review was completed analyzing the advances in quorum sensing and quenching and relating that to current orthopaedic research.

Several major types of autoinducers/QS systems have been identified:

- N-acyl-homoserine lactone (AHL) systems and 4-quinolone systems (from Gram negatives),
- AgrD peptide systems (from Gram positives), and
- AI2/LuxS systems (both Gram negatives and Gram positives).

Quorum sensing is best described as a population dependent bacterial cell signaling pathway that has the capability of regulating gene expression. For biofilm formation, the accumulation of signaling molecules is an important switch for increased resistance to antimicrobials and protection against host defenses. Quorum sensing inhibitors (QSI) have been shown to improve antibiotic success rates for medically important biofilm forming bacteria with different QS systems -- *Pseudomonas aeruginosa* (AHL system) and *Staphylococcus aureus* (AgrD peptide-based system). These new strategies of QSI and QQ are being developed to address the emergence of antibiotic resistant bacteria and prevention of human disease including post-operative infections.

## **Isolated “Downhill” Esophageal Varices In SVC Syndrome Caused by Castleman’s Disease**

Neha Goyal, Yaser Rayyan.

Department of Internal medicine, Gastroenterology, Joan C. Edwards  
School of Medicine, Huntington, WV.

‘Downhill’ varices due to Superior Vena Cava (SVC) syndrome are much less common than ‘uphill’ type associated with portal hypertension. In SVC obstruction superior to the azygous vein, venous return from the head and upper extremities is redirected caudally through collaterals into the azygous vein back to the heart. However, this creates back-pressure in the azygous vein. The resulting esophageal varices will be in the upper esophagus. The designation “downhill” refers to the direction of blood flow through the veins. We present a rare case of SVC syndrome and downhill varices due to Castleman’s disease.

A 33-year-old male, who presented with shortness of breath and facial swelling. He had a past history of a mediastinal mass. A previous mediastinoscopic biopsy was benign. A CAT scan was performed, which showed a large anterior mediastinal mass with obstruction of the superior vena cava, compressing the trachea. He also had large bilateral pleural effusion. Preoperative LFT, beta HCG, AFP, and HIV were normal. Physical exam of the scrotum was normal. He underwent resection of a complex mediastinal mass that measured 13x8.5x7 cm, and weighed 350 gms. Pathology revealed the hyaline variety of Castleman’s disease. He was readmitted to the hospital with nausea and vomiting. He underwent an upper endoscopy which revealed grade II proximal esophageal varices without bleeding stigmata. Distal esophagus, stomach and duodenum were normal

This case represents a very rare presentation of unicentric Castleman’s disease with SVC syndrome. Causes of SVC syndrome that have been reported to cause downhill varices include lung & thyroid carcinoma, thymoma, or mediastinal lymphoma, Behcet’s disease and vasculitis. Other causes include goiter, mediastinal fibrosis, and hemodialysis venous access. Bleeding from downhill varices is rare. In case of bleeding, band ligation or angiographic embolization is recommended. In our review of the literature, this case represents the fourth case of Castleman’s with SVC obstruction.



## Primary Tracheal Tumor

Yasser Etman, Nancy Munn

VAMC and School of Medicine, Marshall University, Huntington, WV

Tracheal lesions are not infrequently noted on chest-CT scans but often represent secretions or tumors related to lung or ENT malignancy.

63 yo male presented with 4-week h/o cough, fatigue, DOE and hemoptysis mostly in the morning. He had been treated with several courses of antibiotics for possible bronchitis without significant improvement. There was no report of fever or weight loss. He had a 20-pack-year history of tobacco smoking and had exposure to asbestos for 40 yrs but no reported exposure to TB. His lung exam was unremarkable. Initial CXR showed a posterobasilar infiltrate and mild retrosternal scarring. CT chest showed a lobulated soft tissue density that invaded through the right lateral tracheal wall at the level of thoracic inlet and numerous bilateral cervical LNs, but no hilar or mediastinal lymphadenopathy. Bronchoscopy showed a fungating mass invading the right side of the trachea. Pathology showed squamous cell carcinoma of the trachea. He underwent a tracheal sleeve resection followed by radiotherapy one month later. His final pathology report showed squamous cell carcinoma of the trachea with close radial margin and no tumor seen in the LNs. The tumor was found to be Stage-3 T3N0M0.

Tracheal neoplasms occur infrequently, accounting for less than 1% of all malignancies. Despite their rarity, their usually insidious onset often leads to a delay in diagnosis, making these potentially treatable lesions difficult to treat and often fatal. Squamous cell carcinoma is the most rapid in onset, often leading to hemoptysis or obstructive symptoms as presenting features and is more prone to be exophytic and ulcerative in nature. Practitioners should be aware of this entity so that hemoptysis in patient's without chest-x-ray abnormalities are still promptly addressed.

## **A Case of Ramsay Hunt Syndrome in a 13-year-old Female.**

Rebecca Bell, Joe Evans, April Kilgore

Pediatrics, MUSOM

In this case, we describe a report of a 13-year-old female with culture positive herpes zoster oticus (Ramsay Hunt syndrome) with no history of having varicella but had received 2 doses of the vaccination.

A 13-yr-old female presented to the clinic complaining of left ear pain. She reports a scratch to her ear 10 days prior. Two days ago, her left ear became increasingly swollen and tender. Topical antibiotics were applied with no improvement. On physical exam, her left ear was mildly erythematous with edema of the tragus and pinna. A superficial abrasion was noted inside the left ear, and the remainder of the physical exam was normal. The patient was thought to have cellulitis of the left ear and was prescribed oral antibiotics.

The patient returned to the clinic 2 days with persistent left ear swelling. She now reported excessive tearing of the left eye, concerns that the left side of her face looks “droopy”, and blisters inside her left ear. Patient denies history of chicken pox or herpes simplex I infection and reports having received 2 varicella vaccines. On physical exam, vesicular lesions were visible inside the left ear. An asymmetric smile and difficulty closing the eye, both on the left side, were noted. A viral culture of the vesicular lesions confirmed the diagnosis of Ramsay Hunt Syndrome. She was treated with Prednisone and Valacyclovir.

This case gives an overview of Ramsay Hunt syndrome in children. We discuss the incidence of the disease in children and possible etiologies. Of most importance to our case, we describe breakthrough varicella after vaccination and how the clinical features can be less easily recognized as primary varicella infection. Also, we discovered having varicella before the age of 1 seems to be the most important risk factor for developing RHS in childhood.

## **Paraganglioma a case report of long standing hypertension in a 37 year old female.**

Yanal Masannat, Omolola Olajide

### Endocrinology

Paragangliomas (PGL) are rare tumors with a prevalence of 1/10000 to 1/30000. They can arise from the adrenal medulla, sympathetic or parasympathetic ganglia. Sympathetic associated PGL are usually located in the abdomino-pelvic area and are often functionally active. Functional PGLs are rare causes of secondary hypertension. We report a case of a 37 year old hypertensive female with an incidentally discovered PGL.

A 37 year old female with a long standing history of resistant hypertension was referred for further management. She was on metoprolol, Enalapril and Hydrochlorothiazide/Triamterene for Blood pressure control. An incidental abdominal mass was seen on a CT scan done to evaluate a back lump. This showed a 3.5 cm complex, solid appearing mass located between the left kidney and aorta. A CT guided biopsy done later showed findings compatible with a paraganglioma. She was subsequently seen in our clinic in December 2012.

She reported spells of palpitations, anxiety and sweating triggered by stress for many years. She had episodes of extremely high blood pressure during a nasal septoplasty in 2009 and a hysterectomy in 2012. Her biochemical evaluation showed elevated norepinephrine and normetanephrine levels. She had an I 123 MIBG scan after her evaluation in our clinic which showed radioactive isotope uptake compatible with an extra-adrenal pheochromocytoma located in the left Para-aortic area. She was then started on Doxazosin but Hydrochlorothiazide/Triamterene was stopped. Metoprolol and Enalapril were continued. Surgery is scheduled for January 2013.

Work up for endocrine hypertension should be initiated in young patients with resistant hypertension. Functional PGL are rare and can have detrimental effects if unrecognized. It is a known cause of surgically correctable hypertension. Identifying PGL should prompt screening for this among family members and may warrant genetic testing to prevent harmful effects of an unrecognized, but yet curable cause of hypertension.

## **Bacillus Cereus Bacteremia in 2 month old infant**

Alabd Alrazzak B, Kilgore A, McGuffin A

Department of Pediatrics, Joan C Edward School of Medicine

*Bacillus Cereus* infection is uncommon and usually reported as a contaminant; however systemic infections including bacteremia and meningitis, which are potentially serious, and requiring special and urgent medical attention have been reported. This case presents a 2 month old infant with *B. cereus* bacteremia which was successfully treated with vancomycin.

2 month old male admitted to pediatric floor for 2 weeks of projectile vomiting which was accompanied with a fever for the last 3 days, he has a history of esophageal reflux and is on OTC rice cereal thickened formula, no history of recent IV catheter use prematurity or NICU admission; no sick contact at home; on physical exam the patient was febrile and has 2/6 systolic ejection murmur and otherwise exam was normal. The Patient underwent a full septic workup which revealed a positive blood culture for *B. Cereus* after 17 hour of incubation; CSF and urine cultures were negative, other labs showed leukocytosis with left shift and mild transaminitis. Head CT scan, abdominal ultrasound and echocardiogram were obtained and ruled out disseminated disease. The patient was treated with vancomycin and showed dramatic improvement; the fever resolved within the following 24 hours, WBC was normal within the following 3 days and ASL, ALT showed steady improvement until discharge. Public health was contacted regarding possible testing of the rice cereal and declined further testing as there was no identified outbreak.

Even though *B. Cereus* is an uncommon cause of bacteremia in otherwise healthy infant, physicians should have a high index of suspicion for this pathogen and be aware of the transmission, diagnostic process and the appropriate antimicrobial treatment.

## **Recognizing Post-Streptococcal Guttate Psoriasis**

Lacey Vence

Internal Medicine

Guttate psoriasis is a less common form of psoriasis. It manifests with numerous small, teardrop shaped plaques on the trunk and extremities. It commonly arises 3-4 weeks following a beta hemolytic streptococcal infection. In some cases, it may be misdiagnosed as an allergy to the antibiotics being used to treat the infection. This case report stresses the importance of differentiating guttate psoriasis from an antibiotic allergy.

A 53-year-old Caucasian female with no history of psoriasis presented with sudden onset of sore throat. A rapid strep test was performed and was positive for beta hemolytic streptococcus and she was started on Amoxicillin. Five days after finishing the antibiotics, she developed a rash on her legs that spread to her torso within one day. On physical exam, she had multiple papulosquamous lesions over the torso and proximal extremities, sparing the hands and feet. At this time she was diagnosed with an allergy to Amoxicillin. Multiple office visits later she was given the diagnosis of Guttate Psoriasis. She was treated with Triamcinolone Acetonide Cream 0.1% and was instructed to avoid oral steroids.

Guttate psoriasis has a prevalence of less than 30 percent of patients with psoriasis. Etiology includes both environmental and genetic components. Due to its common presentation after a streptococcal infection and probable completion of antibiotic therapy, it is important not to confuse guttate psoriasis with an antibiotic allergy. The time period and the classic teardrop appearance of the rash are characteristics that will help differentiate between an allergy and guttate psoriasis. First line therapy includes ultraviolet phototherapy. Topical corticosteroids and vitamin D analogues can also be used. It is important not to treat guttate psoriasis with systemic corticosteroids due to the rebound flare phenomenon.

## **Extraskelatal myxoid chondrosarcoma: case report and literature review**

David Feigal, Aneel Chowdhary

Marshall University - Joan C. Edwards School of Medicine

Extraskelatal myxoid chondrosarcoma (EMC) is a rare malignant soft-tissue sarcoma with a median onset age of 49.5 and slight male predominance of 2:1. We present a case report of a 53-year-old caucasian male admitted for pain and weakness in the right lower limb in 2009. Magnetic resonance imaging (MRI) at that time revealed a complex soft tissue mass in the lateral right thigh involving the muscles of the lateral thigh as well as gluteus musculature, measuring 11x21 cm in dimension. Post contrast imaging demonstrated intense though heterogeneous enhancement consistent with a sarcoma. Biopsy showed no areas of increased cellularity or rhabdoid changes, but rather features consisting of a cord and chain-like proliferation of bland small cells with eosinophilic cytoplasm embedded in a basophilic myxoid background. These histologic findings are normally consistent with a low-grade neoplasm, however, the histologic features are not especially successful in predicting the behavior of these tumors. In general, EMC neoplasms behave as low-grade sarcomas with considerable potential for late recurrence and metastasis. Excision of the mass was performed at this time with preservation of the bony structures. The patient was later admitted in 2011 for a pathologic fracture of the right mid-femur, with suspected secondary malignant neoplasm, bone, and bone marrow metastatic spread of recurrence. MRI demonstrated a 7mm transverse fracture with surrounding edema, but no definitive mass. Prominent lymph nodes up to 1.4 cm were also appreciated in the right groin. Patient underwent fixation of the fracture with rod placement. In 2012, an 8 mm left-lower nodule was discovered on routine follow-up screening computed tomography scan. The lung nodule was suspicious for recurrence of the sarcoma and left-lower-lobectomy with level 7 lymph node excision was performed. Histology showed small foci of metastatic extraskelatal myxoid chondrosarcoma, with rare scattered poorly formed non-necrotizing granulomas.

## **Cefaroline Use In Immunocompromised Pediatric Patient with MRSA Pneumonia**

Baraa Alabd ALrazzak, April Kilgore

### Pediatrics

Ceftaroline is a  $\beta$ -lactam of the cephalosporin class of antimicrobials. It has antibacterial activity against aerobic gram positive cocci including MRSA Streptococcus pneumonia. FDA has granted approval for ceftaroline in October 2010, to treat adults with community acquired bacterial pneumonia and acute bacterial skin and skin structure infections. Data about its use in pediatric population is still limited; this case presents our experience with ceftaroline in treating MRSA pneumonia in 3 year old immunocompromised patient.

A 3-year-old Caucasian male with PMH of Kaposi form lymphangiomatosis with a consumptive coagulopathy, and immunosuppression secondary to chemotherapy was admitted to the PICU for an epidural hematoma and underwent emergency craniotomy. On hospital day 4 he was intubated secondary to acute lung injury. He was febrile, CXR showed bilateral infiltrate compatible with PNA, and sputum culture grew MRSA. He was started on vancomycin and ceftriaxone but continued to be febrile and had worsening infiltrates. In addition, cultures showed a vancomycin MIC of 2 and as a result he was changed to levofloxacin and Gentamicin with no improvement. ID was consulted and ceftaroline was added to maximize MRSA coverage. He improved within 48 hours of starting ceftaroline, and continued to clinically improve and was extubated, and CBC and CRP both improved and were normal a week later.

In adult studies, ceftaroline is active against MRSA pneumonia; however there is no data on its use in children. This case illustrates the successful use of ceftaroline in a complicated pediatric patient in which susceptibility data and agent side effects precluded the use of other traditionally used agents. Additionally, this patient had no reported side effects from therapy. Until further data is available we recommend use only in patients for whom no other options exist and in consultation with a pediatric ID specialist.

## **Resveratrol Protects Renal Tissue from Reactive Oxygen Species (ROS) Cytotoxicity**

Stephanie Van Meter, John G. Ball, Rikki Miller, Bekkah Brown,  
Jacob Wolfe and Monica Valentovic

Department of Pharmacology, Physiology and Toxicology,  
Joan C. Edwards School of Medicine, Huntington, WV

Cisplatin is a cancer chemotherapeutic agent used for treatment of cervical, ovarian and non-small cell lung cancer. Nephrotoxicity is a serious adverse effect associated with cisplatin. The mechanism for cisplatin nephrotoxicity is not known but includes oxidative stress and generation of Reactive Oxygen Species (ROS). Previous work in our laboratory has shown that Resveratrol (RES) reduced cisplatin nephrotoxicity in a rodent model. The purpose of this study was to evaluate whether RES could reduce renal toxicity induced by the ROS species, hydrogen peroxide (H<sub>2</sub>O<sub>2</sub>) and furthermore, did RES protect oxidative stress enzyme activity from H<sub>2</sub>O<sub>2</sub>.

Renal cortical slices were prepared from male Fischer 344 rat kidneys (n=4/group). Renal slices were equilibrated in oxygenated Krebs buffer and incubated for 30 min at 37°C with 0, 50 or 150 μM RES. Renal slices were then incubated for 30-120 min with 0, 10 or 20 mM H<sub>2</sub>O<sub>2</sub>. In some experiments, RES was rinsed from the tissue to test the hypothesis that RES protection was not mediated by an extracellular reaction with H<sub>2</sub>O<sub>2</sub>. Loss of membrane integrity was assessed by lactate dehydrogenase (LDH) leakage. Oxidative stress enzyme activity was assessed on renal tissue.

H<sub>2</sub>O<sub>2</sub> induced a concentration dependent increase in LDH leakage within 30 min in the absence of RES (p<0.05). A final concentration of 50 or 150 μM RES prevented LDH leakage by 10 and 20 mM H<sub>2</sub>O<sub>2</sub>. A 30 min incubation with RES (50 μM) followed by further incubation with H<sub>2</sub>O<sub>2</sub> in the absence of RES also prevented a rise in LDH by H<sub>2</sub>O<sub>2</sub>. Catalase enzyme activity was not depressed by H<sub>2</sub>O<sub>2</sub> or RES during the exposure period.

In conclusion, RES can protect renal cortical tissue from ROS cellular toxicity. Further studies need to evaluate the mechanism for protection.



## **Stage IV melanoma with unknown primary with small bowel and lung involvement discovered through capsule enteroscopy**

Majd Kanbour and Waseem Shora

Department of Medicine, Gastroenterology

Malignant melanoma is known by its unpredictability to metastasize to practically any organ. Among gastrointestinal involvement, the small bowel is affected in 30 - 75 % of cases. Primary malignancies of the small intestine in general are unusual, thus malignant melanoma alone represents a significant proportion of all neoplasms in the small bowel. Primary malignant melanoma of the small intestine was described only in few case reports. We describe a case of small bowel involvement by malignant melanoma and

66-year-old Caucasian male who has been sent to us for further evaluation for anemia. The patient's history dates back to November 2009 when he presented with a hemoglobin of 7.7, fatigue, and tiredness. His white blood count was 6.9 and platelet count was 241. His MCV was 68. He had a colonoscopy and EGD in November 2009 which was normal.

Barium study of the small bowel on 07/08/2010-WNL.

Further evaluation by capsule enteroscopy showed a lesion in the small bowel which on resection proved to be melanoma of the small bowel.

PET-CT and MRI brain showing No Mets .

CT chest showed 12 mm lung lesion. Bx on 10/7/2010 showed melanoma. Had LLL wedge resection 10/22/10 and pathology report consistent with melanoma. PET-CT 11/24/10 showed no evidence of disease. Patient completed 12 months of INF treatment 1/2012.

The small intestine is the most common location of gastrointestinal metastasis from cutaneous malignant melanoma. On the other hand, primary melanoma originating in the small intestine is extremely rare .An exceptional case of melanoma in Meckel's diverticulum has also been published .we assume that this case is primary small bowel melanoma. A Curative resection of the tumor remains the treatment of choice. Adjuvant therapy comprises interferon alfa, interleukin-2, vaccination with modified melanoma cells and high-dose chemotherapy with autologous bone marrow transplants .

## **Giant Cell Foreign Body Injection Site Reaction to Interferon Beta-1b**

Susan Touma, Rodney Kovach, Lacey Vence, Audrey Dean

Huntington Dermatology

Interferon beta-1b (Betaseron) was approved by the FDA in 1993 for the disease modifying therapy of relapsing multiple sclerosis. Its mechanism of action in patients with multiple sclerosis is unknown. The most common adverse reaction is injection site reactions (78%) including: hypersensitivity (4%), inflammation (42%), mass (2%), pain (16%), edema (2%), atrophy, hemorrhage, and nonspecific reactions. Injection site necrosis is seen in 4% of patients. Panniculitis and lipoatrophy can also be an adverse reaction seen in patients taking Interferon beta-1b. We present a case of a skin reaction following 12 years of Interferon beta-1b with accompany pathology reports of foreign body giant cell reaction.

A 58-year-old woman presented to a dermatologist for evaluation of "scar tissue" and painful skin lesions that had formed in the location of her Interferon beta-1b injection sites. She has been using Interferon beta-1b for multiple sclerosis for the past 12 years. On physical exam, subcutaneous indurated plaques with overlying erythema were visible over the lower abdomen and right anterior thigh. The dermatopathology report showed mild fibrosis and focal foreign body type giant cells in the deep dermis possibly related to the patient's medication injections. Multiple deeper cuts did not reveal changes of panniculitis or fat necrosis.

Based upon our literature research, foreign body giant cells have never been described with Interferon beta or confirmed by histology with any interferon. Further investigation is necessary to determine the clinical significance and the possible mechanism. It is plausible that miniscule foreign bodies could have been introduced with the injections. Our patient was also instructed to ice the sites prior to treatment, which is not a recommended instruction in administering the drug according to the package insert and may have contributed to her pathology.

## **Hypoglycemia in the Diabetes Control and Complication Trial (DCCT) and the Epidemiology of Diabetes Interventions and Complications (EDIC) Trial: What is the story with vascular disease?**

Elke Fährmann \*, Laura Adkins \*\*, Jim Denvir \*\*\*, Henry Driscoll \*

\* Joan C. Edwards School of Medicine, Huntington, WV; \*\* Marshall University, Department of Mathematics, Huntington, WV; \*\*\* Marshall University, Department of Biochemistry and Microbiology, Joan C. Edwards School of Medicine, Huntington, WV: Acknowledgment:

The Diabetes Control and Complications Trial (DCCT) and its follow-up the Epidemiology of Diabetes Interventions and Complications (EDIC) study were conducted by the DCCT/EDIC Research Group and supported by National Institute of Health grants and contracts and by the General Clinical Research Center Program, NCRR. The data from the DCCT/EDIC study were supplied by the NIDDK Central Repositories. This manuscript was not prepared under the auspices of the DCCT/EDIC study and does not represent analyses or conclusions of the DCCT/EDIC study group, the NIDDK Central Repositories, or the NIH.

Recently, major attention has been paid to the role of hypoglycemia as a risk factor in cardio-vascular disease (CVD). While EURODIAB-investigators concluded that severe hypoglycemia is not a risk factor in T1DM, other investigators found the opposite to be true. The role of mild hypoglycemia as a CV-risk factor was not investigated. Our aim is to shed light onto these contradictory results and additionally assess the role of mild hypoglycemia.

We analyzed the effect of self-reported hypoglycemic events of 1206 patients during the DCCT/EDIC-study on Calcification score (CAC), measured during the EDIC-study. Severe hypoglycemia was defined as hypoglycemic events requiring assistance, a blood glucose level below 50mg/dl and/or clinical manifestations reversed by treatment. In case of mild hypoglycemia, patients were able to treat themselves. Robust statistical tests for hypoglycemia and A1C-levels (good, <7.5%; fair, 7.5%-<8.5%; poor, 8.5%-<9.5%; very poor, >=9.5%) were employed. To analyze the association between CAC and hypoglycemia, several statistical models were applied.

Hypoglycemia (severe, mild) during the DCCT, EDIC and total follow-up was significantly different for above A1C-ranges. Consequently, stratification was applied. Additionally, mild hypoglycemia was stratified by the existence of severe

hypoglycemia. Stratified Tobit-model analyses showed significant positive associations between severe hypoglycemia and CAC during the EDIC-study and total follow-up time for patients with good-to-excellent glucose-control ( $p < 0.02$  and  $p < 0.02$ , respectively). Furthermore, mild hypoglycemia during the EDIC study and total follow-up was associated with increased calcification score ( $p < 0.04$  and  $p < 0.05$ , respectively) for patients with a fair glucose-control and no severe hypoglycemia. For patients with severe hypoglycemia the association became almost significant in the poor glucose-control range during the total follow-up ( $p < 0.06$ ). Additional models showed similar results.

Our analysis seems to link the results of the contradictory reports. We found that hypoglycemia is a risk factor for preclinical arteriosclerosis. However, the role of hypoglycemia is not straightforward. One size doesn't fit all.

## **Retrospective analysis of Hepatitis C transmission rates between vaginal and cesarean deliveries**

Ryan Stone and Elizabeth Brown

Marshall University Obstetrics and Gynecology

Hepatitis C virus vertical transmission rates to a fetus during pregnancy has been reported as 5-6% with no difference in infection rates between infants delivered vaginally compared with infants delivered with cesarean section. This is reflected in the recommendations for delivery by the CDC to preserve cesarean section for obstetrical indication and not for the prevention of vertical transmission. Our current practice, however, is to offer elective cesarean section for viral load greater than 1 million per milliliter at time of delivery based on small studies which show a decreased rate of transmission with high viral load.

This study is a retrospective review of women delivering at Cabell Huntington Hospital who had hepatitis C at time of delivery and reviewing the infant transmission rates based on mode of delivery and hepatitis C viral load at time of delivery in the last 10 yrs. The study will compare transmission rates between vaginal, operative vaginal and cesarean deliveries. Positive perinatal HCV infection will be determined by a positive HCV RNA greater than 12 months from delivery.

Medical records for women with hepatitis C who delivered between November 2002 to November 2012, 221 deliveries were available for review. Of the 221 deliveries, only 27 infants were tested after delivery. Of the 27 infants tested, only 10 were tested after at least 1 yr following delivery. All of the infants tested were hepatitis C negative.

Insufficient data were available to make any determinations of whether elective cesarean sections decreased hepatitis C transmission rates to infants at time of delivery. Infants were not tested after delivery. A prospective study should be conducted to more accurately determine whether elective cesarean delivery reduces transmission rates. This study would be designed to provide follow-up testing for infants in order to collect the necessary data for transmission rates.

## **Liver Abscesses caused by Streptococcus Constellatus**

Mohammed AL-Ourani, Nancy Munn, Fuad Zeid

Internal Medicine/Pulmonary Medicine, Joan C. Edwards School of Medicine. Huntington, WV, VAMC. Huntington, WV

*Streptococcus Constellatus* is an anaerobic germ that colonizes the mouth, superior airways, the intestinal and urogenital tracts and are considered to be commensal rather than pathogenic. These group of microorganisms is characterized by the tendency to form abscesses in different organs .

A 67-year-old white man with Hemorrhoids and diverticulosis .He presented with abdominal pain in the right upper quadrant, gradual onset , dull aching in nature, became tolerable over the last 3 days prior to admission. Had history of Colonoscopy 2 weeks before this pain started. Physical examination revealed that the liver was palpable 6 cm below the costal margin in the right mid-clavicular line. Abdominal Computerized Tomography showed large intrahepatic abscess and moderate right pleural effusion. Drainage of the abscess that was done the next day by Interventional radiology with pigtail catheter, 850 cc out from the abscess was drained, Culture of the purulent material obtained yielded *Streptococcus constellatus* as the causative agent. Patient was put on Unasyn, he required vasopressors for few days during his stay in the ICU due to septic shock. He also required hemodialysis due to the deterioration of his kidney function secondary to sepsis .Patient continued to complain of abdominal pain mainly Right and left upper quadrants, and leukocytosis, abdominal ultrasound was done and revealed another 2 abscesses in the right and left lobe of the liver that was not well seen in the CT scan before due to the large abscess, another drain was put in.

Liver abscess is a potential life-threatening disease that must be treated as soon as possible with invasive approaches. *Streptococcus Constellatus* in the normal conditions are not associated with pathologic events in humans except when any invasive manipulation is performed such as dental procedures , Endoscopy or other surgical procedures .Our patient had Colonoscopy 2-3 weeks before his presentation.

## **A Case of Epidural Hematoma and Kaposiform Lymphangiomas**

Bi Mo, Tarek Hussein, Anthony Alberico, Paul Ferguson,  
Richard Coulon

Department of Neuroscience, Joan C. Edwards School of Medicine, Huntington, WV., Department of Pediatrics, Joan C. Edwards School of Medicine, Huntington, WV.

Generalized Lymphangiomas (GLA) is a rare benign condition. Kaposiform Lymphangiomas (KLA) is a newly identified variant of even lower incidence. This aggressive version of lymphatic malformation commonly presents with coagulopathy (thrombocytopenia), friable vessels, hemorrhagic effusion, and a spindle cell component histologically. Currently, there is limited literature on this entity and it remains poorly characterized. The clinical course of lymphangiomas is protracted and the symptoms are vague. All parts of the body can be affected, except Central Nervous System (CNS) where lymphatic system does not reach. Diffuse involvement of soft tissues, internal organs, and bones can result in significant morbidity and mortality. There is presently no literature documenting the management of acute neurological operative condition in patient with Kaposiform Lymphangiomas and the challenges encountered in subsequent intensive care setting.

We hereby present a case of emergent evacuation of epidural hematoma in a 3 year-old Caucasian male diagnosed with Kaposiform Lymphangiomas and associated consumptive coagulopathy. Patient presented to the Emergency Department in altered mental state. CT imaging results indicated an epidural hematoma localized to the right posterior cranial fossa. No evidence of abuse or history of recent trauma was identified. Patient was managed operatively in spite of suboptimal hemodynamic conditions due to rapidly deteriorating neurological conditions. Patient was subsequently managed in the Pediatric Intensive Care Unit with a multitude of challenges surfacing throughout the clinical course of his hospital days.

Kaposiform Lymphangiomas is an extremely rare entity and its clinical manifestation varies by location. The condition is complex and its involvement is broad. From a neurosurgical standpoint, the need to familiarize with lymphangiomas cannot be overlooked for several important clinical reasons especially when multifocal lytic bony lesions are present. A multidisciplinary approach is prudent in order to maximize recovery and reduce the burden of comorbidities.

## **Assessment of Nurse Satisfaction with Bedside Nurse Presence at Family Centered Rounds**

Audra Pritt and Jennifer Gerlach

Pediatrics, Marshall University

The study assessed whether inclusion of a patient's nurse during family centered rounds (FCR) affected nurse satisfaction. Many studies have been performed to assess patient and physician satisfaction with FCR, but few have addressed nursing satisfaction.

The nursing staff at Cabell Huntington Hospital was surveyed before inclusion of nurses in FCR using a validated survey. Each nurse present for rounds was surveyed daily for one week, resulting in 18 total surveys. On 10/1/2012 nurses began to be included in FCR. A month later, the nursing staff was surveyed again using the same survey tool. A focus group of three nurses provided input.

18 surveys were collected before changes were made to FCR, and 15 surveys were collected after changes were made to FCR. The pre-changes surveys were not statistically significant because of too many uninterpretable responses. The surveys conducted after changes to FCR were analyzed. 80% of nurses surveyed agreed that new FCR gave them an improved idea of the patient's care plan. 84.5% agreed that patient and family contributions during rounds were useful. 64.3% agreed that patients and families participated in decisions during FCR. 61.5% disagreed that patient and family concerns and questions took up too much time. 66.7% agreed that they were informed when rounds began. 71% agreed that they were present for the entire duration of their patient's presentation. 73% agreed that they had the opportunity to raise concerns. A focus group of 3 nurses provided additional insight into nurse satisfaction with changes to FCR. The nurses felt they had a better understanding of the patient's care plan for the day, but that it is difficult to for them commit to the entire patient presentation given conflicting patient care duties.

Inclusion of a patient's bedside nurse in FCR was associated with satisfaction from the nursing staff.







# Hematology/Oncology Update

## for the Primary Care Physician



## Friday, April 26, 2013

in the Harless Auditorium on the campus of  
the Edwards Comprehensive Cancer Center

[www.edwardsccc.org](http://www.edwardsccc.org)  
[www.cabellhuntington.org](http://www.cabellhuntington.org)

### Planning Committee

The planning committee for the 2013 Hematology/Oncology Update for Primary Care Physicians includes:

- Maria Tria Tirona, MD, FACP (chair)
- Rajesh Sehgal, MD
- Lynne Goebel, MD, FACP
- Linda Savory, MD
- Charles McCormick, MD
- David Bailey, MBA
- Angie Hayes, MA, RT(R), (T), CMD
- Deanna LaFon
- Lisa Muto, DNP WHNP-BC, APNG, OCN®
- Margaret Wagnerowski, MSN, RN, CNS-BC, AOCN® , AOCNS®
- Sheila Stephens, DNP RN, MBA, AOCN®
- Jennifer Murray, MSN, RN

No disclosures or conflicts of interest are indicated.

Course objectives will be available online for download at [http://mission.manual.edu/ce/ce\\_directory.asp](http://mission.manual.edu/ce/ce_directory.asp). Print weeks prior to conference.

## 4th Annual Hematology/Oncology Update for the Primary Care Physician

Friday, April 26, 2013

7 a.m.	Registration/Continental Breakfast/Vendors
7:30 a.m.	<b>Welcome &amp; Introduction</b> Mario Tiro, MD, FACP Marshall University JCESOM Edwards Comprehensive Cancer Center
7:45 a.m.	Larry Dost, MD Marshall University JCESOM
	Moderator: Rajesh Srigal, MD Marshall University JCESOM Edwards Comprehensive Cancer Center
	<b>Common Hematological Issues in the Primary Care Setting</b> Mohamed Maswada, MD Marshall University JCESOM Edwards Comprehensive Cancer Center
8:45 a.m.	<b>Hereditary Breast Cancer:</b> Do You Know It When You See It? Larry Geier, MD, Medical Oncologist Director, Genetic Risk Evaluation and Testing Kansas City Cancer Center—South
	Break with exhibitors
9:45 – 10 a.m.	
10 a.m.	Moderator: Lynne Goates, MD, FACP Marshall University JCESOM
	<b>Modalities for breast cancer screening – when to use MRI and 3D mammograms</b> Reidar Blake, MD Radiology, Inc.
10:30 a.m.	<b>Palliative Care in Primary Care</b> Charles McCormick, MD Marshall University JCESOM

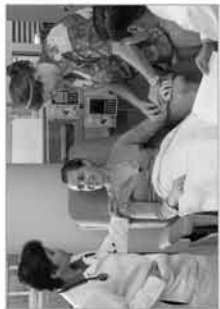### Survival Issues Pertinent to Primary Care Providers

Mario Tiro, MD, FACP  
Marshall University JCESOM  
Edwards Comprehensive Cancer Center

Break with vendors

### Lunch & Learn: Case Studies

All speakers  
Ariwe Chonohary, MD  
Marshall University JCESOM  
Edwards Comprehensive Cancer Center



## 4th Annual Hematology/Oncology Update for the Primary Care Physician – April 26, 2013

### Course Objectives

- Apply knowledge of the work-up of a patient with mild pancytopenia or thrombocytopenia before referral to a specialist.
- Compare and contrast the use of blood products, including single donor and multiple donor platelets, and the use of platelet transfusion in the setting of thrombocytopenia.
- Describe the work-up and plan of care for patients with hematologic diseases such as CLL or monoclonal gammopathy.
- Identify patients to be referred for genetic counseling and genetic testing.
- Describe cancer risk reduction strategies related to a genetic mutation.
- Compare and contrast the indications for mammography, 3D mammography, ultra sound and MRI in the diagnosis of breast cancer in asymptomatic patients.
- Discuss the use of tamoxifen in the management of breast cancer.
- List one resource to assist in equal analytic conversation.
- Apply the knowledge of the risks and benefits of tube feedings for patients at the end of life.
- List 6 of the top 10 sources of distress reported by EOC cancer survivors.
- Describe the role of primary care providers in reducing fear of recurrence for cancer survivors.
- Discuss one late side effect of radiation therapy seen in breast cancer patients.
- Formulate a plan of preventive care for the cancer survivor.
- Formulate a plan of care for the patient with a hematologic cancer; post treatment.
- Formulate a plan of care for the patient who requires palliation of symptoms.

### Purpose of Conference

To educate healthcare providers regarding the diagnosis, treatment and management of hematology/oncology conditions. The conference is designed to provide continuing education for individuals who are challenged by hematology/oncology issues to include current research, best practice and clinical practice guidelines.

### Target Audience

Primary care physicians, physician assistants, residents, medical students, nurses, pharmacists and other healthcare providers interested in cancer patient management.

### Physician Continuing Education Credit

Marshall University, Joan C. Edwards School of Medicine designates this educational activity for a maximum of 4.5 AMA PRA Category 1 Credits™. Physicians should only claim credit commensurate with the extent of their participation in the activity. (Session registration and evaluation are required.)

### Nursing Continuing Education Credit

Continuing Education credit will be provided for nurses who complete the course. The American Nurses Association, an accredited sponsor by the American Nurses Credentialing Center's Commission on Accreditation, 4.5 contact hours will be provided.



This activity has been planned and implemented in accordance with the Essentials and Standards of the American Nurses Credentialing Center for continuing education through the American Nurses Credentialing Center's Commission on Accreditation. CME is provided by Marshall University, Joan C. Edwards School of Medicine. Manual University, Joan C. Edwards School of Medicine is accredited by the Accreditation Council for Continuing Medical Education (ACCME) to provide continuing medical education for physicians.

# FACULTY



**Rodger Blake, MD**  
Associate Clinical Professor  
Department of Diagnostic Radiology  
Director of MRI Services



**Aneel Chowdhury, MD**  
Assistant Professor, Section  
of Hematology/Oncology  
Marshall University JCESOM  
Edwards Comprehensive Cancer Center



**Larry Geier, MD**  
Medical Oncologist and Director,  
Genetic Risk Evaluation and Testing Program  
Kansas City Cancer Center  
Assistant Professor of Medicine,  
Division of Oncology  
University of Kansas Cancer Center



**Lynne Goebel, MD, FACP**  
Professor, Department of  
Internal Medicine & Geriatrics  
Marshall University JCESOM



**Aamir Hussain, MD**  
Assistant Professor, Department  
of Radiation Oncology  
Marshall University JCESOM  
Edwards Comprehensive Cancer Center  
Director of Stereotactic Radiosurgery  
and Stereotactic Body Radiotherapy



**Mohamed Khasawneh, MD**  
Assistant Professor, Section  
of Hematology/Oncology  
Marshall University JCESOM  
Edwards Comprehensive Cancer Center




**Charles McCormick, MD**  
Associate Professor, Section  
of Family and Community Health  
Marshall University JCESOM  
Medical Director, Hospice of Huntington



**Rajesh Sehgal, MD**  
Assistant Professor, Section  
of Hematology/Oncology  
Marshall University JCESOM  
Edwards Comprehensive Cancer Center



**Maria Tria Tirone, MD, FACP**  
Director of Medical Oncology,  
Edwards Comprehensive Cancer Center  
Professor of Medicine and Chief,  
Section of Hematology/Oncology  
Marshall University JCESOM  
Edwards Comprehensive Cancer Center



**Disclosure Summary**  
Dr. Geier has disclosed an affiliation with Myriad Genetics' Speakers Bureau.

*At present, no other disclosures or conflicts of interest are indicated. Faculty will disclose any additional conflict of interest at the time of the presentation.*



**Edwards Comprehensive Cancer Center**

# REGISTRATION

## HEMATOLOGY/ONCOLOGY UPDATE for the Primary Care Physician Friday, April 26, 2013

Name \_\_\_\_\_  
Address \_\_\_\_\_

Phone \_\_\_\_\_ Email \_\_\_\_\_

Employing Agency \_\_\_\_\_

Position/Title \_\_\_\_\_

**Fee enclosed:**

**No cost for students and faculty, but registration is required to guarantee availability of course materials and lunch.**

No Charge \_\_\_\_\_ MU faculty physicians, medical students, residents or fellows

No Charge \_\_\_\_\_ CHH employees

\$25 \_\_\_\_\_ All others (lunch included)

**Make checks payable to Edwards Comprehensive Cancer Center.**

**For credit or debit cards, please include:**

Name on card \_\_\_\_\_

Account # \_\_\_\_\_

Expiration date \_\_\_\_\_ CV# code on back \_\_\_\_\_

**Return this form with remittance to:**

Edwards Comprehensive Cancer Center  
ATTN: Angie Hayes, Radiation Oncology  
1400 Hall Green Boulevard  
Huntington, WV 25701

**Email to:** cancerconferences@chh.org **Fax to:** 304-399-6528

**The deadline for registration is April 15, 2013.** For more information, call 304-399-6518. This form may be photocopied.

**Assisted Services:** Do you require special arrangements to participate in this conference?

Comment \_\_\_\_\_

Do you request a vegetarian meal?  Yes  No

Please submit a question for the lunch discussion, or fax to 304-399-6528.

